

ILLUSTRATED GUIDE TO COLLAGEN INDUCTION **WITH PLATELET-RICH PLASMA (PRP)**

Rejuvenation

Face

Neck

Décolleté

Hands

Bernard C. Kolster

Uwe Paasch

With the collaboration of Hanno Pototschnig

 **QUINTESSENCE PUBLISHING**

London, Berlin, Chicago, Tokyo, Barcelona, Beijing, Istanbul, Milan, Moscow,
New Delhi, Paris, Prague, São Paulo, Seoul, Singapore and Warsaw

Table of contents

1	Skin repair and skin regeneration as a therapeutic principle 2		
1.1	Wound healing and cicatrization 3		
1.1.1	Physiology of wound healing 3		
1.1.2	Pathophysiology of wound healing 4		
1.2	Fractional microtraumatization – the scarless gateway to the skin 9		
1.2.1	Drug delivery via fractional microtraumatization 11		
1.2.2	Laser- and microplasma-assisted PRP therapy 14		
1.2.3	Needling-assisted drug delivery 14		
2	PRP in aesthetic medicine 18		
2.1	Introduction 18		
2.2	Mechanism of action 18		
2.3	Clinical effect 19		
2.4	Contraindications 19		
2.5	Side effects 19		
2.6	Treatment failures 19		
2.7	The use of PRP in hair loss 20		
3	PRP preparation systems 22		
3.1	Requirements for an ideal system 22		
3.2	Comparison of the various systems 22		
3.3	Conclusions 26		
3.3.1	Platelet concentration 26		
3.3.2	Separating off leukocytes and erythrocytes 26		
3.3.3	PRP yield 26		
3.3.4	Preparation time 26		
3.3.5	Closed versus open systems 26		
3.3.6	With/without separation gel 27		
3.3.7	User-friendliness/overall procedure time 27		
4	Application methods 30		
4.1	Microneedling 30		
4.2	Devices 31		
4.2.1	Rolling 31		
4.2.2	Pens 31		
4.2.3	Injector 32		
4.3	Puncture depth 32		
4.4	Combined treatment options 35		
4.4.1	Combination of PRP with hyaluronic acid 35		
4.4.2	PRP and lipofilling 35		
5	Patient management 38		
5.1	Consultation 38		
5.2	Examination 38		
5.2.1	Medical history 38		
5.2.2	General dermatological examination 39		
5.3	Objective evaluation 46		
6	Documentation and organization 48		
6.1	Photo documentation 48		
6.1.1	Background 49		
6.1.2	Lighting 49		
6.1.3	Camera 50		
6.1.4	Taking photographs 51		
6.1.5	Photo documentation checklists 55		
6.2	Archiving 56		
6.2.1	Record sorting 56		
6.2.2	Archiving using practice software 56		
6.3	Practice organization 56		
6.3.1	Appointment planning and information material 56		
6.3.2	Information events 56		
6.3.3	Waiting room TV 56		
6.4	The information session and informed consent 56		
7	Treatment 60		
7.1	The treatment setting 60		
7.2	Positioning the patient 60		
7.3	Ergonomics 60		
7.4	Practical procedure for the combined needling/PRP treatment 60		

7.4.1	Preparing the patient	60	10	Aids for the practitioner	175
7.4.2	PRP harvesting	62		Documentation forms	176
7.4.3	Materials required	64		Merz scales	177
7.4.4	Treatment	65		Patient information sheet for PRP treatment	183
7.5	Aftercare	68		Patient disclosure form	186
7.5.1	Immediately after the treatment	68		Patient informed consent form	187
7.5.2	Managing adverse treatment effects	68			
8	Regional applications	70	11	Appendix	189
8.1	Forehead	72		References	190
8.2	Periorbital region	76		Manufacturer directory	193
8.3	Lower lid region	80		Index	194
8.4	Perioral region	84			
8.5	Nasolabial region	88			
8.6	Chin region	92			
8.7	Cheek/side of the face	96			
8.8	Nasal region	100			
8.9	Neck region/décolleté	104			
8.10	Hands	108			
9	Case histories	115			
	Patient 1	115			
	Patient 2	121			
	Patient 3	127			
	Patient 4	133			
	Patient 5	139			
	Patient 6	143			
	Patient 7	149			
	Patient 8	155			
	Patient 9	161			
	Patient 10	167			

1 Skin repair and skin regeneration as a therapeutic principle

Damage to the integument is associated with visible and sometimes also perceptible changes in the skin, which may necessitate medical and/or cosmetic treatment. Wrinkles, lax skin, stretch marks or scars all represent potential indications for a corrective cosmetic procedure. This is particularly true in areas of skin that are permanently visible, such as the face and hands, but can also apply to any other part of the body. Aging skin, on the other hand, is increasingly more likely to be subject to benign and malignant neoplastic transformation.

Thus, the incidence of superficial non-melanoma skin cancer (NMSC; also known as non-melanocytic tumours or white skin cancer) in the Western hemisphere is rising constantly and appreciably (Gurtner et al. 2008). The two types listed below are the most common:

- Superficial basal cell carcinoma (BCC) in the form of superficially differentiated or solid basal cell carcinomas → Fig. 1.1),
- Actinic keratosis (AK; synonym: squamous cell carcinoma in situ) (→ Fig. 1.2).

A major problem in this context is the commonly seen, extensive spread of cancer cells, known as field cancerization.

When structural damage to the skin needs to be remedied, one established therapeutic principle in aesthetic medicine is based on initiating the skin's own regenerative potential, bringing about remodeling and the formation of new structures, eventually resulting in repair of the altered tissues.

The aim of such medical procedures is to improve the appearance and function of the skin, while avoiding post-interventional damage as far as possible. Accordingly, the ideal therapeutic intervention aimed at improving the skin activates only those processes that are associated with natural skin regeneration:

- repair of the epidermis, no destruction
- repair of the dermis with scarless wound healing
- stimulation of collagen synthesis, no fibrosis
- stimulation of endogenous growth factors

The most widely used skin-rejuvenating methods, such as extensive laser resurfacing or chemical peels, only go part of the way to meeting these requirements. Since their use is always associated with epidermal or even dermal ablation, these procedures are risky and may not always result in improvement; instead, they may even cause worsening of the initial condition.

Significant findings about wound healing following multiple microtraumas have been made while developing the concept of fractional photothermolysis. Provided that the microscopically small trauma does not exceed certain dimensional limits, i.e. as long as a sufficient number of areas are always left untreated, one can induce an astounding regeneration potential. Nowadays, the concept of fractional skin treatment is implemented using a great variety of methods: ablative and non-ablative lasers, needling, radiofrequency and ultrasound are firmly established variants. They address either only the epidermal or dermal compartment, or both.

The method of percutaneous collagen induction, known mainly as "needling" in everyday practice, is a method that almost ideally fulfills the requirements of skin-regenerating therapy. As a result of its auto-regenerative, but only microscopic destructive effect, it allows structural changes ranging from minor to severe to be treated safely and effectively. Fractional photothermolysis is also suitable for the treatment of numerous dermatological disorders and is more effective in certain areas than previous methods.

The indications for these microperforation methods have been extended with the increased introduction of topical agents; this is known

1

Skin changes in superficial non-melanoma skin cancer

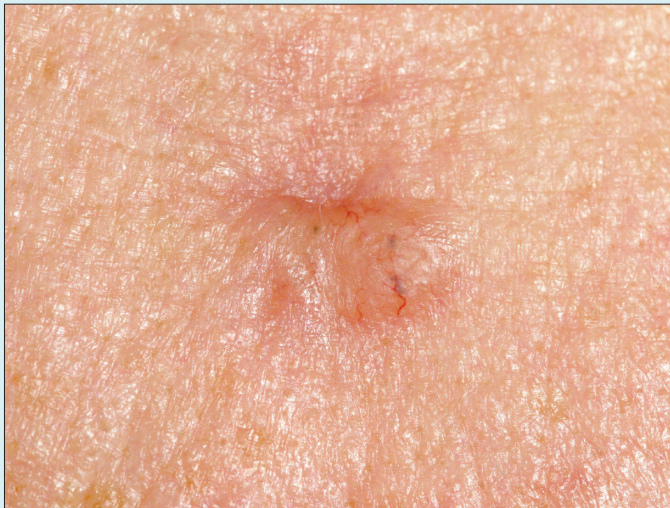

Fig. 1.1 Basal cell carcinoma is the most common non-melanoma skin cancer in humans.

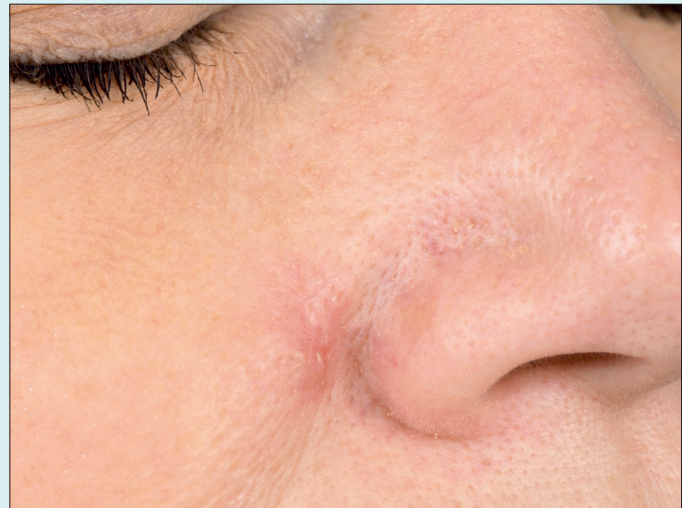

Fig. 1.2 Actinic keratosis is the second most common non-melanoma skin cancer in humans.

as device-assisted drug delivery (DAAD). The latter has been successfully used by experienced medical practitioners for the treatment of malignant non-melanoma skin cancers, in the form of laser-assisted photodynamic therapy. The concept is undergoing constant refinement; for example, it is being used in combination with daylight or alternative light sources similar to daylight. The coagulation zone, which prevents heavier bleeding, is particularly significant in this respect. The most recent studies show that this zone acts as a sponge-like reservoir for the introduced molecules (Lee et al. 2011).

In contrast to this, the intensified needling technique initiates intradermal bleeding, which directly stimulates the dermal wound healing cascade, thereby inducing the desired neocollagen synthesis. Keratinocytes migrate to the area, proliferating and leading to regeneration of the dermis. The most recent developments in the area of platelet-rich plasma (PRP) indicate that the introduction of PRP into microperforated skin by means of DADD, in the context of aesthetic medicine, allows skin repair and skin regeneration to be achieved in a controlled and efficient manner, with few side effects.

1.1 Wound healing and cicatrization

1.1.1 Physiology of wound healing

Injuries to the integument disrupt its barrier function, with a great variety of consequences; for this reason, prompt wound healing with the aim of restoring the skin to its original condition is an essential requirement. However, the latter is not possible *ex utero*, and even the best wound healing is always associated with the formation of a scar, i.e. cicatrization. The most recent studies indicate new ways of achieving further improvements in wound healing, although there is, as yet, no way of avoiding scars entirely once the basal membrane is injured. Classical wound healing takes place in phases.

■ Phases of wound healing

Under normal physiological circumstances, wound healing proceeds according to a very strictly controlled spatiotemporal sequence including a variety of events. Classical wound healing may be divided into four overlapping phases:

- **Exudation** (days 1 to 4): Wound healing processes are initiated by injury to the blood vessels. Platelets and neutrophilic granulocytes secrete a variety of growth factors. The wound is temporarily closed.
- **Absorption** (days 1 to 10): Inflammatory cells (granulocytes, macrophages) migrate into the wound region. Cell fragments are broken down, and more growth factors and inflammation mediators (cytokines, chemokines, prostaglandins) are secreted. The messenger substances attract inflammatory cells and fibroblasts and stimulate their synthesizing activity.
- **Proliferation and epithelialization** (days 3 to 24): Granulation tissue is formed, initially interspersed with numerous blood vessels. Incoming fibroblasts synthesize increased levels of collagen and elastin. The new collagen fibres strengthen the granulation tissue, while keratinocytes migrate into the area and proliferate to form an epidermal layer over the granulation tissue.

- **Repair and regeneration** (day 24 to 1 year): The newly formed collagen fibres form a network while the capillaries degenerate. The tissue becomes increasingly stronger, with fewer blood vessels. It may take several months for the regeneration phase to be completed and for the connective tissue structures to reorganize.

The purpose of the initial inflammatory reaction is to eliminate defective tissue, foreign bodies and microorganisms. This is followed by the formation of new blood vessels and the activation of keratinocytes and fibroblasts, while connective tissue is replaced by the synthesis of extracellular matrix components (Gurtner et al. 2008). Clinically speaking, wound healing correlates with cicatrization. In the main, normal scars are adapted to the morphology and function of the surrounding skin, do not disrupt its function and are resistant to stresses and strains. When compared to healthy skin, scar tissue is characterized by a loss of skin appendages, the effacement of rete ridges, altered architecture and composition of the extracellular matrix components, and a qualitative impairment in mechanical properties.

■ Molecular mechanisms of wound healing

During the dermal wound healing cascade, tissue breakdown by the macrophages is instigated first, followed by the formation of new connective tissue (remodelling) by the fibroblasts. A substance that deserves special mention in connection with this rebuilding of the extracellular matrix structure is the cytokine TGF- β (transforming growth factor beta). It has a mitogenic effect on the fibroblasts, which are then stimulated into the neosynthesis and secretion of collagen, elastin, fibronectin and other components of normal, healthy connective tissue. Therefore, TGF- β plays a key role in the wound healing cascade and its outcome. Depending on the traumatic stimulus, i.e. the nature of the injury, various TGF- β subtypes may be formed by the inflammatory cells in the initial phase, which have regulatory effects on different gene segments in the fibroblasts. Therefore, dermal remodelling and the quality of the skin once the repair and reconstruction phase has been completed is controlled by a molecular regulatory mechanism.

Studies have shown that TGF- β_3 is of particular significance in the construction of a physiologically intact collagen network (consisting predominantly of collagen I fibres). Conversely, TGF- β_1 and TGF- β_2 are linked to wound healing with cicatrization and the formation of collagen III fibres in parallel array, instead of the normal fine mesh structure. Wounds produced on embryos *in utero* can heal without scarring (Ferguson et al. 2004; Larson et al. 2010). They are characterized by high levels of TGF- β_3 and, at the same time, very low levels of TGF- β_1 and TGF- β_2 . In contrast, TGF- β_1 and TGF- β_2 predominate in adult wounds.

Adequate concentrations of vitamin A in combination with sufficient antioxidants have been shown to counteract the skin's aging process, by stimulating repair mechanisms while also providing protection from free radicals. Vitamin A controls the proliferation and differentiation of all the epidermal and dermal cell series and is thus essential for the maintenance of the skin's physiological processes, including wound healing, and for constructing the extracellular matrix, by optimizing collagen synthesis and the production of glycosaminoglycans by the fibroblasts. In addition, vitamin A promotes the

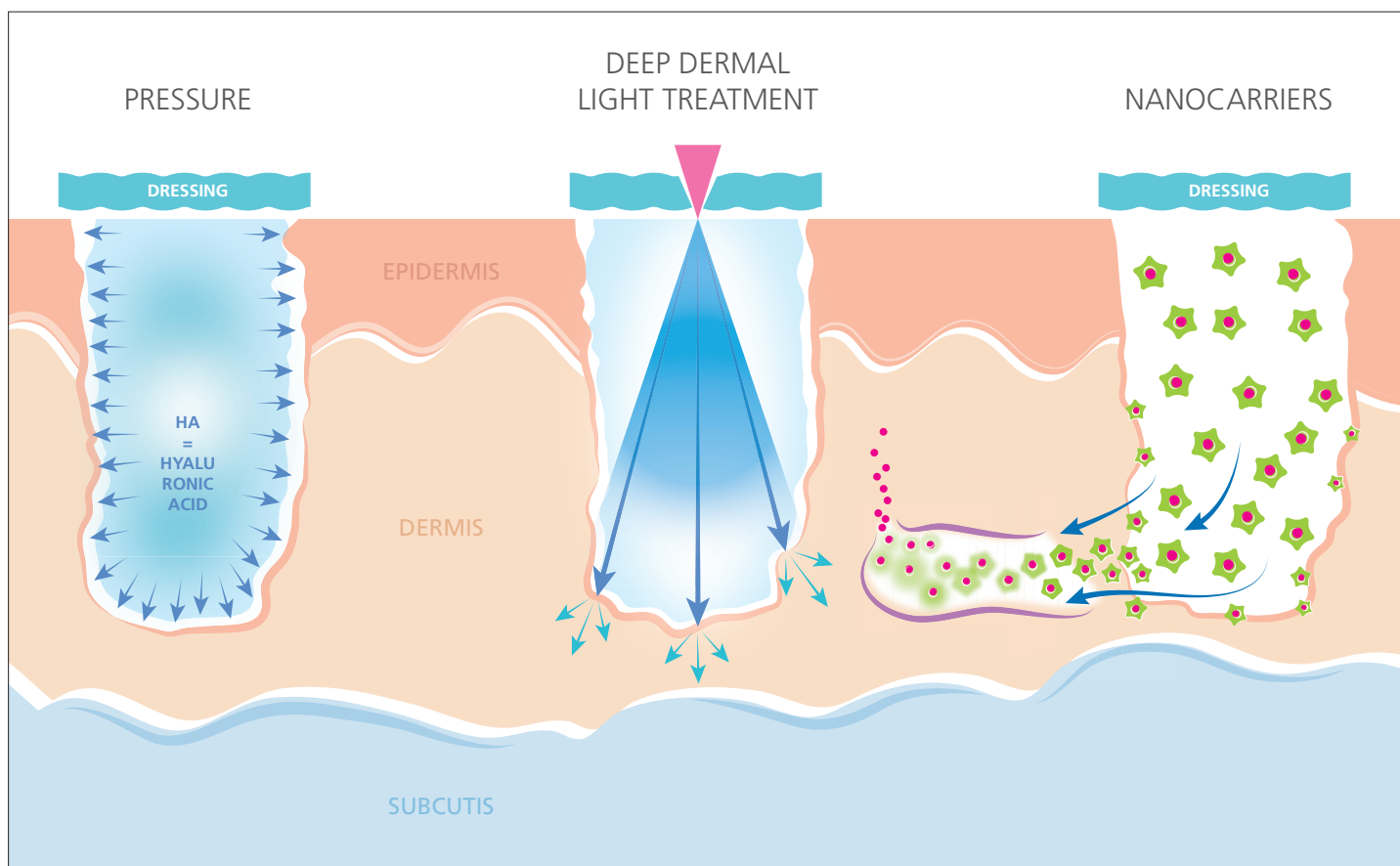


Fig. 1.29 Schematic representation of optional methods for the effective topical, microperforation-assisted introduction of active substance into the skin (from: Paasch 2013).

1.2.2 Laser- and microplasma-assisted PRP therapy

The stimulating effects of PRP on wound healing strongly suggests its use following laser-induced microperforation of the skin and gives reason to hope that there may be synergistic effects as well (Hui et al. 2017; Shin et al. 2012). When compared to AFXL monotherapy with a CO₂ laser, areas that are subsequently treated with PRP show better healing. However, instances of post-therapeutic hyperpigmentation have been described (Uysal & Ertas 2017). Better healing has been observed with acne scars subjected to a combined treatment consisting of AFXL, using either an Er:YAG (Zhu et al. 2013) or CO₂ laser (Lee et al. 2011; Petrov 2016), followed by PRP.

1.2.3 Needling-assisted drug delivery

The microperforation caused by needling has the advantage of extremely low device costs. Initially designed as rollers, motor-based systems with single-use attachments rapidly emerged. Today, needling is widespread throughout the world and is used for the treatment of

numerous conditions such as scars, lines, dermatochalasis and so on. In contrast to laser treatment, there is absolutely no coagulation in the tissue (→ Fig. 1.28), which is why blood is discharged from the perforation channels. The idea that the outflow of liquid might prevent the introduction of substances prompted the idea of developing microplasma rollers (→ Fig. 1.30), which have ablation profiles that strongly resemble those of lasers (→ Fig. 1.27).

As with lasers, the first successes were reported in combination with topical agents. If not as effective, needling can be used to intensify PDT to a certain extent. In addition, it uses active substances which are intended to accelerate wound healing and intensify remodelling. These include PRP (Asif et al. 2016), glycolic acid (Rana et al. 2017), hyaluronic acid (→ Fig. 1.31), vitamins and even intact cells (Gualeni et al. 2017).

Other possible ways of ensuring the effective introduction of active substances include the alternating application of pressure and vacuum (Erlendsson et al. 2016) or the use of ultrasound (sonoporation) (→ Fig. 1.32 and 1.33).

The introduction of active substances by needling

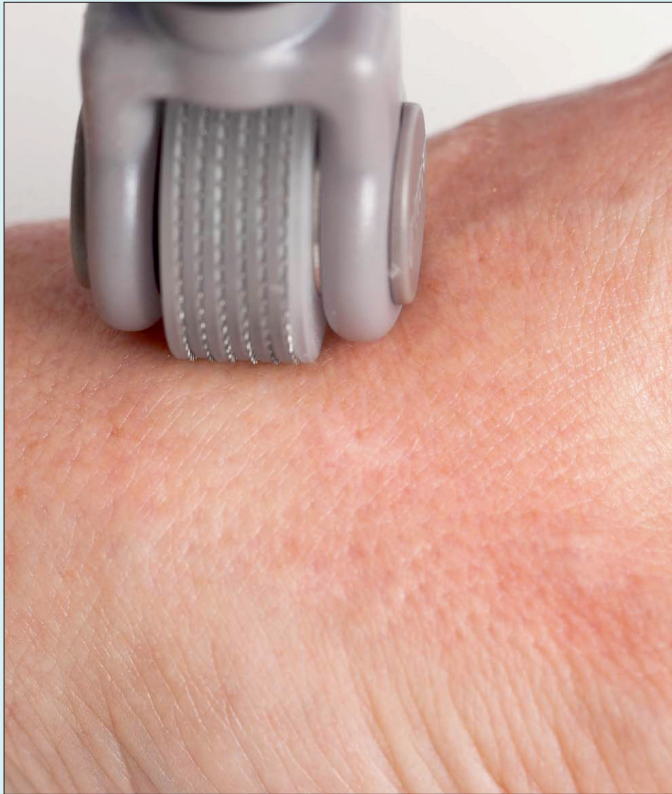


Fig. 1.30 Legato microplasma roller (Alma Lasers GmbH).

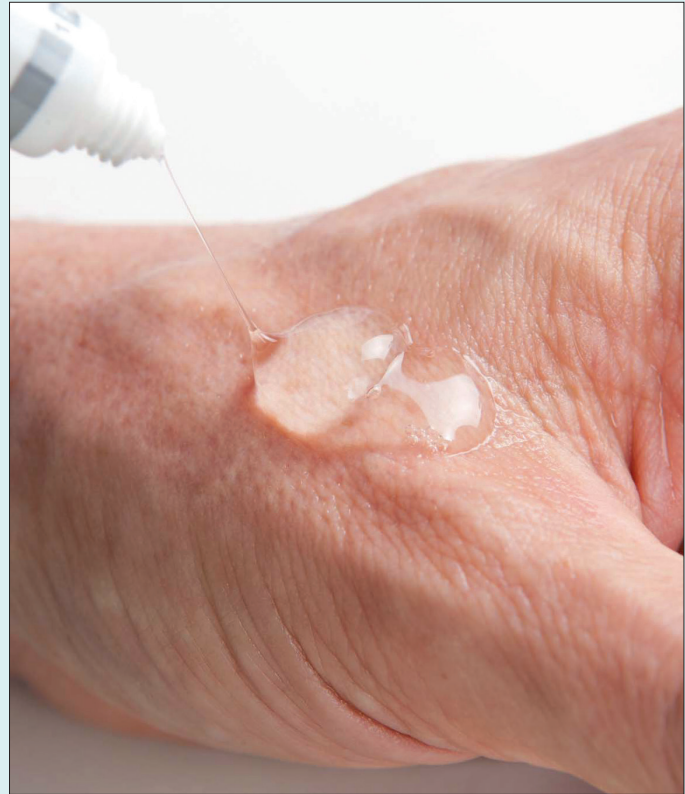

Fig. 1.31 Hyaluronic acid applied following microperforation can enhance remodelling.

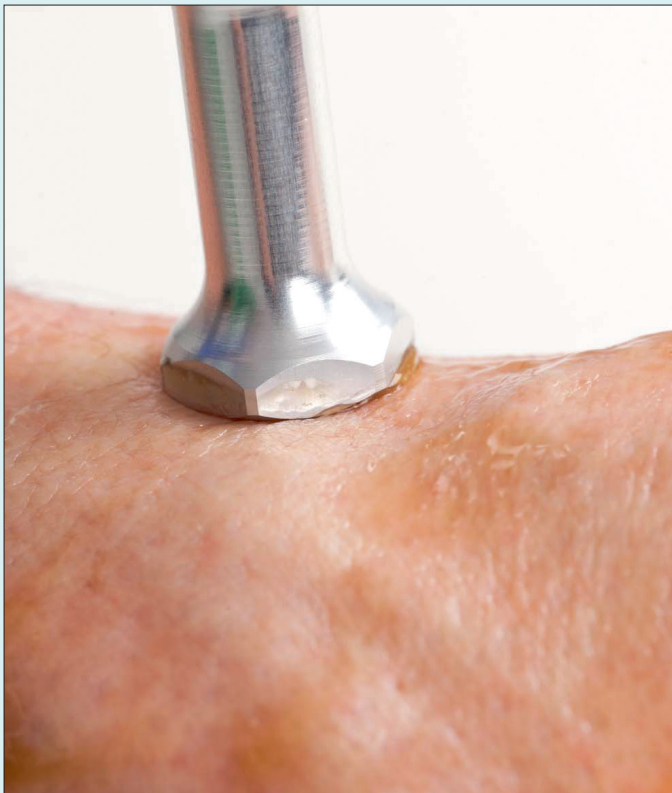

Fig. 1.32 Sonoporation (Impact, Alma Lasers GmbH) facilitates the introduction of active substances following microperforation.

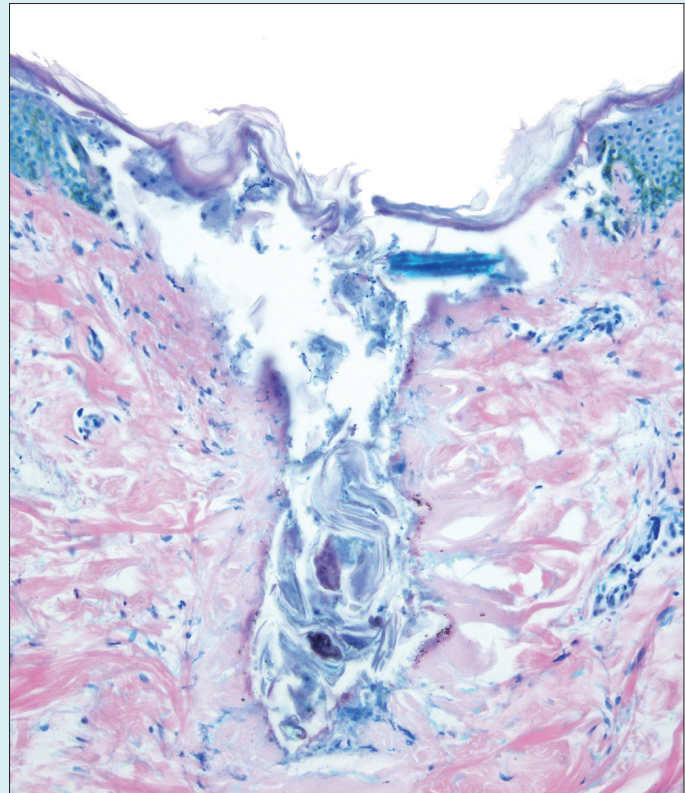


Fig. 1.33 Microperforation zone following application of a hyaluronic acid by sonoporation.

2 PRP in aesthetic medicine

2.1 Introduction

According to Marx's definition, platelet-rich plasma (PRP) is a volume of autologous plasma that has a platelet concentration (in full blood) above baseline (Marx 2001). The first clinical trial, in maxillary surgery, dates back to 1998 (Marx et al. 1998), while case histories involving the treatment of wound defects with patients' own (autologous) blood go right back into the 1960s (Schulte 1960). Currently (in 2019), PubMed contains more than 9,000 entries with the keyword "platelet rich plasma".

For years, PRP has been used successfully in dermatology, plastic surgery and aesthetic medicine, and also in orthopedic medicine, sports medicine, trauma surgery, oral and maxillofacial surgery and dentistry.

2.2 Mechanism of action

Platelets contain a great variety of growth factors: in 2001, Marx described seven growth factors found in PRP (Marx 2001). Since then, it has been assumed that more than 1500 growth factors and regulatory proteins are responsible for the effects of PRP. An exact breakdown of all these factors is yet to be made (Wu et al. 2011). In their review, which focuses on dermatology, Arshdeep & Kumaran (2014) listed the growth factors and their effects shown in Table 2.1.

The growth factors are released following endogenous or exogenous activation of the platelets and have a chemotactic effect, as well as a direct and indirect tissue-regeneration effect.

Some of the platelets are already activated during centrifugation due to mechanical effects. Endogenously, platelets are activated by collagen; needle-induced bleeding during the PRP injection may also contribute endogenous clotting factors (DeLong et al. 2011). Exogenous activation through the addition of foreign substances such as CaCl_2 seems to be becoming less popular.

Fibroblasts, mononuclear leukocytes and mesenchymal stem cells are attracted by PRP and their proliferation is stimulated. The literature provides indications that the optimal platelet concentration is approx. 2.5 times higher than baseline, as less potent fibroblast stimulation and proliferation has been observed at both higher and lower levels (Graziani et al. 2006). Moreover, the highest secretion of endogenous hyaluronic acid and procollagen type 1 by skin fibroblasts has been described at a platelet concentration in this range (Anitua et al. 2009).

For most uses, PRP should contain as few erythrocytes and leukocytes as possible, since the breakdown of pro-inflammatory cytokines in the erythrocytes can lead to the formation free radicals, which can damage the tissue being treated. If present at excessive concentrations, leukocytes can also produce negative effects due to the release of proteases (Belcher et al. 2010; Diegelmann & Evans 2004; Martin & Leibovich 2005). A leukocyte-rich PRP can be beneficial in the treatment of chronic wounds, as a means of achieving natural debridement.

2.3 Clinical effect

From the clinical point of view, PRP has positive effects on the texture, luminescence, hydration, thickness and elasticity of the skin, and can

Growth factors	Effects
PDGF- $\alpha\alpha$, $\alpha\beta$, $\beta\beta$ (platelet-derived growth factor)	<ul style="list-style-type: none"> Chemotactic for fibroblasts and Macrophages Mitogenic for fibroblasts, smooth muscle cells and endothelial cells
TGF- β_1 , β_2 (transforming growth factor)	<ul style="list-style-type: none"> Mediates angiogenesis Chemotactic for fibroblasts, keratinocytes and macrophages Mitogenic for fibroblasts and smooth muscle cells Inhibits endothelial cells, keratinocytes and lymphocytes Regulates matrix proteins including collagen, proteoglycans, fibronectin and matrix-degrading proteins
VEGF (vascular endothelial growth factor)	<ul style="list-style-type: none"> Chemotactic and mitogenic for endothelial cells Mediates angiogenesis
EGF (epidermal growth factor)	<ul style="list-style-type: none"> Mediates angiogenesis Mitogenic for fibroblasts, endothelial cells and keratinocytes
HGF (hepatocyte growth factor)	<ul style="list-style-type: none"> Mediates regeneration
FGF (fibroblast growth factor)	<ul style="list-style-type: none"> Mediates tissue organization and regeneration
FGF-9	<ul style="list-style-type: none"> Encourages the generation of new follicles

Tab. 2.1 Growth factors and their effects, focusing on dermatology (Arshdeep & Kumaran 2014).

produce mild volume-enhancing effects. Fine lines, nasolabial folds, crow's feet and rings under the eyes can be successfully treated with PRP (Cameli et al. 2017; Elnehravy et al. 2017; Leo et al. 2015). The literature also contains reports of positive effects following PRP treatments in hairy regions of the skin, namely in androgenetic alopecia and alopecia areata (Donovan et al. 2015; El Taieb et al. 2017; Gupta & Carviel 2017; Trink et al. 2013). The positive effects of PRP are enhanced by multiple applications. Since the results of this regenerative therapy occur only gradually over a number of weeks or months, good photo documentation and a detailed information session are especially relevant. This ensures high patient compliance and satisfaction.

2.4 Contraindications

PRP treatments should not be performed in patients with skin tumours, active infections, hepatitis, HIV and syphilis. Herpes prophylaxis is a good idea in predisposed patients, as with any other more invasive procedures in aesthetic medicine. Table 2 provides an overview of how to manage anti-platelet drugs and anticoagulants (Ramsook & Danesh 2016). A risk/benefit assessment should always be carried out before any medication is discontinued. In most cases, however, there will be no question of discontinuation. In that event, the patient should be informed about an increased risk of haematomas and reduced efficacy.

Acetylsalicylic acid (aspirin) acts as an antagonist, i.e. it decreases platelet synthesis as a result of its inhibitory effect on the clotting system, thus reducing the efficacy of a PRP treatment. For this reason, higher-dose products (> 250 mg) should not be taken one week before and after the treatment.

2.5 Side effects

Since PRP is an autologous product, any side effects are not usually serious. Swelling, reddening, bruising, throbbing or a feeling of tightness are possible side effects. Other injection-related side effects, such as flare-up of a herpes infection, are also possible (Cameli et al. 2017).

2.6 Treatment failures

Failure to respond to PRP treatments may occur, for reasons that have not yet been sufficiently explained. Possible causes of a reduced PRP effect that come into consideration include thrombocytopenia, autoimmune disorders, hypothyroidism, vitamin D deficiency and nicotine abuse.

2.7 The use of PRP in hair loss

Hair loss is a widespread problem in Europe; conditions that are particularly significant include androgenetic alopecia, with a prevalence of up to 80% in European men and 50% in women, and alopecia areata, which has an incidence of 1.7% (Hoffmann & Altmeyer 2007; Piraccini & Alessandrini 2014). In women, both forms should always be interpreted as being pathological, whereas androgenetic alopecia occurs so commonly in men of more advanced age that it is regarded as a normal phenomenon of aging (Hoffmann & Altmeyer 2007; Piraccini & Alessandrini 2014). The causes of hair loss are many and varied; metabolic disorders, infectious diseases or drug side effects

Active substance	Discontinuation before the procedure	Resumption after the procedure
Abciximab	48 hours	2 hours
Acetylsalicylic acid (aspirin)	8–9 days	2 hours
Apixaban	26–30 hours	4–6 hours
Clopidogrel	7 days	6 hours
Dabigatran	7 days	5 days
Eptifibatide	4–8 hours	2 hours
Fondaparinux	36–42 hours	6–8 hours
Heparin	2–4 hours	1 hour
Non-steroidal anti-inflammatory drugs	24 hours	2 hours
Low-molecular-weight heparins	Prophylactic use: 10–12 hours Therapeutic use: 24 hours	Prophylactic use: 6–8 hours Therapeutic use: 2–4 hours
Prasugrel	7–10 days	6 hours
Rivaroxaban	22–26 hours	4–5 hours
Ticagrelor	5 days	6 hours
Tirofiban	4–8 hours	2 hours
Warfarin	4–5 days	2 hours

Tab 2.2 Recommendations for the discontinuation and resumption of anti-platelet drugs and anticoagulants during a PRP treatment.

4.2.3 Injector

An injector (→ Fig. 4.4) which combines needling with an injection of PRP was available as a prototype (expected to become commercially available in 2019). A multi-needle attachment is used to introduce the PRP directly into the dermis at defined depths. This allows all treatment areas to be infiltrated selectively and reproducibly. Overall, the system consists of an injector unit, a syringe filled with PRP, a spacer that is used to preset the injection depth, and a multi-needle tip. Placing the injector unit vertically onto the skin generates a defined vacuum, which draws up the skin and allows a preset volume of PRP to be applied at a pre-specified depth. The advantage of this accurately controlled application method is that individual areas can be treated not only selectively but also, and above all, reproducibly. In the author's view, therefore, this intradermal application method could become the gold standard of infiltration therapy.

4.3 Puncture depth

Puncture depths ranging from 0.5 to a maximum of 2.0 mm are favoured in the outpatient setting (→ Fig. 4.5). These reach the basal membrane layer, inducing minimal petechial bleeds in the papillary dermis. This is sufficient to activate the TGF- β_3 signal cascade, with collagen synthesis and a skin-regenerating effect. The intradermal

lesions are so minor that there is hardly any downtime. The effect is enhanced by the added application of PRP through the puncture channels.

The choice of penetration depth is dependent on

- The location
- The condition of the individual's skin
- The desired effect

The sites demonstrated and documented here are mainly on the face, neck and hands.

The thickness of the dermis and epidermis varies enormously, even within the face alone (→ Fig. 4.6). In addition, there are also age-related variations. The skin of older people is generally more fragile and thinner, so that puncture depths of 0.5–0.8 mm may well be sufficient here.

Note

When treating the face, it is not possible to work gently, selectively and efficiently if using a fixed, pre-set puncture depth.

Aquapen 2 injector




Fig. 4.4 Aquapen injector. **a.** Injector unit with syringe. **b.** Multi-needle attachment with five fine needle tips through which the active substance can be injected simultaneously. **c.** Different spacers can be used to achieve the desired dermal puncture depths.

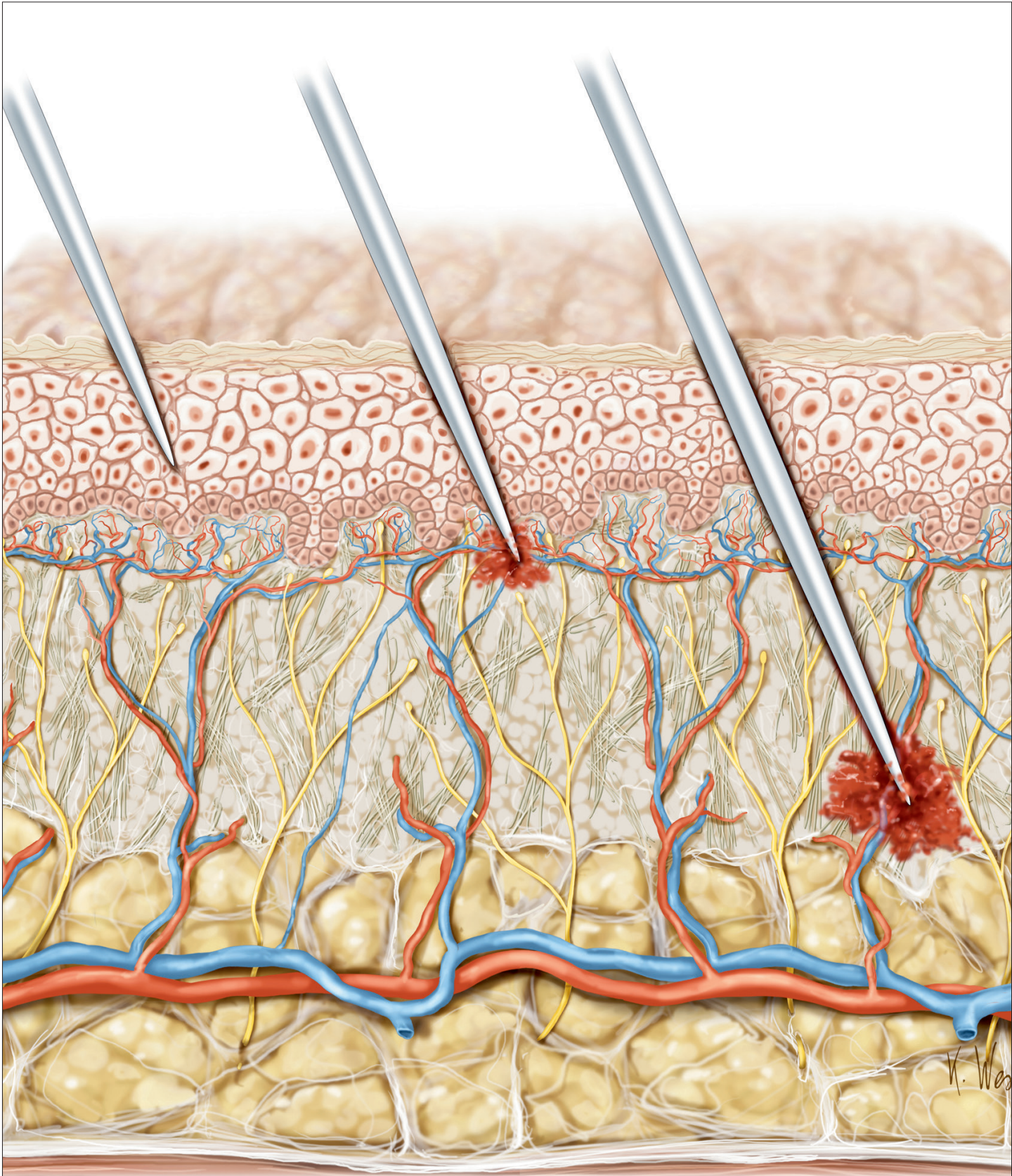


Fig. 4.5 Schematic representation of needling techniques in a cross section of the skin. Different needle lengths are used in practice, depending on the indication. Apart from the purely epidermal cosmetic needling technique, used primarily to transport topically applied active substances, there are two different methods of needling for collagen induction:

- Medical needling, using 1-mm (up to a maximum of 2-mm) needles, which extend to just below the stratum basale and cause minute haemorrhages in the papillary dermis,
- Surgical needling, using 3-mm needles, which reach from the reticular dermis to the subcutis, leading to heavy intradermal bleeding.

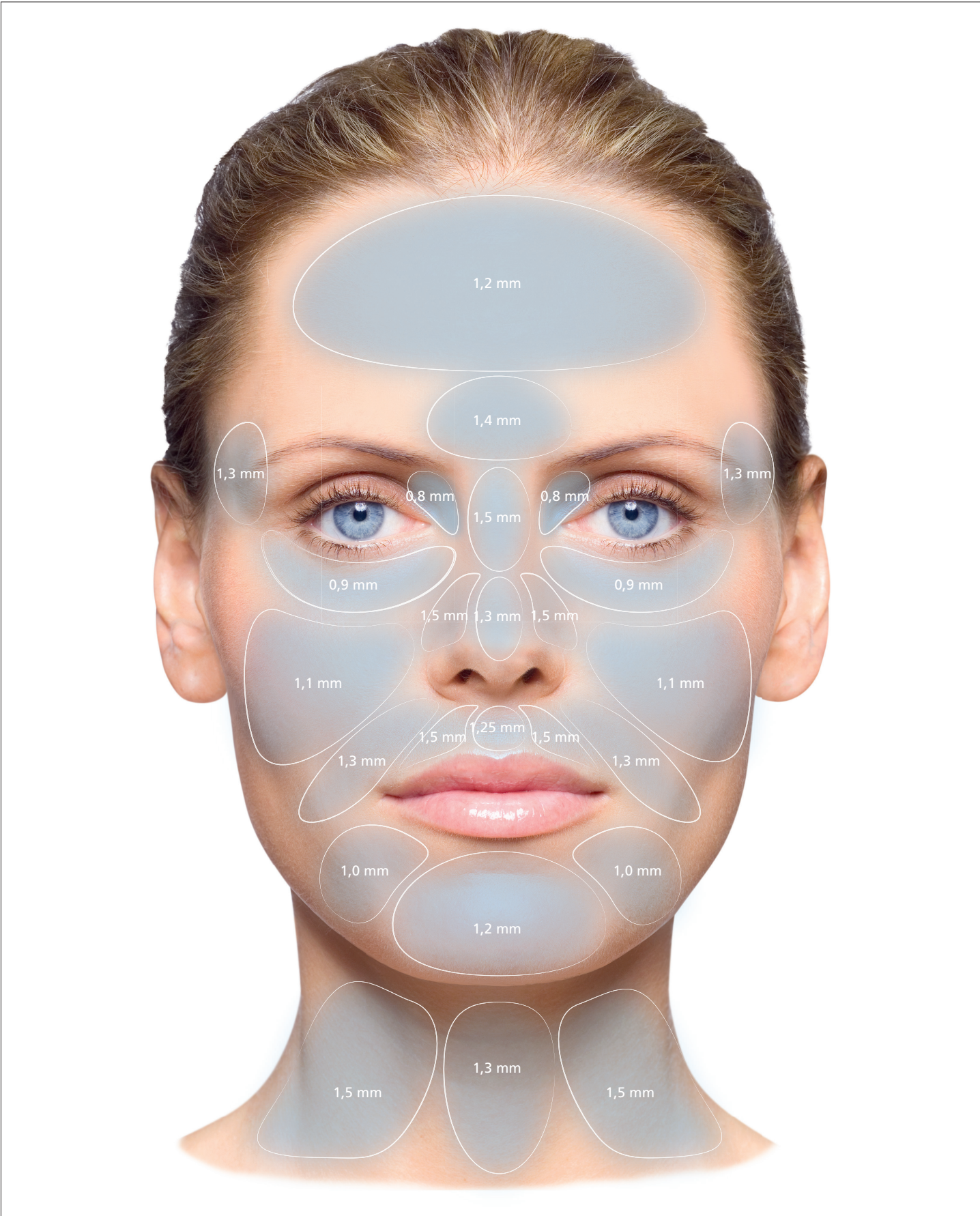


Fig. 4.6 Distribution of skin thickness (epidermis plus dermis) in various regions of the face and neck; modified from Chopra et al. (2015).

The fixed needle lengths on rollers make these devices unsuitable for a full-face treatment. Several rollers with different needle lengths would be needed to treat each region specifically. Electromechanically powered pens offer a more advantageous solution. They allow the puncture depth to be varied during the needling process. Their disadvantage is that the whole treatment takes a bit longer to perform.

4.4 Combined treatment options

In principle, the use of PRP can be combined with other components, autologous (the patient's own body fat) and non-autologous (e.g. hyaluronic acid). However, the combination of autologous body fat and PRP cannot be administered using the needling method described here.

4.4.1 Combination of PRP with hyaluronic acid

PRP can be mixed with hyaluronic acid (HA), at least in principle: however, the current body of evidence to support it is very weak. In our literature search, PubMed yielded one study in which PRP was mixed with hyaluronic acid and combined with microneedling, and one study where PRP was mixed with hyaluronic acid (Hersant et al. 2017; Ulusal 2017). The therapy was described as effective in both studies, and there were no serious side effects (Hersant et al. 2017; Ulusal 2017). The following limitations were quoted for the first of these studies: lack of a control group and the difficulty of identifying the individual roles of HA, PRP and microneedling (Hersant et al. 2017). The second study also lacked a control group (Ulusal 2017). These studies suggest that the mixture is safe; however, neither study

provides either indications or proof that adding hyaluronic acid to PRP has any advantages versus the use of PRP alone or the use of PRP plus microneedling.

4.4.2 PRP and lipofilling

The current guideline "Autologous Fat Grafting" from the German Association of Plastic, Reconstructive and Aesthetic Surgeons (Deutsche Gesellschaft der Plastischen, Rekonstruktiven und Ästhetischen Chirurgen, DGPRÄC) contains the following sentence: "The addition of platelet-rich plasma (PRP) may be considered." Analysis of the literature as regards the effects of adding PRP is tricky, since the individual publications are difficult or impossible to compare due the great variety of methods used.

The results of a recently published double-blind, placebo-controlled, randomized study of lipofilling in the face show that the addition of PRP significantly reduces downtime, but fails to produce a significant improvement in skin elasticity, volume retention or patient satisfaction when compared to conventional lipofilling (Willemsen et al. 2017). The use of PRP at a concentration that was too high is one possible explanation for its minimal effects in the aforementioned study (Loibl et al. 2016). In contrast, a study of breast reconstruction with lipofilling and PRP also showed a considerable improvement in the maintenance of volume in the PRP group (69%) compared to the control group (39%) (Gentile et al. 2013). In the PRP group, centrifuged fat was mixed with PRP at a ratio of 2:1. The literature shows that the combination of PRP and lipofilling has definite potential; currently, however, it would still need to be viewed with a critical eye, especially if physicians were to design a specific treatment protocol based only on the literature and without conducting their own trials.

7 Treatment

This section describes the relevant conditions needed to optimize the chances of a successful treatment, ranging from the treatment planning to the management of undesirable treatment effects. The following steps should be taken before the treatment:

- Information session/consultation including an evaluation of the patient's wishes (→ Chapter 5.1, p. 38)
- Signing an informed consent form (→ Chapter 6.4, p. 56)
- Examination with photographic documentation of the baseline findings (→ Chapter 5.2, p. 38 onwards and Chapter 6.1, p. 48 onwards)

7.1 The treatment setting

The treatment setting and the atmosphere should communicate the maximum possible professionalism and care. A bright, well-ventilated treatment room set at a pleasant temperature helps to achieve this. Ideally, the area being treated should be easily accessible to the physician and any assistants from all sides. Although the whole treatment is time-consuming, it should not be performed under any time pressure. Experience has shown that, even with the optimum preparatory consultations, the patient may still ask further questions, express concerns or put forward additional therapy requests immediately before the treatment. The physician should react to these openly, patiently and without haste. An optimum treatment result is likely only with full patient compliance. In this respect, it is advisable to describe the planned treatment in detail one more time. The treatment itself should follow only after all remaining questions have been answered and any uncertainties laid to rest.

7.2 Positioning the patient

The treatment is usually carried out on a specialist treatment chair with smoothly adjustable height and back angle. If no such positioning option is available, the treatment may also be performed with the patient in a semi-sitting position. The level of the area being treated should be adjusted to the height of the physician, to ensure that the latter can do the work ergonomically, in an upright position and without straining the back. Treatment with the patient in a supine to semi-supine position not only allows the patient to relax more easily, but also makes application of the PRP easier.

7.3 Ergonomics

In this context, ergonomics involves ensuring that the physician can work in a posture that does not strain the back. An ergonomic posture without back strain allows him or her to carry out the treatment in a relaxed way, specifically aimed at avoiding back problems. Working with the upper body upright is one of the basic principles of an ergonomic posture. Twisting movements between the pelvis and pectoral girdle should be avoided. Any turning movements and postural changes should involve the whole body. Ensuring that the treatment area is at the physician's chest height provides the optimum working level. The physician's shoulders can hang loosely and the arm with which the PRP is administered can be supported by resting the elbow or forearm on the treatment chair. This allows a relaxed posture to be adopted during the application.

7.4 Practical procedure for the needling/PRP treatment

The treatment, consisting of needling combined with the administration of PRP, is a material-intensive, time-consuming process. There are various blocks of time which can be dovetailed for greater efficiency. The phases and sub-steps of the treatment are summarized in Table 7.1.

Treatment phase	Sub-steps
Preparing the patient	<ul style="list-style-type: none">▪ Cleansing the treatment area▪ Photo documentation▪ Topical local anaesthesia
PRP harvesting	<ul style="list-style-type: none">▪ Blood collection▪ Preparation of the PRP
Treatment	<ul style="list-style-type: none">▪ Disinfection of the treatment area▪ Needling plus PRP administration
Aftercare	<ul style="list-style-type: none">▪ Application of a soothing mask▪ Application of a moisturizing lotion

Tab. 7.1 Individual steps of the needling/PRP treatment.

7.4.1 Preparing the patient

Preparations for the procedure of needling in combination with PRP administration consist of the following individual steps, which apply to all treatment areas: cleansing, photo documentation, anaesthesia and disinfection.

Makeup or any residues of it should be removed completely with warm water or a cleansing lotion. After the skin has been cleansed, it is advisable to carry out photo documentation, which may be delegated to someone else. The treatment does not deliver any visible, ad hoc results. It is therefore sensible – and very impressive for the patient – for the treatment results to be documented photographically over the course of time.

Local anaesthetics are most commonly used in needling. The local application of anaesthetics in gel or cream form is generally sufficient for the methods described here (→ Fig. 7.1 and 7.2). It allows large areas to be numbed, providing satisfactory anaesthesia of the treatment area in most cases. The creams usually contain lidocaine at varying dose levels. One of the standard drugs is Emla® (AstraZeneca), a combination of lidocaine and prilocaine. To achieve adequate analgesia, the anaesthetic should be applied at least 30 to 40 minutes before the procedure and left to act under occlusion during this period (→ Fig. 7.3). The anaesthetic is then removed with swabs soaked in saline solution and the region being treated is disinfected with a skin disinfectant.

7.4.2 PRP harvesting

Several different PRP preparation systems are available. The authors use the Arthrex ACP® system. This consists of a double syringe which is a closed system, thus ensuring that the PRP is not contaminated during harvesting. The specifications are described in detail in Chapter 3 (p. 22 onwards).

Applying the topical anaesthetic cream

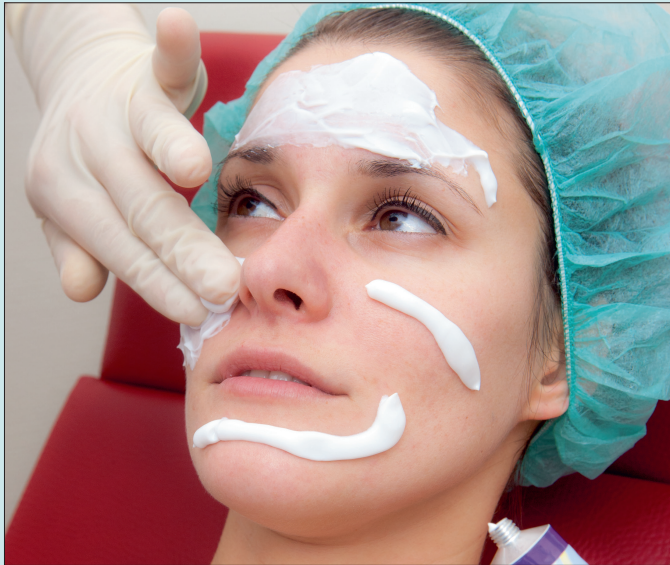

Fig. 7.1 The anaesthetic cream, e.g. Emla® (lidocaine and prilocaine) is generously applied to the cleansed and briefly neutralized skin (guide amount: 30 g/face).



Fig. 7.2 Once applied, the anaesthetic cream should extend up to the lip margins and close to the upper and lower eyelids.



Fig. 7.3 The anaesthetic cream is then left to act under occlusion for 30 to 40 minutes. The patient should be asked beforehand whether her mouth, as well as her nose, should be left uncovered.
Note: Do not occlude if using lidocaine/tetracaine topical agents.

■ PRP harvesting method

- Remove the double syringe from the packaging. The packaging also contains a red cap, which should be left in the packaging (→ Fig. 7.4).
- Withdraw both syringe plungers; holding the syringe in place by the barrel flanges, tightly screw in the inner syringe, turning clockwise. Now push both plungers back in and fit a butterfly needle onto the syringe.
- After disinfecting the skin, puncture a vein, preferably in the cubital region (→ Fig. 7.5).
- Pulling back on the red plunger wings, completely fill the system's outer cylinder (15 ml) (→ Fig. 7.6). The blood collection procedure can be facilitated if one person performs the aspiration itself, while a second person removes the venous access.
- Place the syringe onto the red cap from the packaging and twist. The cap now seals the syringe securely (→ Fig. 7.7).
- Place the sealed syringe into one bucket of the centrifuge (→ Fig. 7.8). Screw a lid onto the bucket. Place a counterweight into the opposite bucket.
- Centrifugation: Four minutes plus approx. two minutes to allow the centrifuge to come to a halt without braking. The G force is 350, calculated from the revolution rate and radius.
- After centrifuging, carefully remove the double syringe from the centrifuge, holding it upright.
- All the subsequent steps should take place with the syringe in this upright position, without shaking, to ensure that the two phases (PRP and blood cells) do not mix (→ Fig. 7.9).
- Aspirate approx. 4–7 ml PRP into the inner syringe (→ Fig. 7.10), leaving the last millilitre of fluid (corresponding to a single graduation line on the syringe scale), to ensure that the leukocytes, which are found in the interface layer between the red blood cells and the plasma, are not aspirated.
- The harvested volume of plasma depends on the patient's haematocrit and hydration level. The volume varies from patient to patient.
- Remove the inner syringe by unscrewing it anticlockwise (→ Fig. 7.11).
- The harvested PRP is now ready for use (→ Fig. 7.12). The Arthrex ACP® system contains no anticoagulants, and therefore needs to be administered within no more than half an hour. Should this prove impossible in exceptional circumstances, the option of adding an anticoagulant is still available.

PRP harvesting



Fig. 7.4 Arthrex ACP® kit in its packaging, from above.

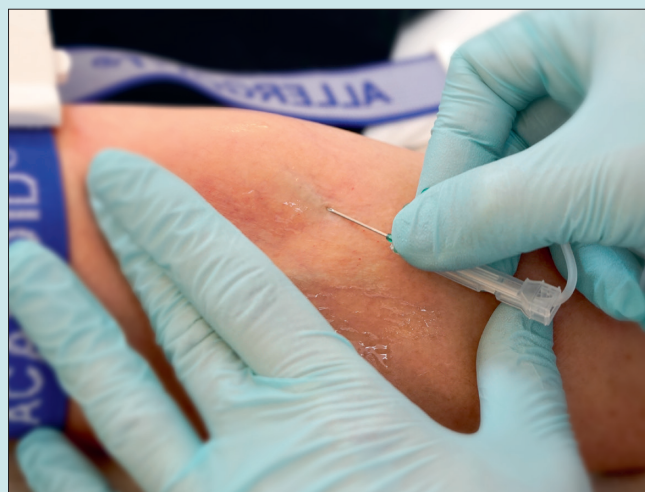

Fig. 7.5 Vein being punctured with the needle from the ACP syringe.

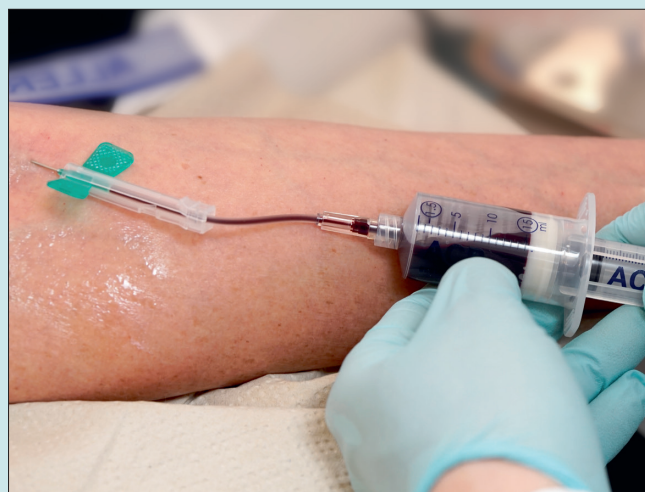


Fig. 7.6 Withdrawing blood from the vein using the ACP system.

PRP harvesting (continued)



Fig. 7.7 ACP syringe placed onto its cap, twisted and securely sealed.



Fig. 7.8 Syringe in the centrifuge.

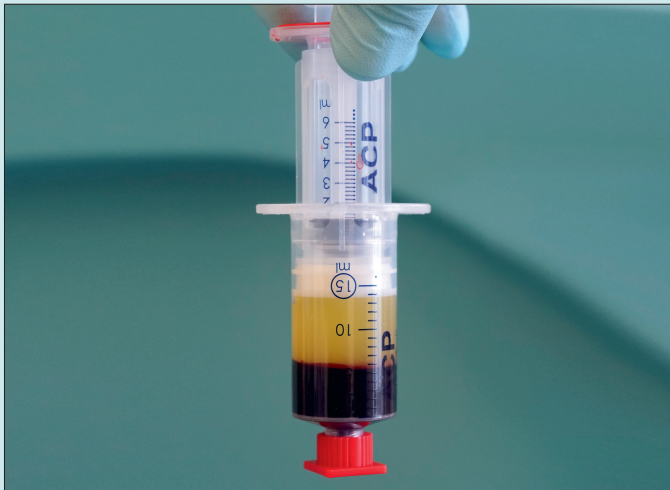

Fig. 7.9 ACP system: Syringe being held upright against a light background.

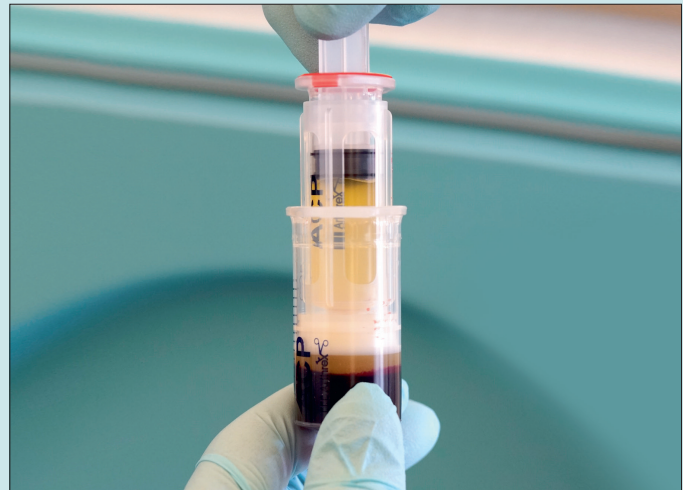

Fig. 7.10 Aspiration of approx. 4-7 ml PRP into the inner syringe.

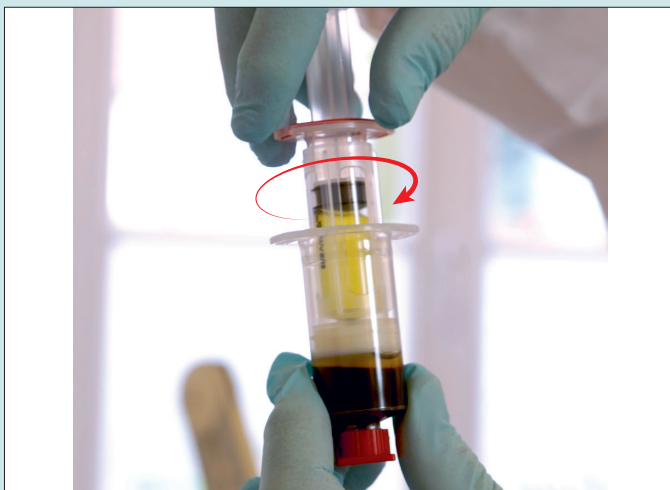

Fig. 7.11 The inner syringe of the ACP system should be removed by unscrewing anticlockwise.

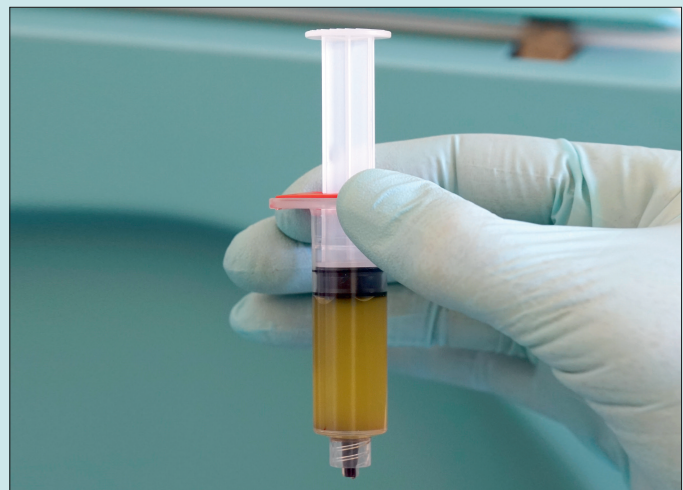
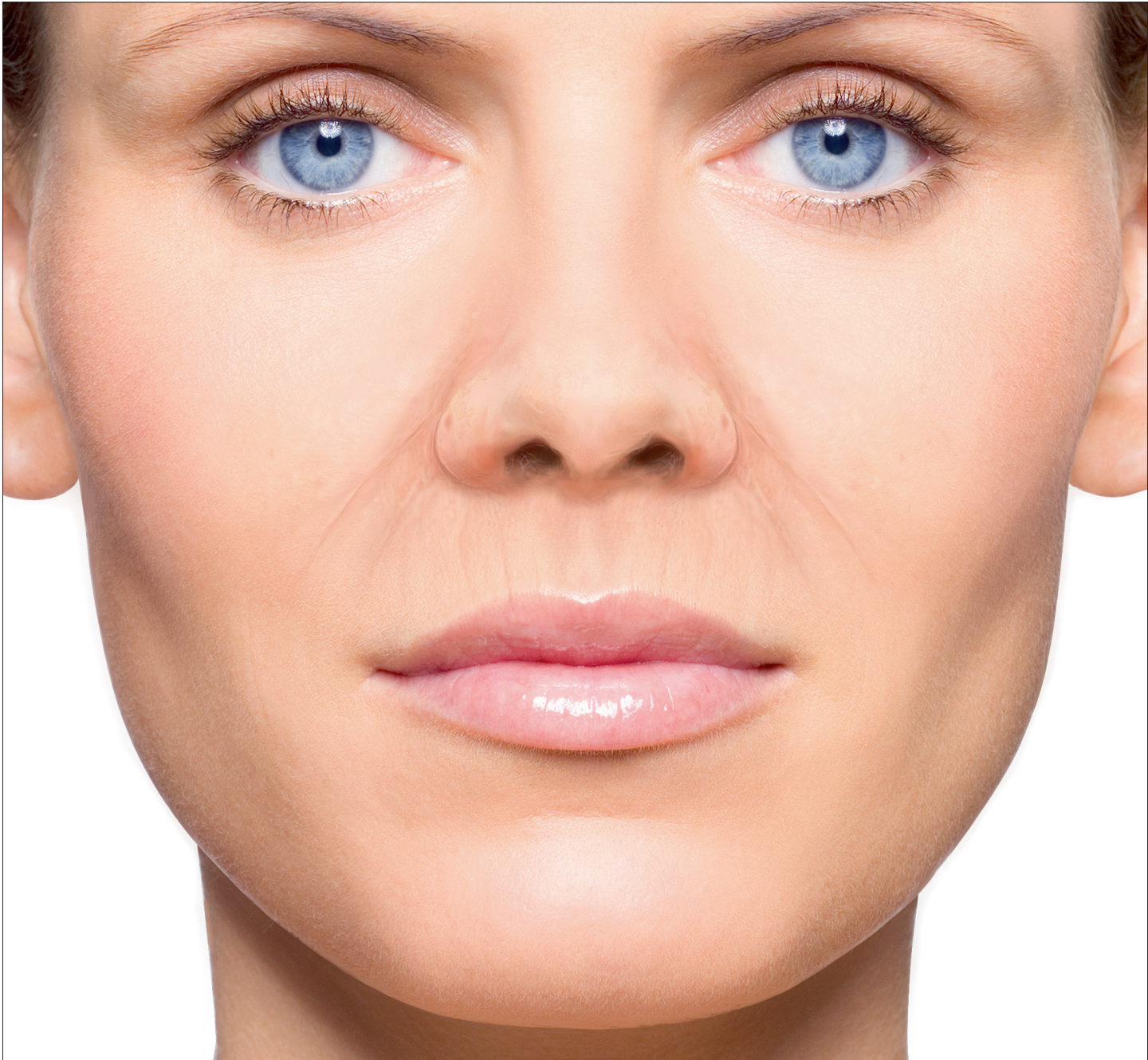
Fig. 7.12 Ready-to-use ACP syringe containing PRP.

8.5 Nasolabial region



8

Fig. 8.45 Fine nasolabial lines.

8.5.1 Examination findings

The nasolabial region is conspicuous for its more or less pronounced lines, referred to as nasolabial folds, accompanied by age-related elastotic skin changes (→ Fig. 8.45). In most cases, it is the nasolabial folds and the increasing sagging of the jaw line that patients find aesthetically troubling.

8.5.2 Patient selection/ assessment of the indication

The combination of PRP and needling tightens the surface of the skin, improves its overall consistency and volume, and leads to a more uniform skin appearance. Deep, pronounced nasolabial folds are difficult or impossible to treat with PRP and needling alone. Adjuvant treatment by direct injection of the nasolabial folds with PRP or a mixture of PRP and hyaluronic acid can be undertaken. The patient should be warned about these limitations during the information session.

8.5.3 Needling diagram

Treating the nasolabial region – diagram of the needling routes

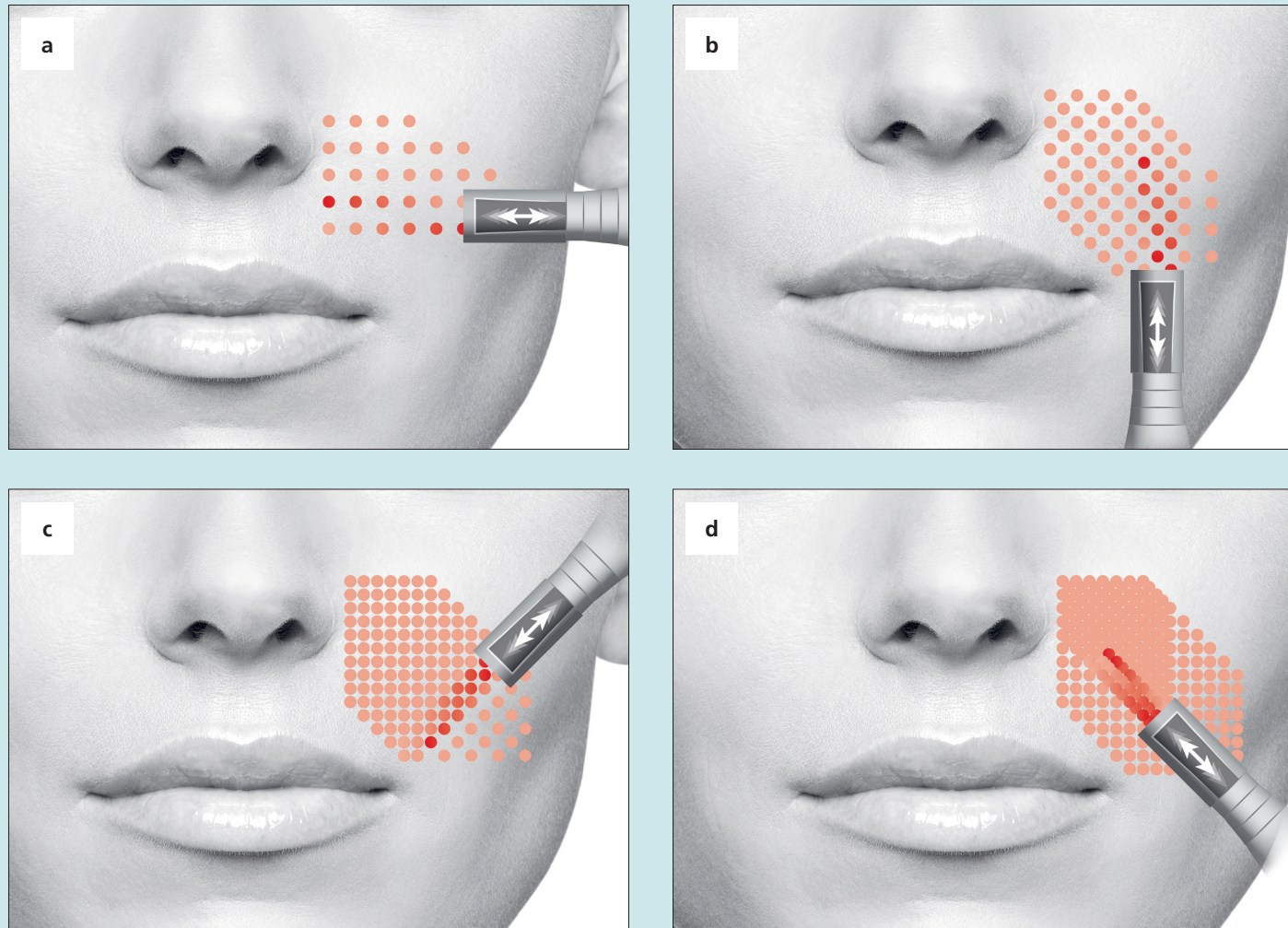


Fig. 8.46 Diagram showing the needling routes for the nasolabial region: **a.** going horizontally, **b.** going vertically, **c.** going diagonally from bottom left to top right, **d.** going diagonally from top left to bottom right.

8.5.4 Treatment protocol

Patient information: PRP and needling

- Thorough skin cleansing
- Application of an anaesthetic over the whole area
- The anaesthetic is left to act for 30–40 minutes
- Blood withdrawal
- Preparation of the PRP
- Removal of the anaesthetic with sterile saline solution
- Disinfection of the whole nasolabial region with a skin disinfectant
- Needling of the nasolabial region at a depth of 1.0–1.5 mm
- Infiltration of the PRP

- Application of a moisturizing mask
- Application of a moisturizing lotion

Post-treatment information for the patient

- Makeup may be applied after 24 to 48 hours
- A moisturizing lotion to be applied in the evening
- UV prophylaxis
- Repetition of the procedure after two to six weeks
- Herpes prophylaxis if there is a relevant predisposition

8.5.5 Practical procedure (→ Fig. 8.47–8.54)

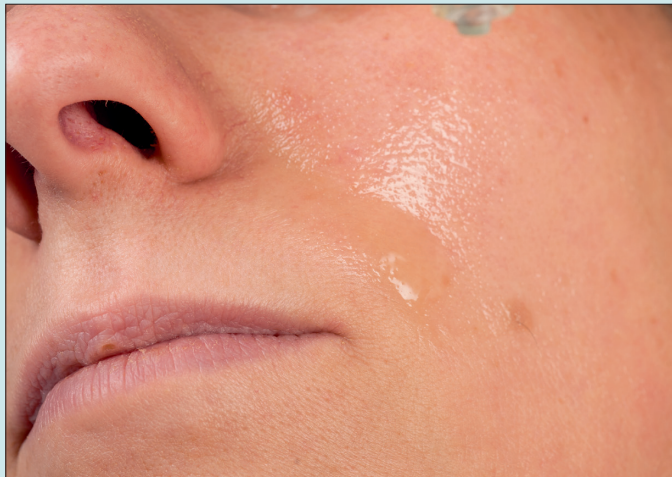

Fig. 8.47 Before the needling: skin disinfection and instillation of the PRP onto the area being treated, to allow the tip of the injection pen to glide easily over the skin.

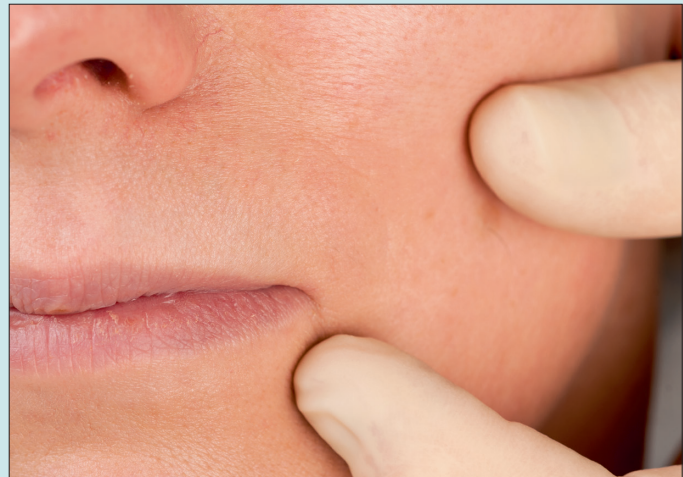

Fig. 8.48 The skin is gently stretched between thumb and forefinger across the direction of the lines or wrinkles.

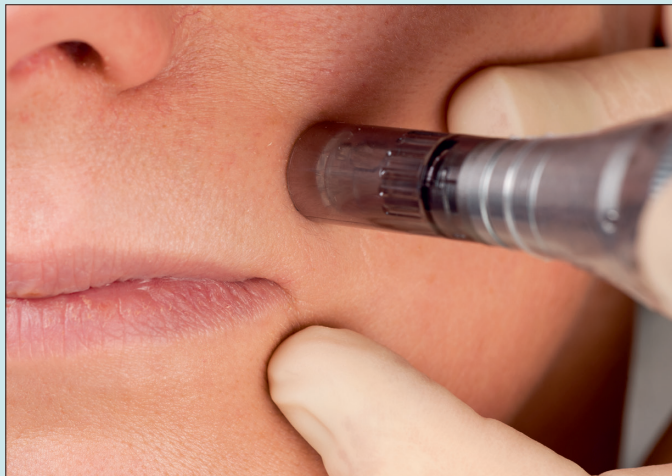

Fig. 8.49 The needling is performed using an injection pen with a sterile, single-use tip (12 needles). During the needling, the PRP is applied onto the nasolabial region drop by drop. It acts as a lubricant, allowing the pen tip to glide easily over the skin.

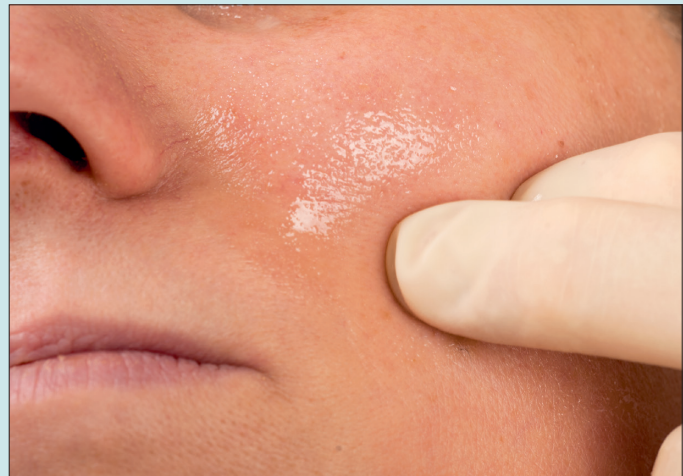

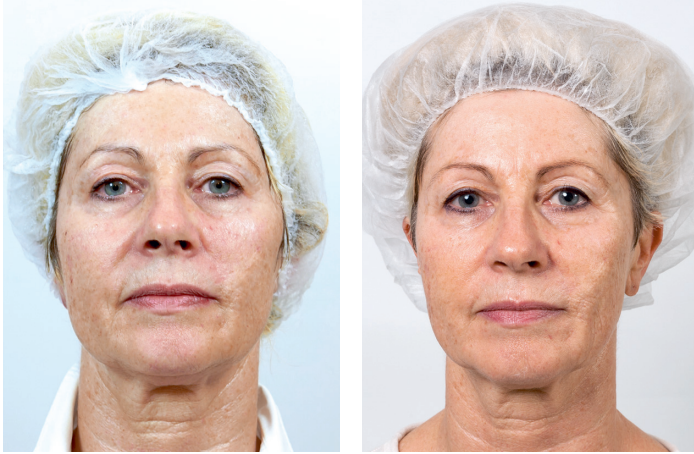Fig. 8.50 After the needling procedure, the PRP is applied to the whole nasolabial region and massaged in gently.

8.5.6 Information for the patient

Immediately after the treatment, the skin reddens, as it would if sunburnt, and may feel tight or sore. These phenomena disappear in the next few hours. A soothing cream can be applied. The effects of the treatment become apparent over the course of the next few weeks. It is essential to maintain consistent and high-level sun protection for at least two weeks after the treatment. Herpes prophylaxis is recommended for predisposed patients: 400 mg aciclovir after the treatment, followed by one 400-mg tablet 3 three times daily the next day.

8.5.7 Special advisory notes

Pronounced nasolabial folds can also be treated by direct injection (→ Fig. 8.55). Patients need to be informed that deeper nasolabial folds and sagging of the jawline are not going to disappear. It may be possible to augment nasolabial folds further with suitable fillers and to treat sagging with lipolysis or liposuction.



Patient 1, female, 59 years old

Problem:

Chronically photodamaged skin in the UV-exposed areas

Wishes:

Fresher appearance, fewer lines and wrinkles, increased firmness

Areas:

Face, neck, hands

Previous treatments:

Laser removal of seborrheic keratoses from the trunk, medical cosmetic treatments, 70% fruit acid peel on the face

PRP treatments:

3 on the face, 3 on the neck, 1 on the hands

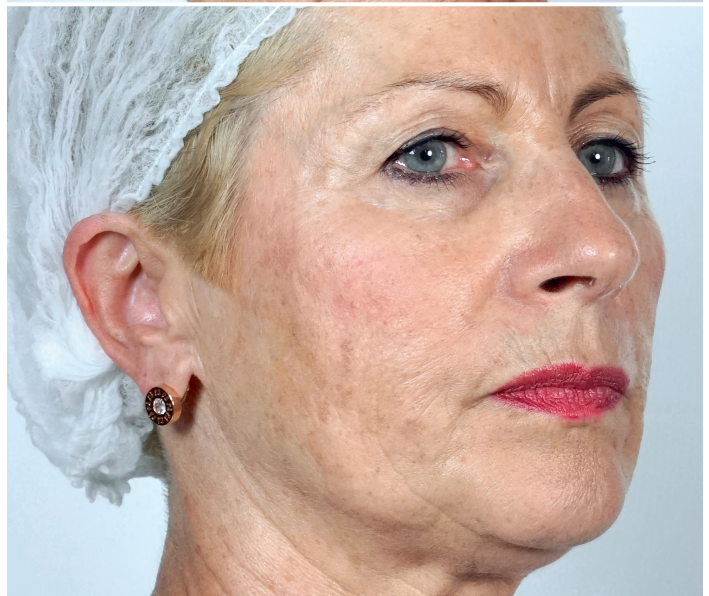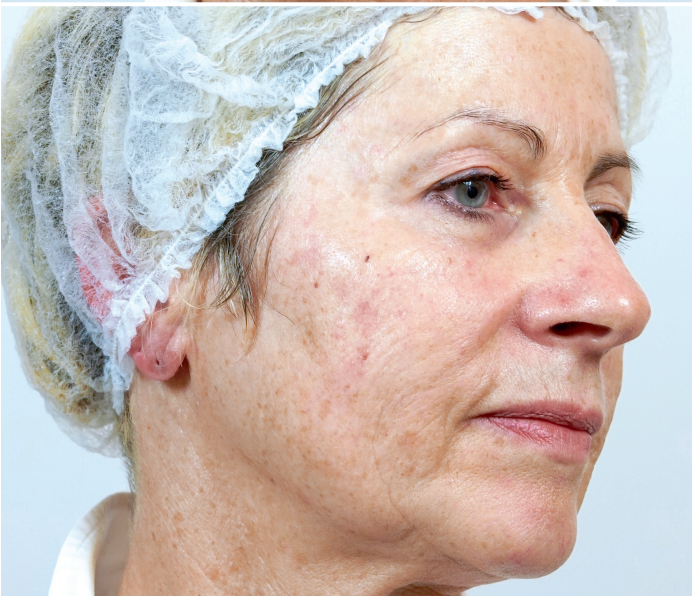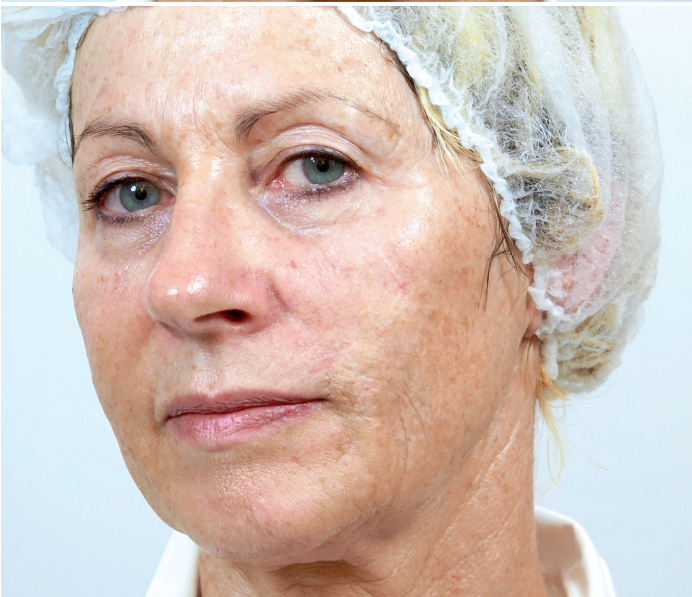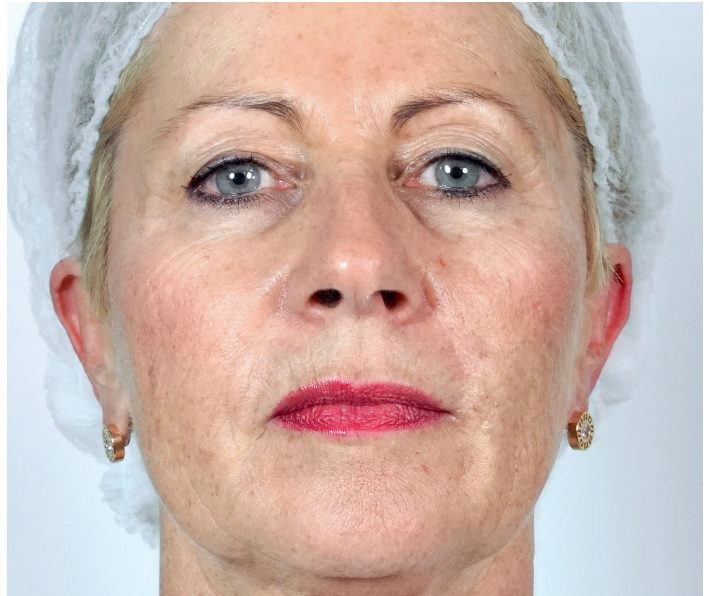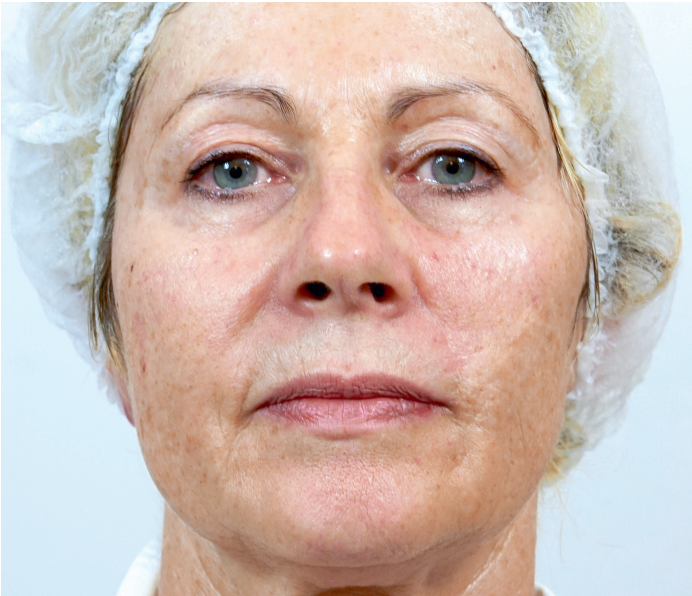- Mean pain level: 0 (VAS 0–10)
- No itching
- Mild reddening

Results:

Very good result achieved as regards fresher facial appearance, pigmentation greatly homogenized, significant reduction in lines and fine lines/wrinkles, textural improvement achieved in all treatment areas, moderate result as regards reduction of deep lines.

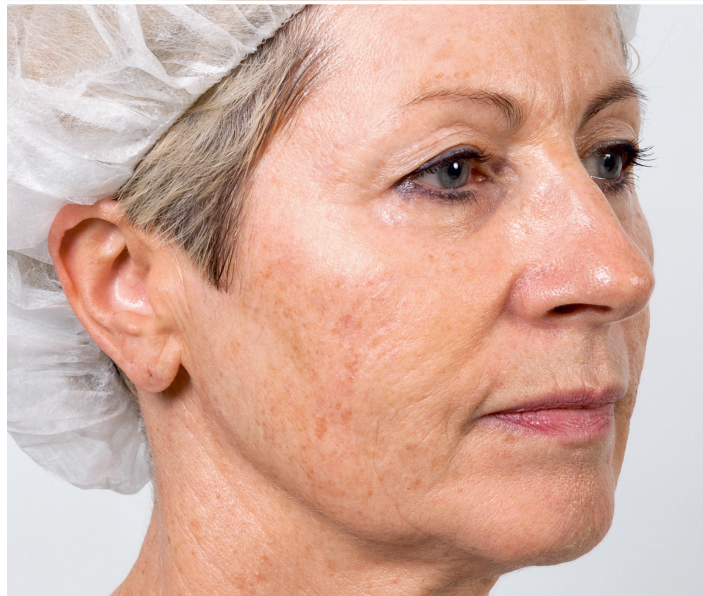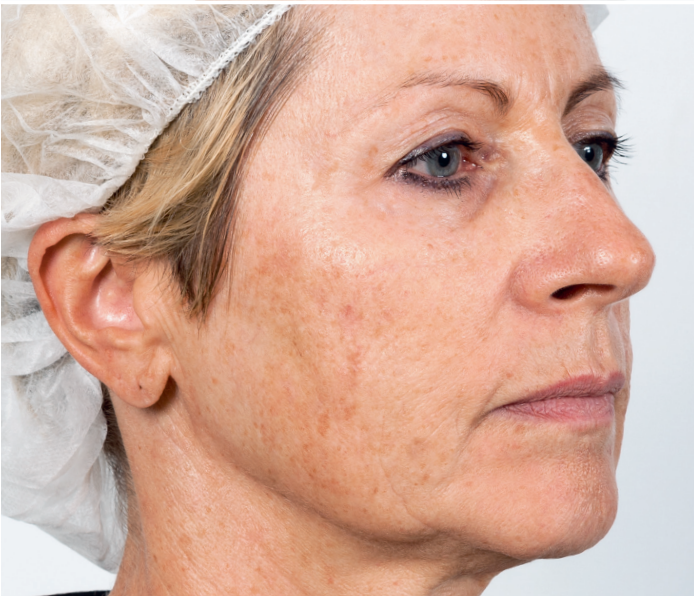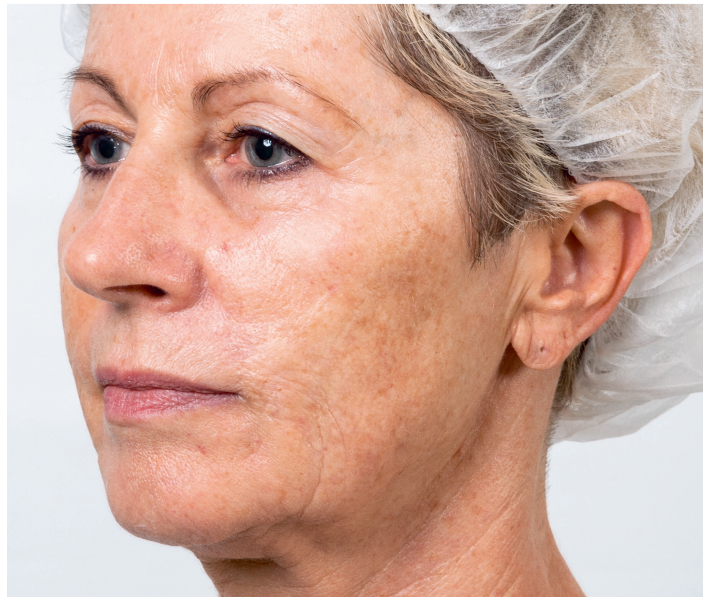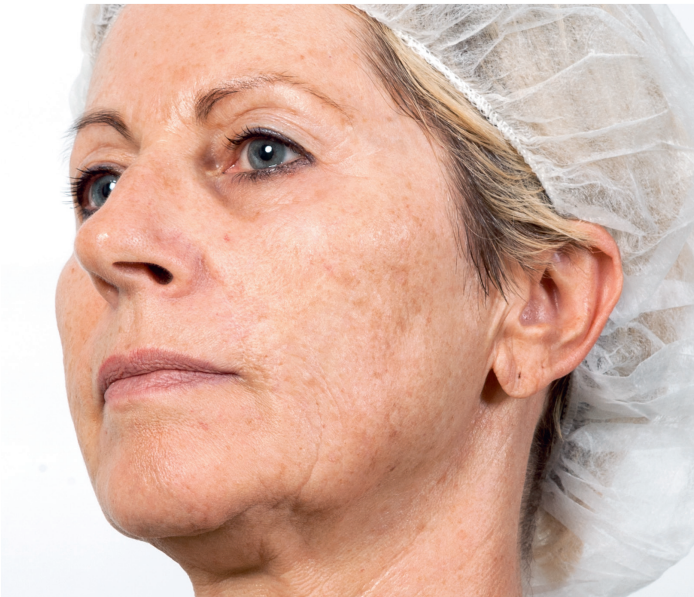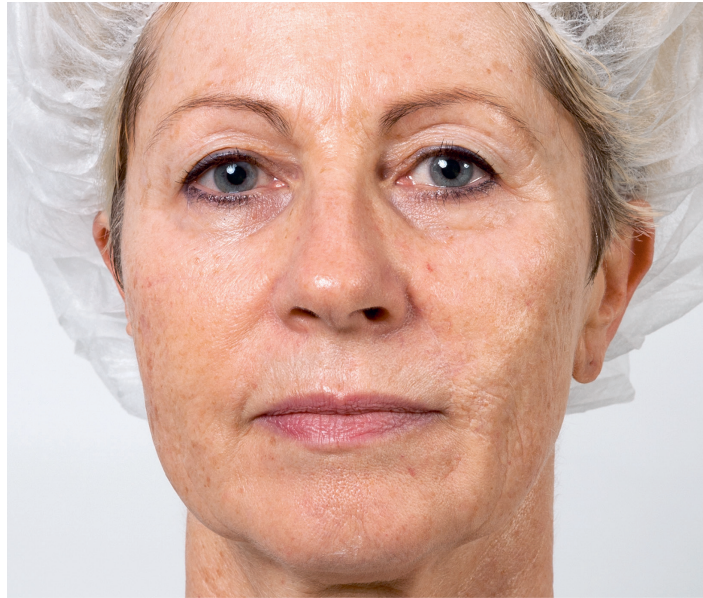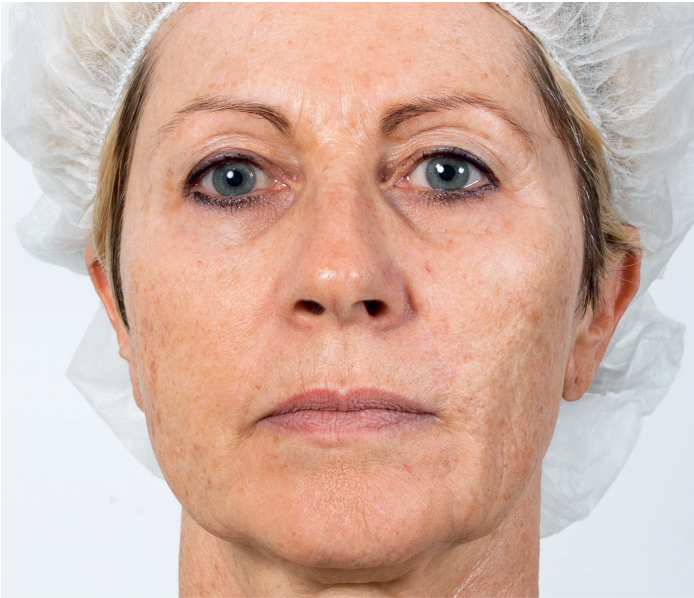Satisfaction level:

Largely satisfied



Before the 1st treatment

Four weeks after the 2nd treatment



9

Four weeks after the 3rd treatment

Check-up 3 months after the 3rd treatment