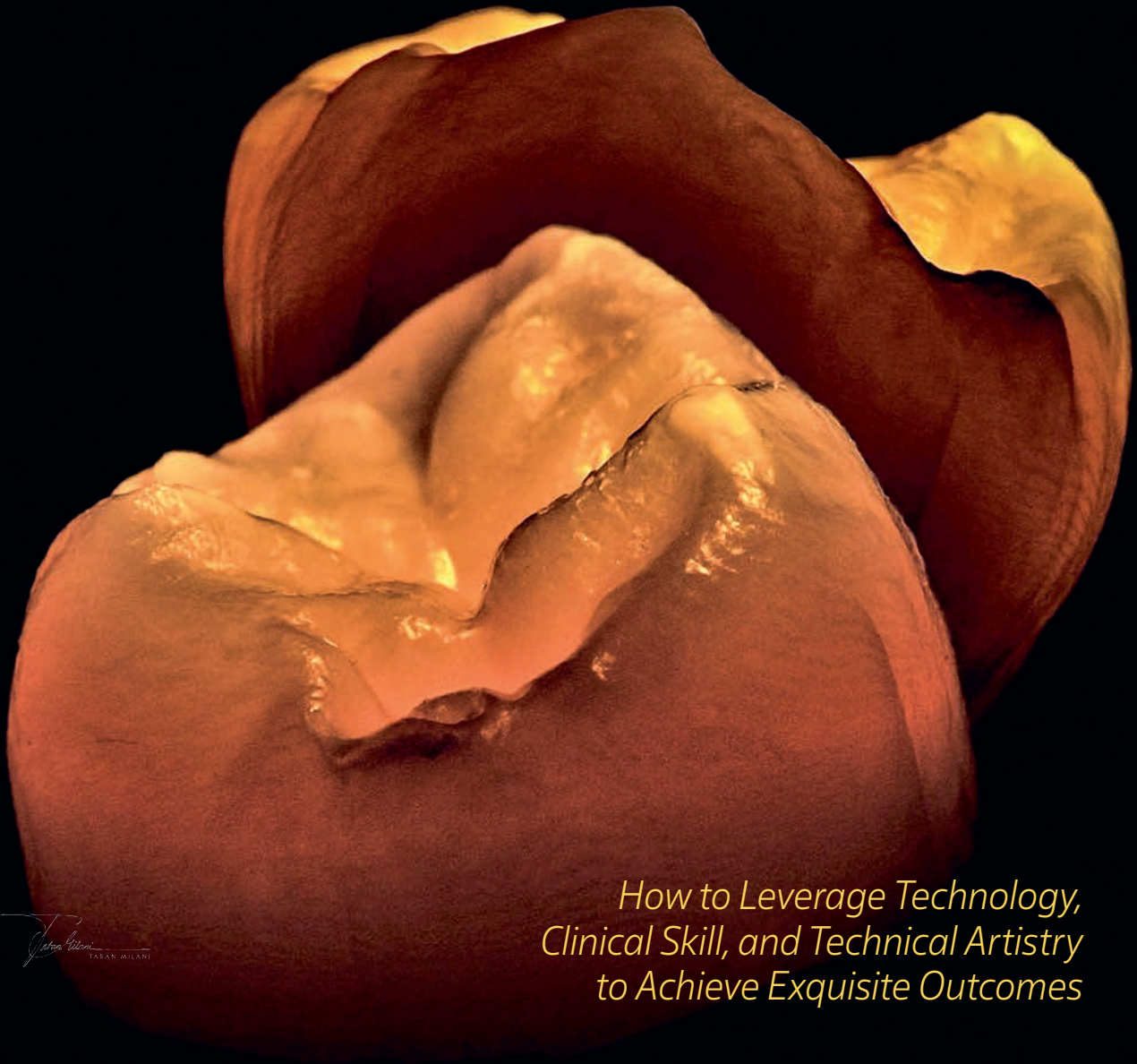


**QDT**

QUINTESSENCE OF DENTAL TECHNOLOGY

*MASTERING*  
**Interdisciplinary  
Treatment**

*Vincent Fehmer, MDT*  
*Editor-in-Chief*



*How to Leverage Technology,  
Clinical Skill, and Technical Artistry  
to Achieve Exquisite Outcomes*

Not for publication

# Expertise and Confidence:

IPS e.max® ZirCAD® Prime Esthetic



**Yuki Momma, RDT, Boston, MA**

"I make it IPS e.max ZirCAD Prime Esthetic because it provides an elegance which is unmatched by any other. It is a game changer zirconia!"

The ultimate zirconium oxide  
with GT Technology.

ivoclar.com  
Making People Smile

ivoclar





One book, one tree: In support of reforestation worldwide and to address the climate crisis, for every book sold Quintessence Publishing will plant a tree (<https://onetreeplanted.org/>).

**Library of Congress Control Number: 2024947471**

A CIP record for this book is available from the British Library.

ISSN: 1060-1341 / ISBN: 978-1-64724-201-5

## **PUBLISHER**

Christian W. Haase

## **PUBLISHER EMERITUS**

H. W. Haase

## **EDITORIAL DIRECTOR**

Leah Huffman

## **DESIGN/PRODUCTION**

Angelina Schmelter

## **MANUSCRIPT SUBMISSION**

QDT publishes original articles covering dental laboratory techniques and methods.

For QDT submission information, contact the publisher ([service@quintbook.com](mailto:service@quintbook.com)).

Copyright © 2025 by Quintessence Publishing Co, Inc. All rights reserved. No part of this publication may be reproduced or transmitted in any form or by any means, electronic or mechanical, including photocopying, recording, or any information and retrieval system, without permission in writing from the publisher. The publisher assumes no responsibility for unsolicited manuscripts. All opinions are those of the authors.

Permission to photocopy items solely for internal or personal use and for the internal or personal use of specific clients is granted by Quintessence Publishing Co, Inc, for libraries and other users registered with the Copyright Clearance Center (CCC) provided the appropriate fee is paid directly to CCC ([www.copyright.com](http://www.copyright.com)).



© 2025 Quintessence Publishing Co, Inc

Quintessence Publishing Co, Inc

411 N Raddant Road

Batavia, IL 60510

[www.quintessence-publishing.com](http://www.quintessence-publishing.com)

5 4 3 2 1

ISSN: 1060-1341

Printed in Croatia

*Cover and title page photos courtesy of Taban Milani, DDS, winner of our QDT 2025 cover contest.*

**QDT**

QUINTESSENCE OF DENTAL TECHNOLOGY

*MASTERING*

# Interdisciplinary Treatment

*How to Leverage Technology,  
Clinical Skill, and Technical Artistry  
to Achieve Exquisite Outcomes*

*Editor-in-Chief*

**Vincent Fehmer, MDT**

Dental Laboratory  
Dental Clinic of the University of Geneva  
Geneva, Switzerland

*Vincent Fehmer*  
VINCENT FEHMER

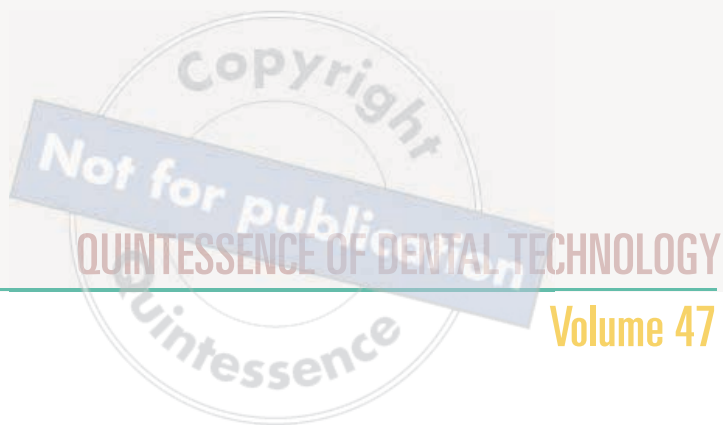 **QUINTESSENCE PUBLISHING**

Berlin | Chicago | Tokyo  
Barcelona | London | Milan | Paris | Prague | Seoul | Warsaw  
Beijing | Istanbul | Sao Paulo | Sydney | Zagreb

# QDT

## 2025

<b>Editorial: <i>Embracing Innovation for the Future of Dental Care</i></b>	<b>vi</b>
Vincent Fehmer	
<b>Segmented Monolithic Zirconia Titanium-Supported Double Full-Arch FP1 Prostheses: <i>A Novel Approach</i></b>	<b>2</b>
Stavros Pelekanos, Emil Bobev, Vassiliki Rizou, Tanya Spyropoulou, and Panagiotis Ntovas	
<b>Treating Terminal Dentition with FP1 Prostheses: <i>A Digital Perioprosthodontic Approach</i></b>	<b>23</b>
Ramon Gomez Meda and Jonathan Esquivel	
<b>Full-Arch Implants: <i>FP1—A Digital Reinterpretation</i></b>	<b>40</b>
Venceslav Stankov, Florin Cofar, David Norré, Adrian Argint, Alexander De Greef, Ioana Popp, Alexander Nikolov, Wael Att, and Eric Van Dooren	
<b>Achieving the FP1 Restoration via Prosthodontically Guided Tissue Sculpting</b>	<b>68</b>
Naif Sinada and Christina I. Wang	
<b>Reference Denture Technique: <i>A Paradigm Shift in Contemporary Prosthodontic Rehabilitation</i></b>	<b>86</b>
Eric D. Kukucka and Nelson R.F.A. Silva	
<b>Predictable Digital Workflows in Reconstructive Dentistry</b>	<b>113</b>
Juan Legaz	
<b>Porcelain Laminate Veneers in 2025: <i>Combining Technology with Evidence-Based Clinical and Laboratory Workflows</i></b>	<b>130</b>
Julian Conejo, Sergio Losas, Telmo Santos, and Markus B. Blatz	
<b>Ultrathin Ceramic Veneers to Restore Adjacent Teeth and Implants</b>	<b>146</b>
Oscar Gonzalez-Martin, Javier Pérez, and Gustavo Avila-Ortiz	



## Volume 47

- Laminate Veneers: Preserving the Essence of Natural Teeth** 160  
Naoki Hayashi
- Noninvasive and Straightforward Treatment of Localized Tooth Wear with Hybrid Ceramic (PICN):  
*The Orthodontic-Assisted One-Step No-Prep Technique*** 170  
Amélie Mainjot
- Contrast and Filter Techniques in Ceramic Layering for Natural-Looking Anterior Crowns** 186  
Hans Joit
- Anterior Cantilever Bridge with Zirconia Infrastructure Coupled with a Pressed Glass-Ceramic Coating:  
*Clinical and Laboratory Implementation*** 202  
Romain Ceinos, Jean Richelme, Flore Moradei, and Fabio Levratto
- Shade-Matching Technique for Full-Contour Zirconia Crowns** 217  
Hiro Tokutomi, Kimiyo Sawyer, Julian Conejo, and Markus B. Blatz
- Low-Viscosity Resin Infiltration for Enamel White Spots** 230  
Meiken Hayashi
- A Digital Leap in Ortho-Restorative Dentistry:  
*Case Report on a Unified Approach to Minimally Invasive Restorations and Orthodontic Treatment*** 244  
Andrea Patrizi and Alexis Ioannidis
- How to Manage the Single Central Incisor** 259  
Yuki Momma





# Editorial:

## Embracing Innovation for the Future of Dental Care

As we navigate an era defined by rapid technologic advancements, the dental community stands at a transformative moment. With the *Quintessence of Dental Technology* (QDT), our mission has always been to bridge the gap between innovative practices and real-world applications in dentistry. In this edition, we reflect on the transformative power of technology in our field and the profound implications for patient care, education, and professional growth.

The last few years have seen remarkable progress in dental technology, from the integration of digital dentistry to the rise of telehealth solutions. These advancements not only en-



hance our diagnostic and treatment capabilities but also elevate the patient experience, making care more efficient and accessible. As we embrace these tools, we must also recognize the responsibility that comes with them. Continuous education and adaptation are essential, ensuring that we leverage these technologies effectively and ethically.

Collaboration within our community has never been more crucial. The sharing of knowledge and experiences among dental professionals encourages an environment of growth and innovation. Through our publications, we aim to create a platform where ideas can flourish and where practitioners can stay informed about the latest research, techniques, and materials. Your contributions are invaluable in this ongoing dialogue, and we encourage you to share your insights and experiences with us.

Moreover, as we look ahead, it's vital to consider the holistic impact of our technologic advancements. How do they influence patient outcomes, and how can we use these tools to promote preventive care? The future of dentistry is not just about adopting new technologies; it's about enhancing the relationship between patient and provider.

As we present the latest research and insights in this issue, I invite you to reflect on how you can integrate these advancements into your practice. Let us embrace the challenges and opportunities that lie ahead with open minds and a commitment to excellence.

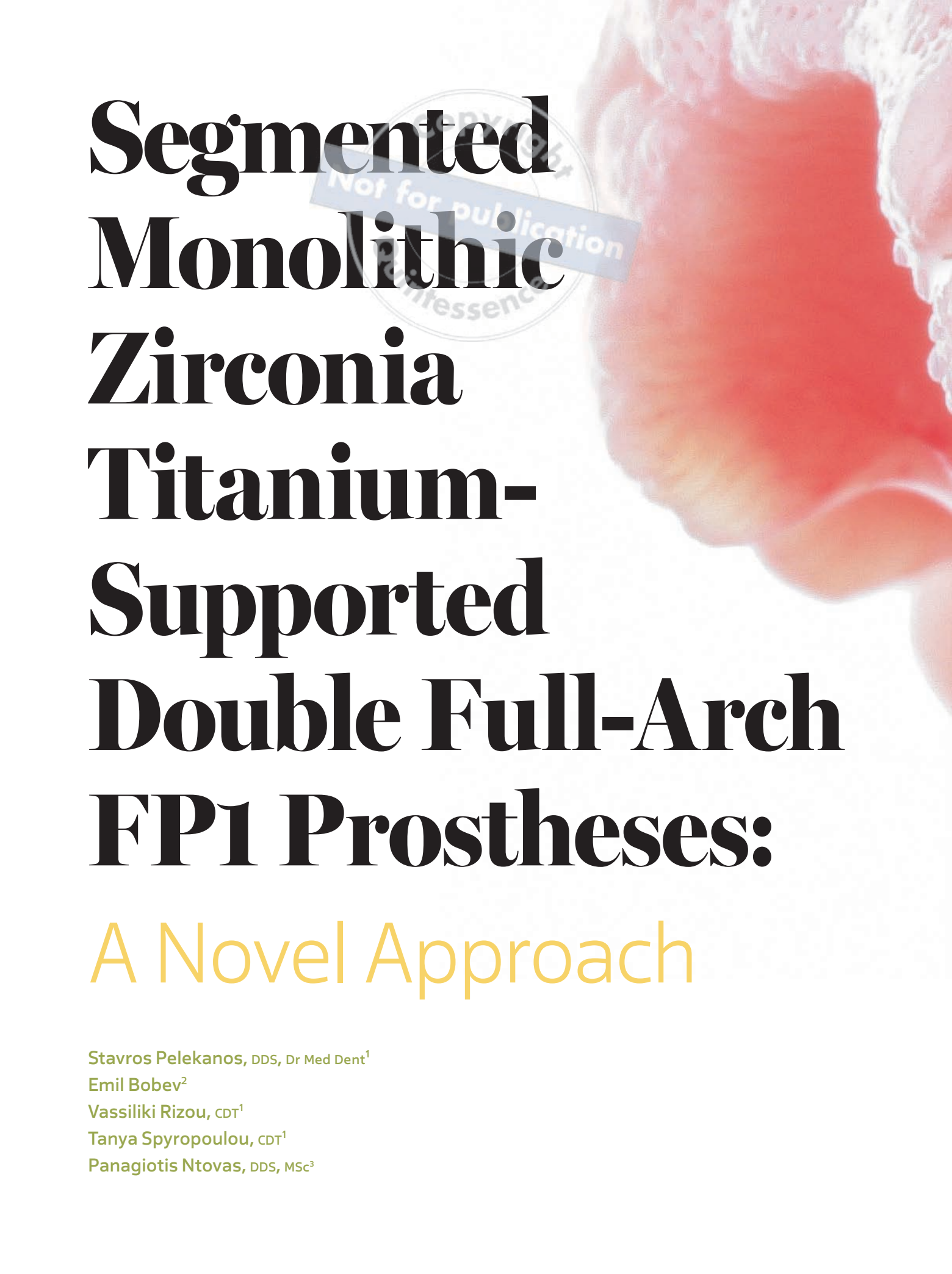
Thank you for your continued support of QDT. Together we can shape the future of dental technology and ultimately improve the lives of our patients.

Warm regards,

Vincent Felner

*Image courtesy of Luis Quintero, CDT, runner-up in our QDT 2025 cover contest.*





# **Segmented Monolithic Zirconia Titanium- Supported Double Full-Arch FP1 Prostheses:**

## **A Novel Approach**

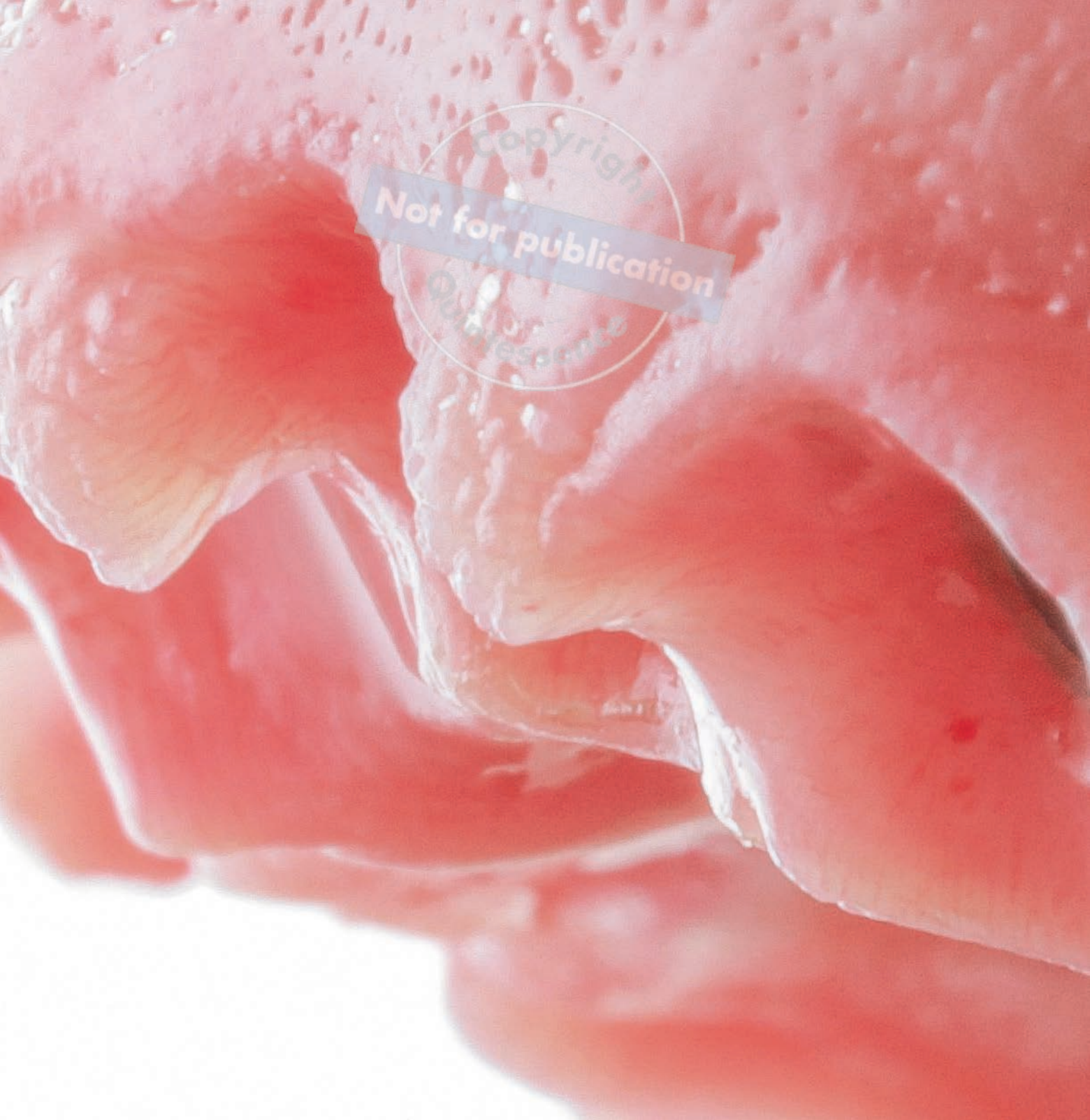Stavros Pelekanos, DDS, Dr Med Dent<sup>1</sup>

Emil Bobev<sup>2</sup>

Vassiliki Rizou, CDT<sup>1</sup>

Tanya Spyropoulou, CDT<sup>1</sup>

Panagiotis Ntovas, DDS, MSc<sup>3</sup>



**T**oday implant-supported full-arch rehabilitations are a common treatment option for patients with edentulism or failing dentition.<sup>1</sup> This article describes material selection and the use of digital technology for the rehabilitation of a patient with terminal dentition compromised by dental caries and periodontal disease.

<sup>1</sup>Private practice, Athens, Greece.

<sup>2</sup>Guided surgery specialist, Berlin, Germany.

<sup>3</sup>Scientific affiliate, Tufts University School of Dental Medicine, Boston, Massachusetts, USA.

**Correspondence to:** Panagiotis Ntovas, pan.ntovas@gmail.com



## Patient Presentation

A 59-year-old man presented to the clinic with the chief complaints of an unsatisfactory smile appearance, limited masticatory function, halitosis, and pain while chewing (Figs 1 to 3). The patient was in good general health with a noncontributory medical history except for smoking five cigarettes per day. Clinical and radiographic examination (Figs 4 and 5) revealed rampant caries, nonrestorable teeth, soft tissue inflamma-

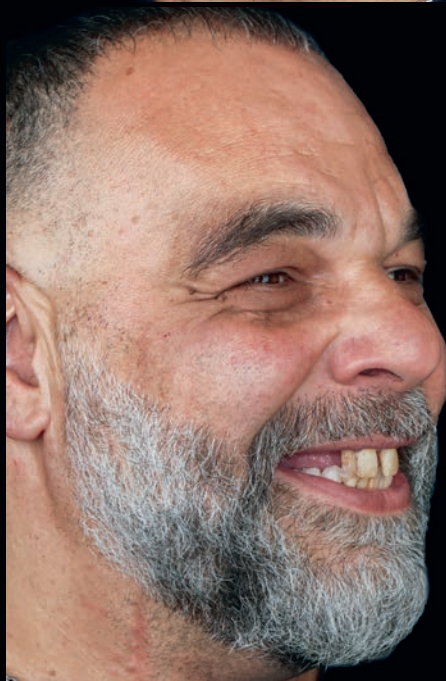tion, tooth mobility, residual roots, and missing teeth. The patient was diagnosed with generalized periodontitis (Stage IV, Grade B).<sup>2</sup>

## Etiology and Diagnosis

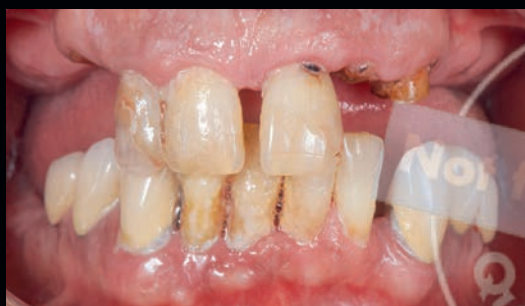*Terminal dentition* refers to dentition that is compromised to the extent that either the teeth cannot be restored or they present with inadequate periodontal



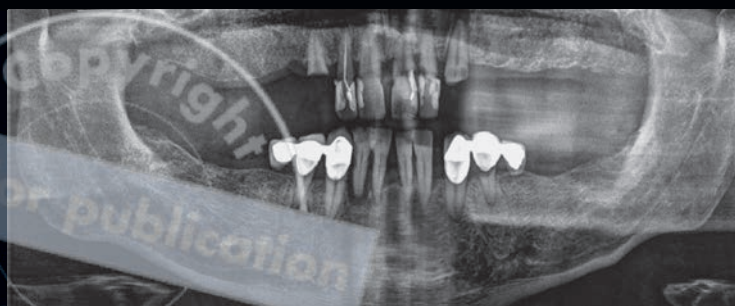
**FIGS 1 TO 3**  
Preoperative clinical views of the patient smiling.







**FIG 4** Preoperative intraoral view in occlusion.



**FIG 5** Preoperative panoramic radiograph.

support.<sup>3</sup> Determining the parameters that can lead to the diagnosis of a terminal dentition can be challenging due to the multifactorial nature of compromised dentitions. For a successful treatment plan, the clinician must be able to avoid both under- and overtreatment and decide whether teeth with a favorable prognosis can be selectively maintained.

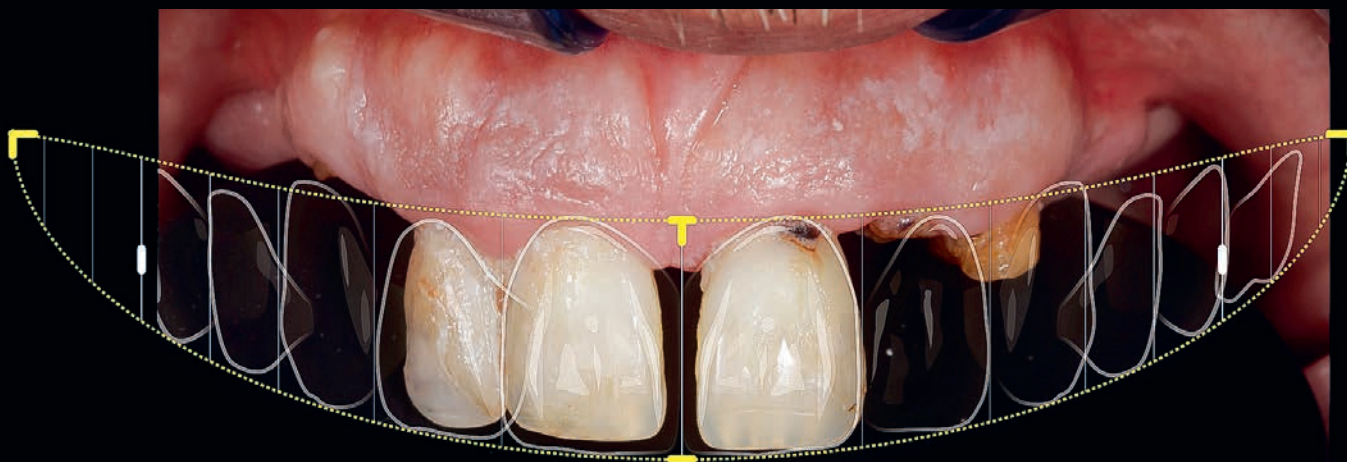
## Treatment Plan

In patients with a compromised dentition, the remaining dentition must be evaluated quantitatively and qualitatively. Structural damage to the dentition, periodontal damage, the number and distribution of the remaining teeth, and dentogingival and dentofacial esthetics are among the major variables that must be assessed individually.<sup>3</sup> In addition to the remaining dentition, the patient's level of compliance, financial capabilities, expectations, and wishes must be considered.

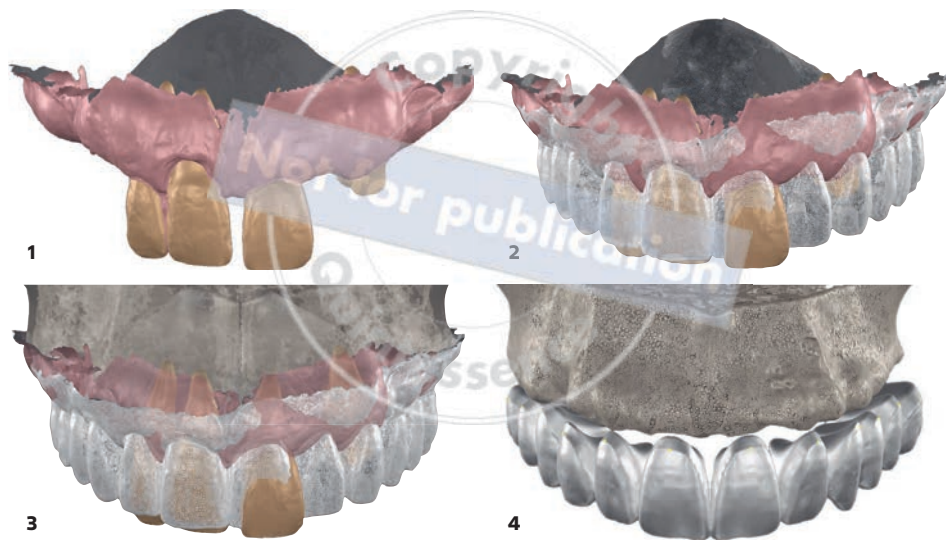
Understanding the etiologic factors that resulted in terminal dentition or edentulism is crucial, as this will affect the treatment plan, restoration design, material selection, and prognosis. It is especially important to consider the higher risk of patients with a history of periodontitis for developing peri-implant disease.<sup>4</sup>

## Esthetic Evaluation

Treatment planning for full-arch implant-supported restorations can be an arduous process.<sup>5,6</sup> As a starting point, the desired smile esthetics must be determined<sup>7</sup> (Fig 6). Today digital smile design can be performed in harmony with a patient's dentofacial esthetics using artificial intelligence-based software (Smilecloud, Straumann).<sup>8</sup> In this case, esthetic analysis was performed by evaluating the smile line, incisal profile, tooth length, individual tooth proportion, tooth-to-tooth proportion, gingival contours, and fullness of the buccal corridors.<sup>6-10</sup>



**FIG 6**  
Digital smile design.

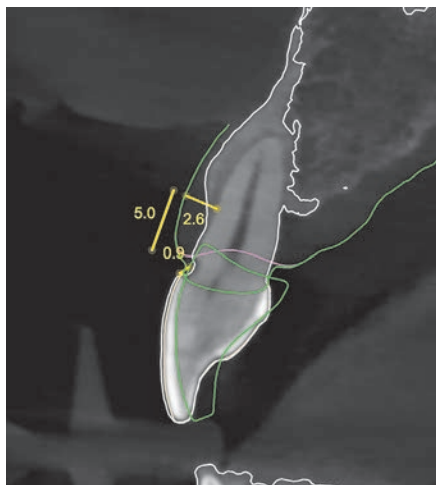


**FIG 7** Virtual design of the FP1 prostheses. (1) Preoperative situation. (2) Preoperative situation and singular design. (3) Preoperative situation and singular design with bone segmentation. (4) Singular design with bone segmentation.

## Virtual Design

First, a 2D digital smile design was created to evaluate smile esthetics (Smilecloud). Subsequently, in the same software a 3D virtual smile design was created to generate a singular design by adding and superimposing the files obtained from the intraoral scan and the files from the CBCT. Figure 7 demonstrates the data sets of the 3D virtual design: initial situation, preoperative situation and singular design, preoperative situation and singular design with bone segmentation, and singular design with bone segmentation. The final data set was used for the virtual implant planning.

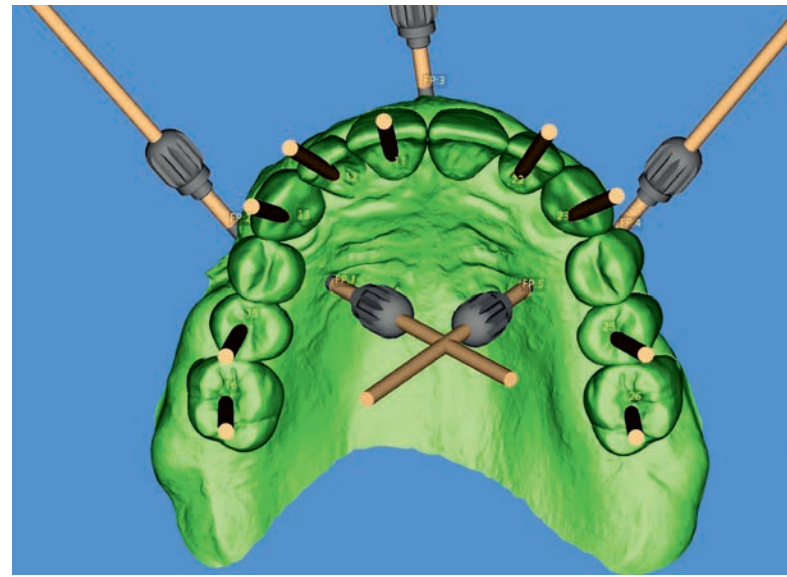
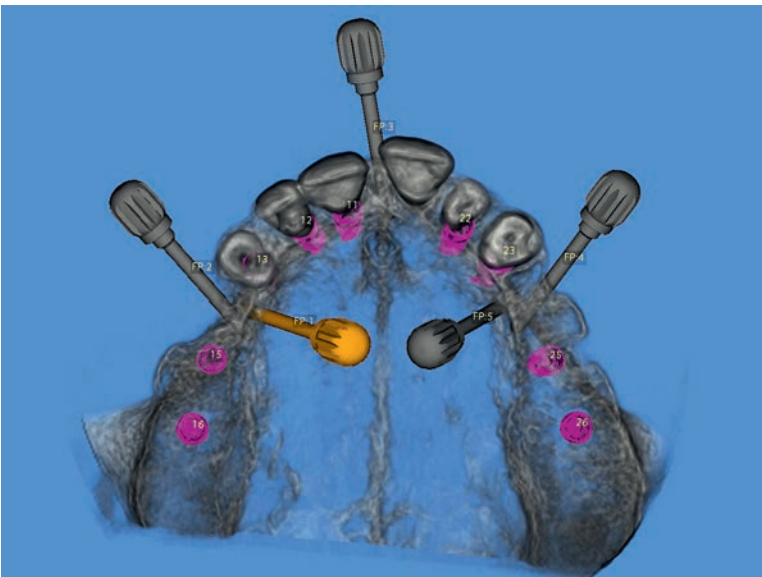
Soft and hard tissue dimensional changes after tooth extraction must be considered during the virtual design process.<sup>11,12</sup> In the authors' experience, when the combined thickness of the bone and the soft tissue is more than 2.5 mm at a level measured 5 mm deeper than the clinical crown of the virtual design, the vertical reduction of the soft tissue contour is less than 1 mm (Fig 8). In the present case, because the bone and soft tissue was 2.6 mm thick, the clinical crown of the virtual design was placed approximately 1 mm coronal to the gingival margin.



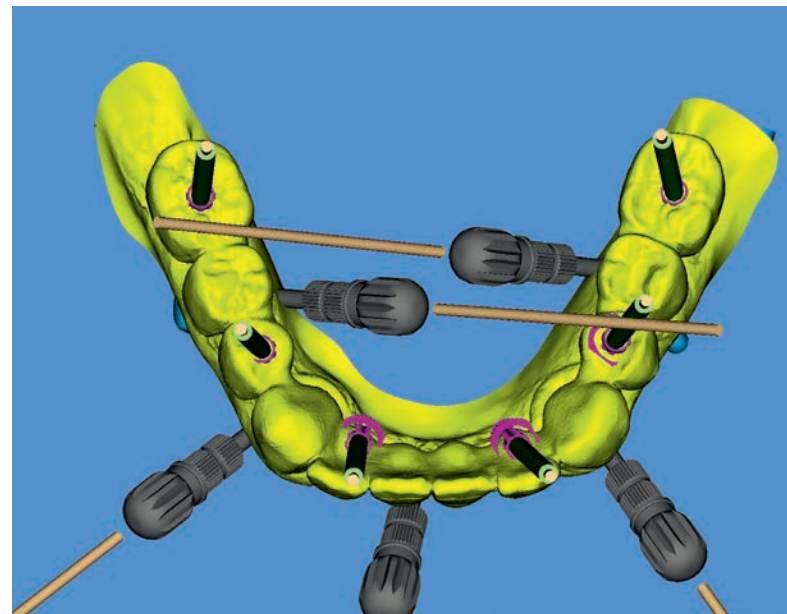
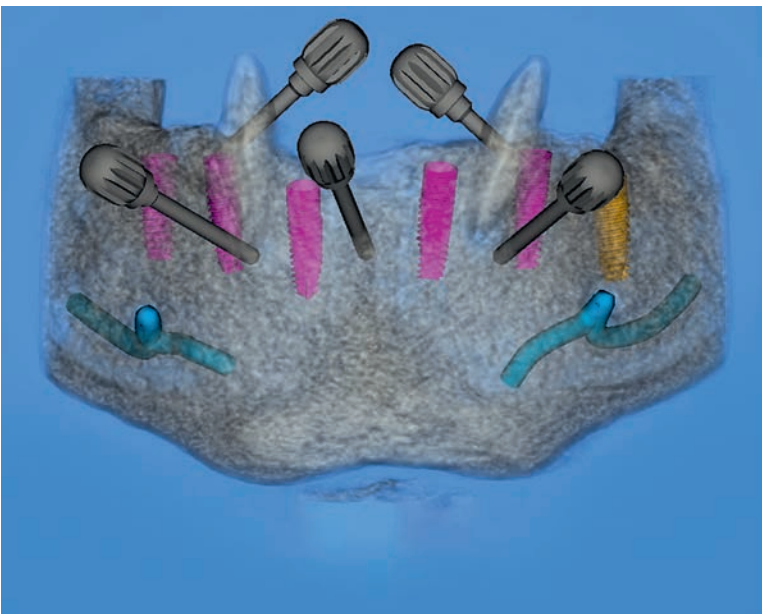
**FIG 8** Analysis showing the measurements performed for the initial design.

## Virtual Implant Planning

An implant planning software (MGuide, MIS Dental Implants) was used to register the CBCT with the virtual models that were obtained from the intraoral scan to facilitate the prosthetically driven planning of eight implants (V3, MIS Dental Implants) in the maxilla (Figs 9 and 10) and six implants in the mandible<sup>13</sup> (Figs 11 and 12).



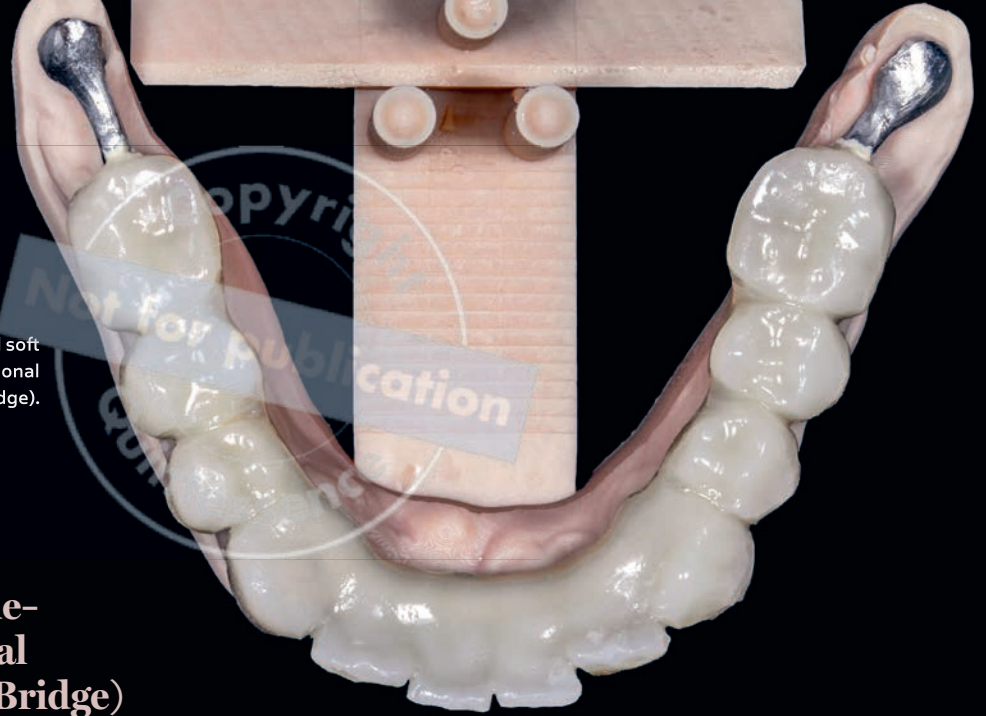**FIGS 9 AND 10** Virtual implant planning for the maxilla.



**FIGS 11 AND 12** Virtual implant planning for the mandible.

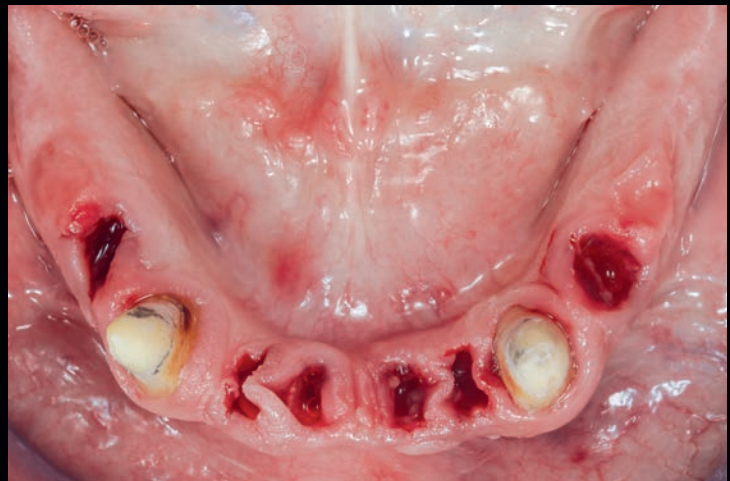

**FIG 13** Tooth- and soft tissue-supported provisional restoration (tripod bridge).



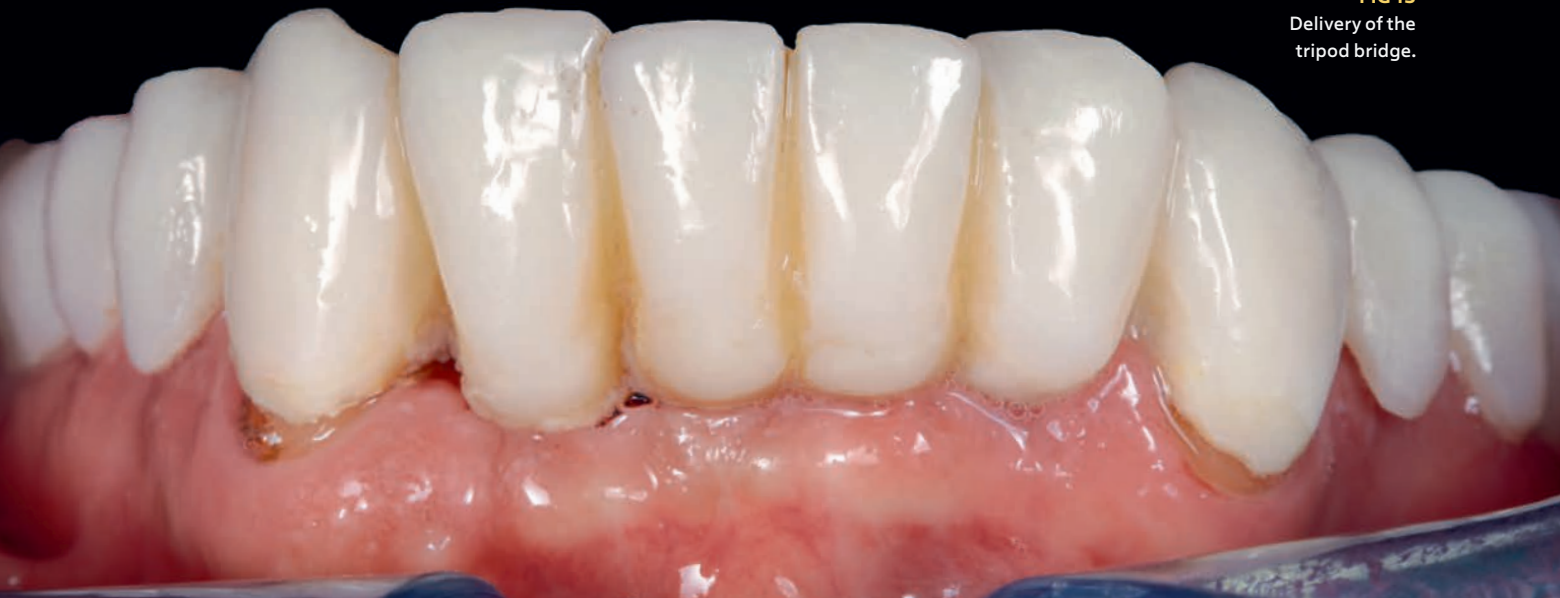## Tooth- and Soft Tissue-Supported Provisional Restoration (Tripod Bridge)

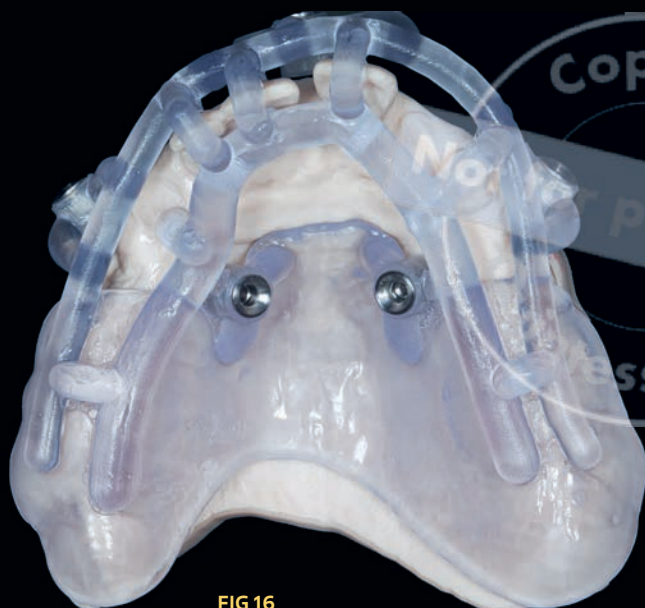
In the mandible, a staged approach was followed to enable a smooth transition in the new centric relation. A tooth- and soft tissue-supported restoration (tripod bridge) was fabricated by bonding a sintered cobalt-chromium (Co-Cr) substructure with a milled polymethyl methacrylate (PMMA) overlay<sup>14</sup> (Fig 13). Teeth with a hopeless prognosis were extracted, except for the canines (Fig 14). The canines were strategically preserved to support a fixed provisional restoration (Fig 15). A tripod bridge is a valuable option for provisional restorations in patients with posterior partial edentulism. Support is provided by the remaining teeth and either the maxillary tuberosities or the mandibular retromolar pads.



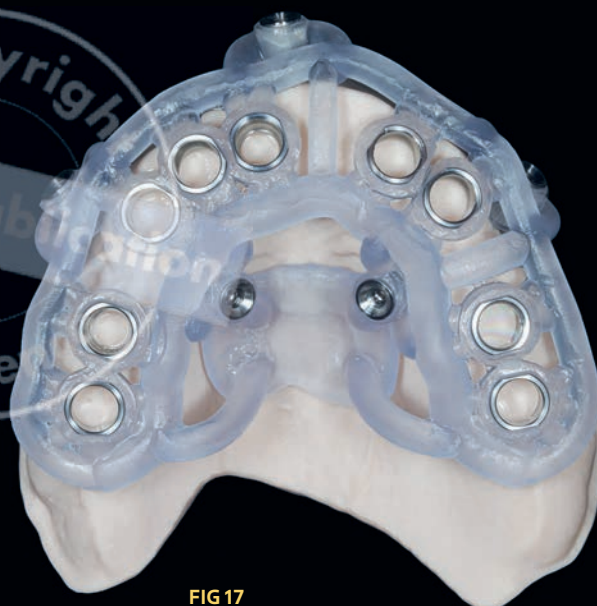
**FIG 14** Occlusal view of the mandible after extraction of the hopeless teeth, leaving the canines in place to support a provisional restoration.

**FIG 15**  
Delivery of the tripod bridge.





**FIG 16**  
Surgical guide for  
anchor pin drilling  
in the maxilla.

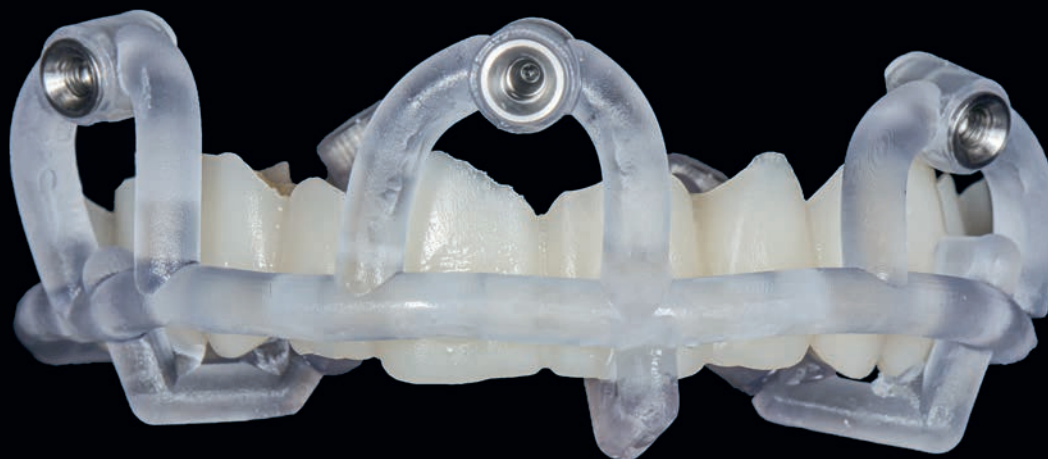

**FIG 17**  
Surgical guide for  
implant placement  
in the maxilla.

## Fabrication of Surgical Guides

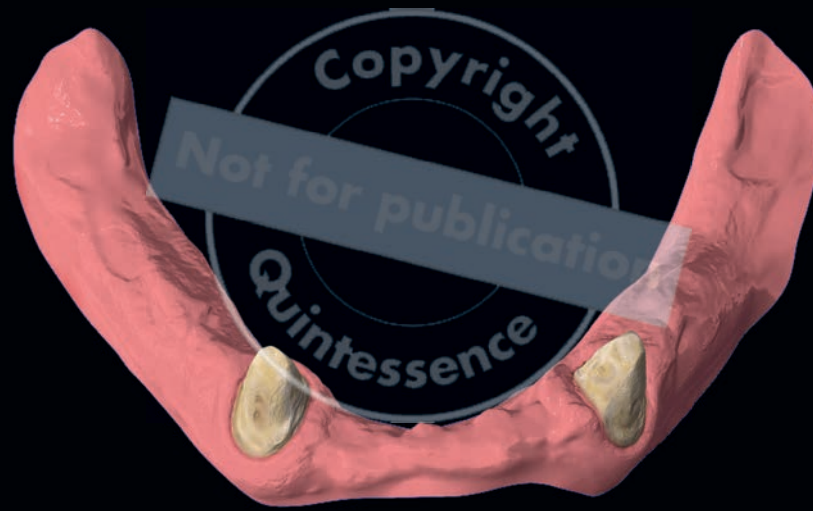The information from the virtual implant planning was used to design a set of surgical guides for the maxilla and mandible. The goal was to transfer the virtual implant positions to the respective recipient sites through fully guided surgery. The STAR concept was followed to take advantage of the remaining teeth.<sup>15</sup> In this way, strategically remaining teeth or roots can be used to increase the accuracy of static computer-aided implant placement. Surgical guides were 3D printed (Max, Asiga) using a bio-compatible resin (KeyGuide, Keystone Industries).

For the maxilla, a guide for the insertion of the fixation pins, a guide for implant placement, and a guide for positioning the prefabricated prosthesis were printed (Figs 16 to 18). For the mandible, a stackable system was used, including a base guide, a positioning guide for the insertion of the anchorage pins and implant placement, and a guide for positioning the prefabricated provisional prosthesis according to the initial virtual design (Fig 19).

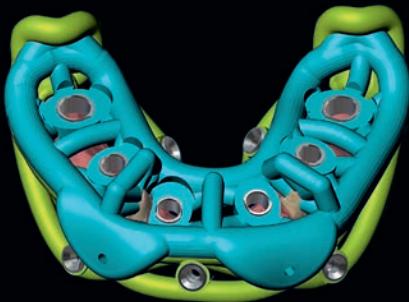


**FIG 18** Surgical guide for positioning the maxillary prosthesis.

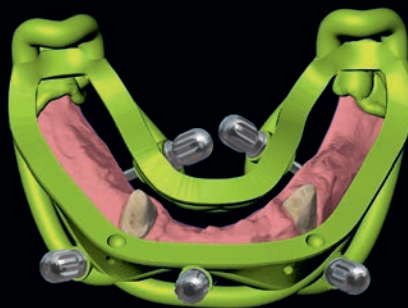




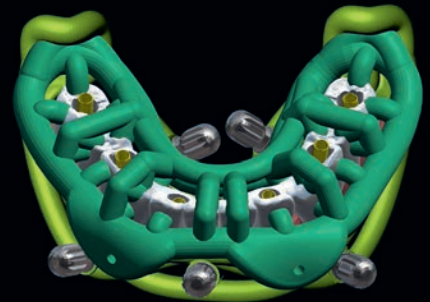
1



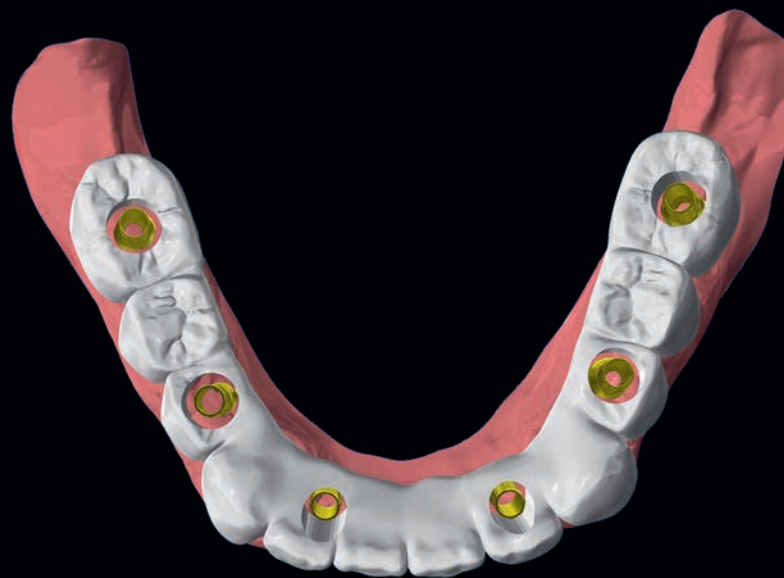2



3



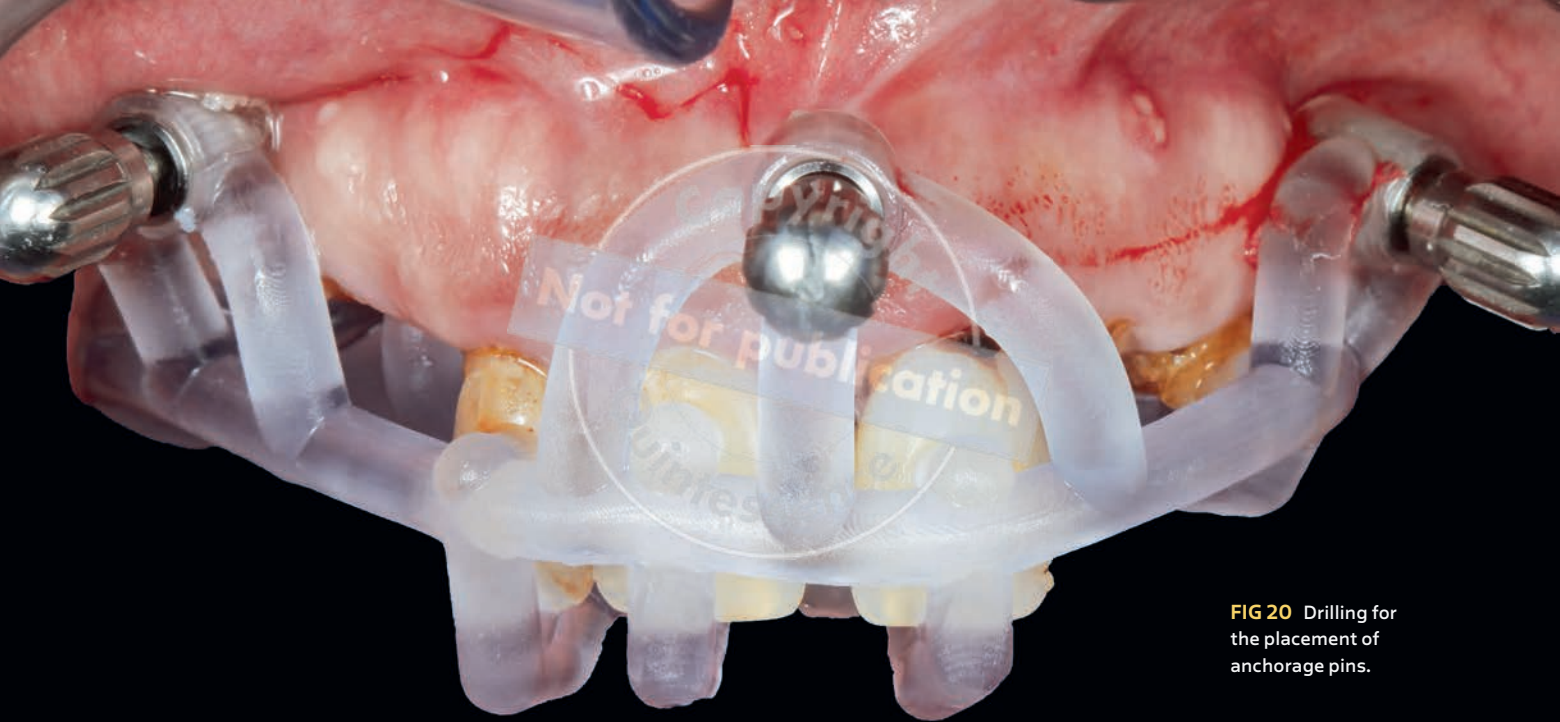
4



5

**FIG 19** Set of stackable surgical guides for the mandible. (1) Initial situation. (2) Base guide (light green) connected with the guide for anchorage pin drilling and implant placement (blue). (3) Base guide. (4) Prosthetic guide (dark green) along with the provisional restoration connected with the base guide. (5) Provisional restoration.





**FIG 20** Drilling for the placement of anchorage pins.

## Implant-Supported Provisional Restorations

Full-arch provisional prostheses were selected to achieve implant splinting for immediate loading. Prior to initiation of the implant surgery, PMMA (Telio CAD LT in shade A1, Ivoclar) FP1 provisional prostheses were milled and stained based on the virtual design. Customized prosthetic channels were incorporated into the prefabricated prostheses to house the temporary cylinders and facilitate chairside relining. For each provisional restoration, the transmucosal part was digitally formed, considering the 3D virtual design in relation to soft tissue architecture and bone anatomy with the goal of facilitating development of a scalloped interface.<sup>16</sup>

## Surgical Phase

Tooth extraction was performed followed by guided implant placement. Extraction sockets in implant sites were filled with a mixture of mineralized bone allograft (maxgraft, bottis biomaterials) and deproteinized bovine bone mineral (cerabone, botiss biomaterials) particles, at a ratio of 70:30. In pontic sites, extraction sockets were filled with a collagen

cone (collacone, bottis biomaterials) with the goal of maintaining the volume of the extraction socket.

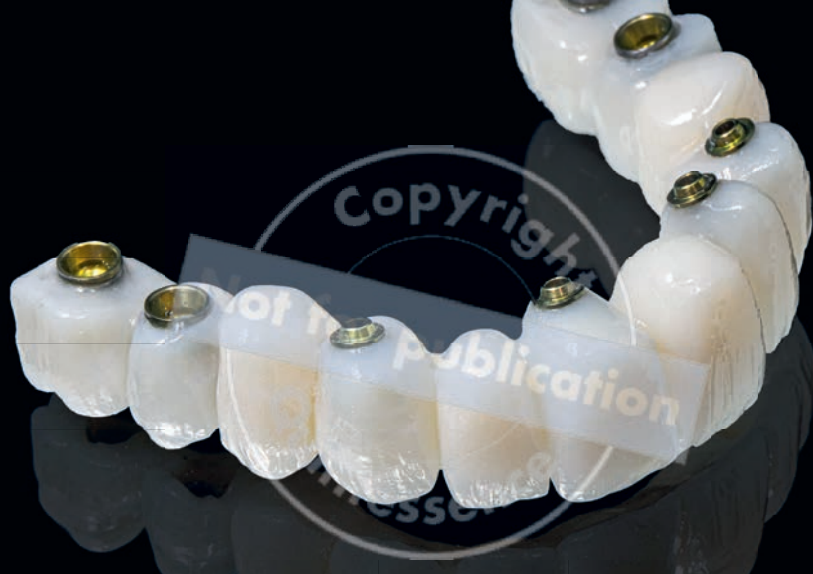## Implant Placement

Implants were placed according to the virtual treatment plan. A fully guided surgical protocol was followed to increase the accuracy between the planned and final positions of the implants and decrease operative time.<sup>17</sup>

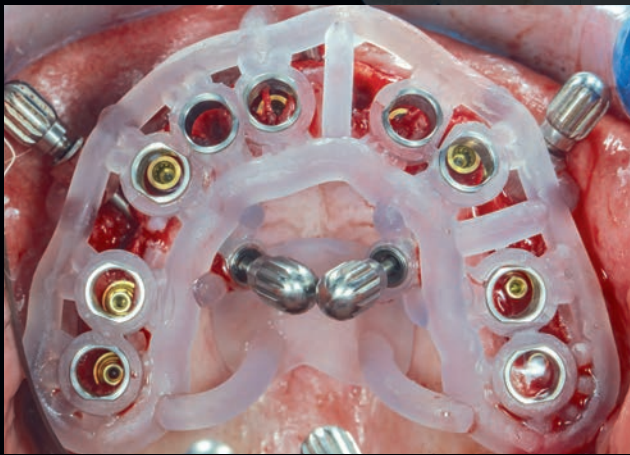
In the maxilla, the first surgical guide (positioning guide) was fitted over the remaining teeth to prepare the recipient sites for insertion of the anchorage screws (Fig 20). The implant guide was then secured with fixation pins and used for implant drilling and placement (Figs 21 to 23).

For the mandible, one surgical guide was fabricated to aid fixation of the guide as well as implant drilling and placement. This was connected with a base guide and fitted over the strategically remaining teeth to prepare the recipient sites for the insertion of the anchorage screws and to fix the base guide in place (Fig 24).

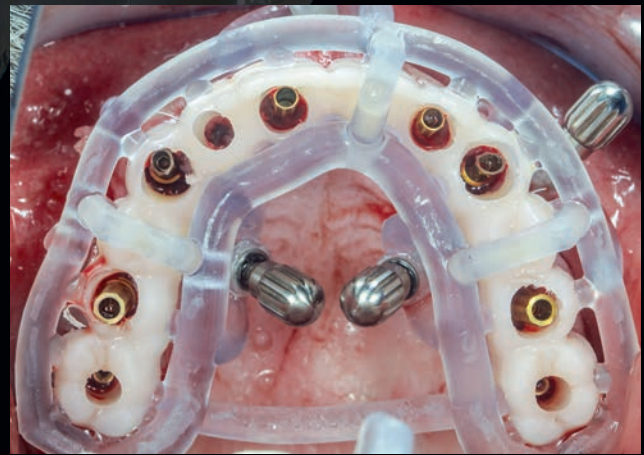
For each implant, a surgical primary stability of  $\geq 35$  Ncm was achieved. After the removal of the last surgical guide, multiunit abutments were seated on the implants with a torque of 30 Ncm.



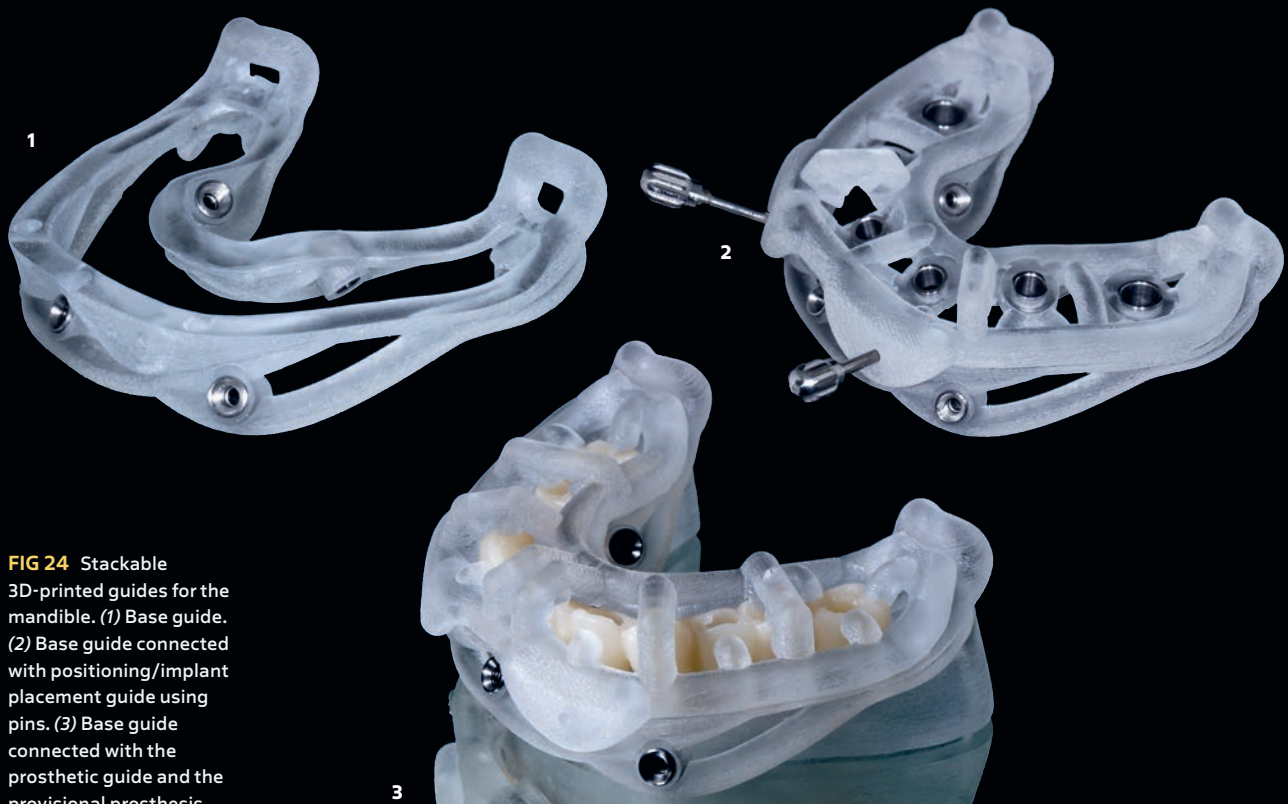**FIG 21**  
Provisional prosthesis.



**FIG 22** Implant placement through the surgical guide.

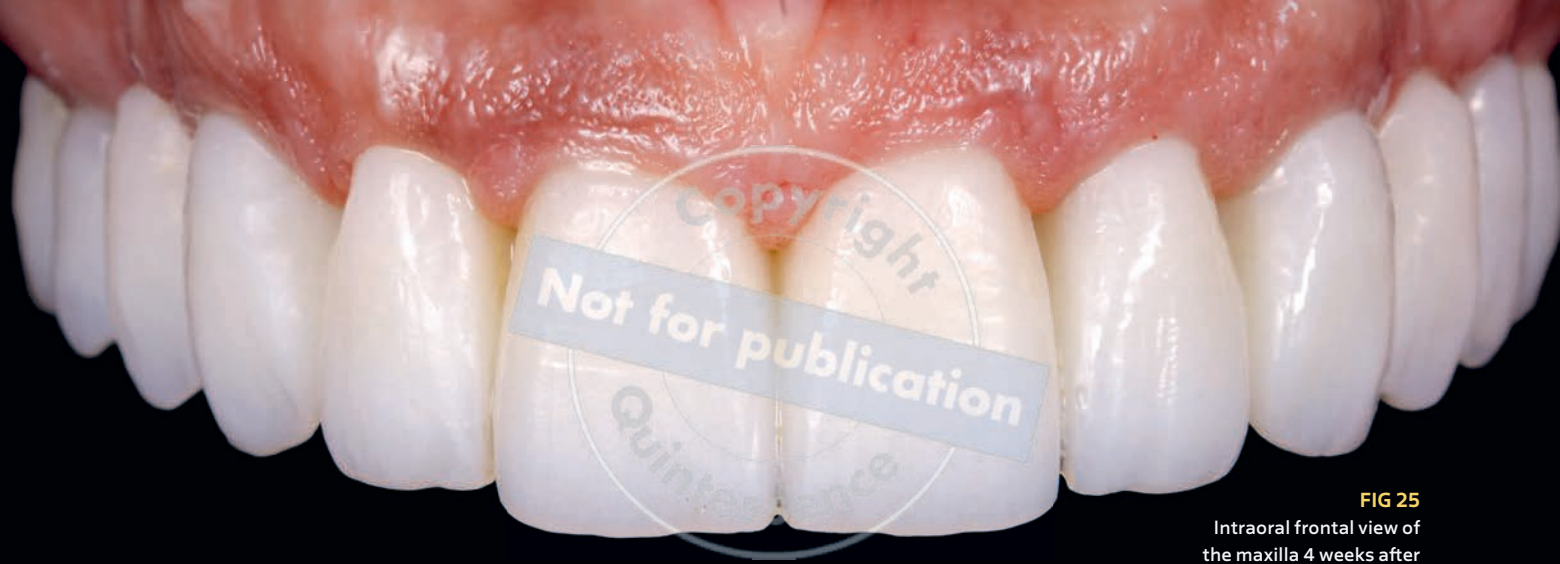

**FIG 23** Positioning of the provisional FP1 restoration with the prosthetic guide.



**FIG 24** Stackable 3D-printed guides for the mandible. (1) Base guide. (2) Base guide connected with positioning/implant placement guide using pins. (3) Base guide connected with the prosthetic guide and the provisional prosthesis.





**FIG 25**  
Intraoral frontal view of  
the maxilla 4 weeks after  
suture removal.

## Immediate Loading

When implants have a primary stability of at least 25 Ncm, an immediate loading approach, in which the implants and prosthesis are placed the same day, has been favorably reported in the literature with high success rates.<sup>18,19</sup>

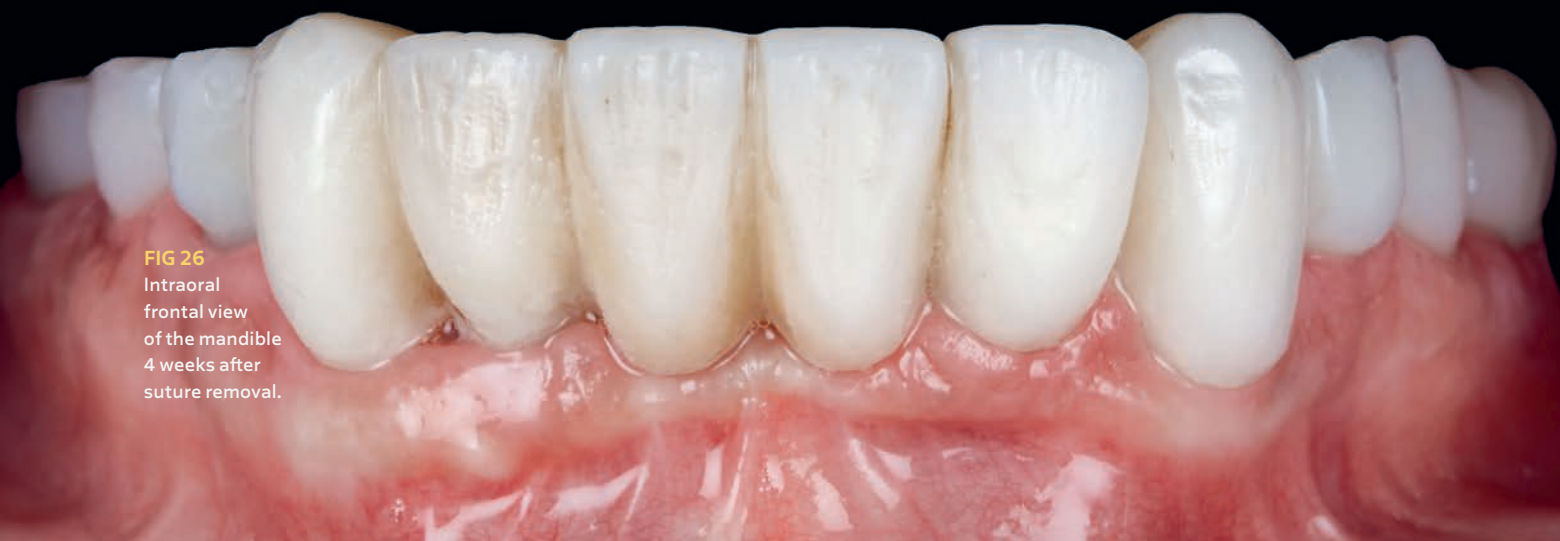After implant placement, temporary cylinders were inserted and a specially designed prosthetic guide was used to position the prefabricated FP1 provisional prosthesis according to the virtual treatment plan and to facilitate the engagement of temporary cylinders.

In the maxilla, the implant guide was removed, and the prosthetic guide was fixed using the same anchorage screws (see Fig 22). In the mandible, the prosthetic guide was inserted over the base guide using fixation pins.

The surface of the prosthetic channels was modified by airborne-particle abrasion with 50- $\mu\text{m}$   $\text{Al}_2\text{O}_3$  particles under

a pressure of 2.5 bars, followed by application of a phosphate monomer primer (Monobond Plus, Ivoclar). Rubber dam foils were used to isolate the surgical field around the base of each temporary cylinder. Subsequently, a flowable composite (Tetric A1 Evoflow, Ivoclar) was injected into each prosthetic channel for connection with the equivalent temporary cylinder. After the excess composite resin was cured, the provisional prosthesis was removed and the emergence profile further developed. Finally, the transmucosal surface was mechanically polished (see Fig 23).

Each provisional prosthesis was screwed onto the multi-unit abutments at 15 Ncm, and the patient was informed about the postoperative medications, diet, and recall schedule at the same appointment. Figures 25 and 26 show the status of the soft tissues 4 weeks after suture removal.



**FIG 26**  
Intraoral  
frontal view  
of the mandible  
4 weeks after  
suture removal.