

Bora Korkut, DDS, PhD



Esthetic Anterior COMPOSITE RESTORATIONS



 **QUINTESSENZ PUBLISHING**

Berlin | Chicago | Tokyo
Barcelona | London | Milan | Paris | Prague | Seoul | Warsaw
Beijing | Istanbul | Sao Paulo | Sydney | Zagreb



One book, one tree: In support of reforestation worldwide and to address the climate crisis, for every book sold Quintessence Publishing will plant a tree (<https://onetreepanted.org/>).

A CIP record for this book is available from the British Library.
ISBN: 978-1-78698-139-4

Title of original issue: Anterior Estetikte Kompozit Restorasyonlar
Copyright © 2022 Quintessence Türkiye



Quintessenz Verlags-GmbH
Ifenpfad 2-4
12107 Berlin, Germany
www.quintessence-publishing.com

Quintessence Publishing Co Ltd
Grafton Road, New Malden
Surrey KT3 3AB, United Kingdom
www.quintessence-publishing.com

Copyright © 2025 Quintessenz Verlags-GmbH, Berlin, Germany
All rights reserved. This book or any part thereof may not be reproduced, stored in a retrieval system, or transmitted in any form or by any means, electronic, mechanical, photocopying, or otherwise, without prior written permission of the publisher.

Translation: Bora Korkut, Türkiye
Editing, layout, production, and reproduction: Quintessenz Verlags-GmbH, Berlin, Germany

Printed and bound in Croatia

PREFACE

I am glad to share my knowledge and my clinical experiences with anterior direct composite restorations through this book. This text includes the clinical application protocols and techniques for anterior direct composite restorations that I have been lecturing on since 2015 at many national and international meetings, at more than 100 hands-on courses, and at my university. Here is a summary of my long-term patient follow-ups, related records, outcomes, knowledge, and experience gained over 3 years of working day and night. All of the application protocols and techniques are my own, performed in my clinic and assessed and previously discussed in various scientific papers. Additionally, all the restorative materials mentioned in the book are the materials I use in my daily clinical practice.

In a sense, this project is more of a visual presentation than a conventional book. The various cases and the material photographs are the meat of the book, which is supported by videos showing the application of the restorative techniques. This format is focused, easier to understand, and more memorable.

I own all the content presented in this book, including 1,197 clinical case photographs, 431 restorative material photographs, 31 application videos, and most of the scientific references. It was a difficult process to eliminate and select materials from a large archive of case photographs and videos, including numerous follow-up records of more than 1,000 patients.

This book is intended to give readers the knowledge needed to perform esthetic and long-lasting composite restorations in both simple and complicated

anterior cases. The text will guide readers in understanding correct clinical indications and performing minimally invasive treatment planning. Readers will also find up-to-date information on various restorative materials, with recommendations for how to use these materials properly depending on the case. Isolation techniques for different types of cases, alternative clinical application protocols, and layering techniques are all described. Readers will also learn to analyze surface morphology during finishing and polishing procedures. The clinical tips included throughout the book make it a great resource for both undergraduate and postgraduate students, as well as for clinicians.

There is a special chapter dedicated to complications, reasons for failure, and the outcomes of my own cases. This chapter provides visual references and simple solutions for dentists experiencing similar problems in the clinic. Real gains in life are born from mistakes, and I believe that this chapter will reinforce knowledge gained from earlier chapters.

Knowledge is increased by sharing, not by saving. Through this book, I hope my knowledge and experiences will create a significant positive difference in your clinical work.

I'd like to thank to Dr Ertuğrul Çetinkaya, Quintessence Publishing Türkiye, and Quintessence Publishing Germany and USA for their support and efforts in the production process.

Enjoy reading!
Associate Professor Bora Korkut, DDS, PhD





I dedicate my book to my lovely mother, Prof Dr Aslı Korkut, and father, Prof Dr Kayıhan Z. Korkut. Thank you for your academic teaching, endless support, and unique love.

AUTHOR



Associate Professor Bora Korkut, DDS, PhD

Dr Korkut graduated from Marmara University Faculty of Dentistry in 2008 and completed his doctorate thesis and PhD in Restorative Dentistry at Marmara University Faculty of Dentistry Department of Dental Diseases and Treatments in 2015. He has worked as an academic at Marmara University Faculty of Dentistry Department of Restorative Dentistry since 2015, earning an Assistant Professor title in 2018 and an Associate Professor title in 2022.

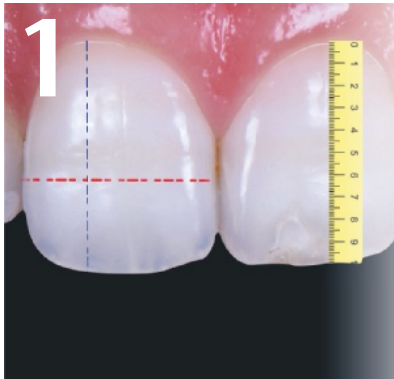
Dr Korkut has many national and international scientific publications about direct and indirect restorations, preresorative clear aligners, tooth bleaching, clinical dental photography, tooth wear, CAD/CAM restorations, magnification in dentistry, and caries diagnosis and management. He has presented many scientific lectures in national and international dental meetings about dental photography, anterior/posterior composite and ceramic restorations, clear aligners, ICON therapy, tooth bleaching, tooth wear, and restoration complications since 2015. He is a certified Invisalign provider. He has participated as an instructor in more than 100 hands-on courses since 2015.

He is a member of the GC Europe Restorative Advisory Board and the Bio-Emulation Group. He is also a key opinion leader and official international speaker of several leading international dental companies such as GC Corp, Hu-Friedy Group Europe, Tokuyama, Dentsply Sirona, Align Technology, Eighteeth, iVeneer, Polydentia, Ivoclar, Busch, and Horico.

TABLE OF CONTENT

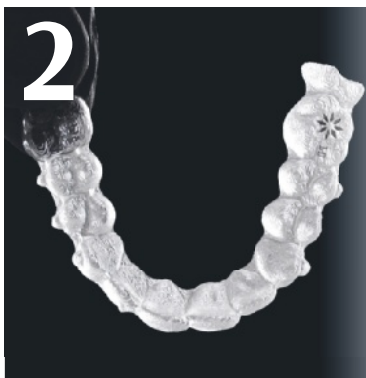

Preface v
Author vii





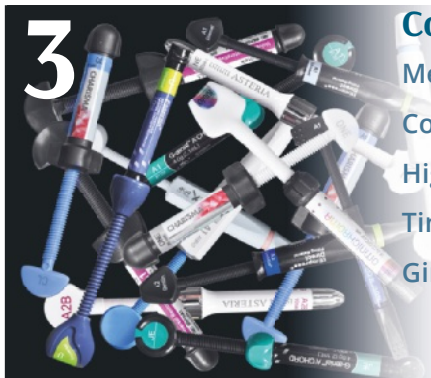1 Diagnosis and Treatment Planning 3

- Periodontal Assessment 4
- Endodontic Assessment 6
- Orthodontic Assessment 6
- Restorative Assessment 9



2 Pre-Restorative Procedures 21

- Periodontal Procedures 22
- Endodontic Procedures 26
- Orthodontic Procedures 26
- Tooth Bleaching 36 
- Microabrasion 40
- Resin Infiltration 42 
- Provisional Restorations and Silicone Index 50



3 Composite Material Selection 57

- Mechanical and Optical Properties 58
- Contemporary Resin Composites 60
- Highly Filled Flowable Composites 83
- Tint Resins and Opacifiers 86
- Gingiva-Colored Composites 90


4



Selection of Restorative Instruments 93

- Restorative Instruments for Anterior Restorations 94
- Armamentarium for Rubber Dam Isolation in the Anterior Region 104
- Matrix bands for Anterior Restorations 110
- Templates for Anterior Restorations 113

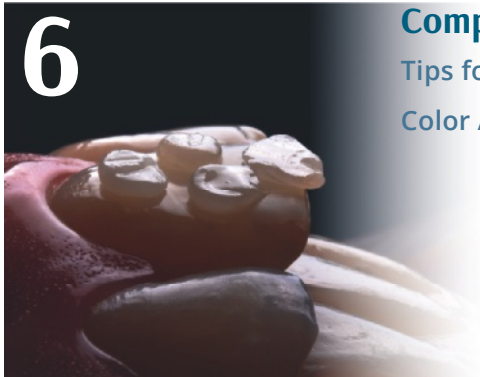5




Photopolymerization 119

- The Ideal Curing Unit 120
- Available Curing Units and Specifications 122
- Suggestions for Clinical Applications 130

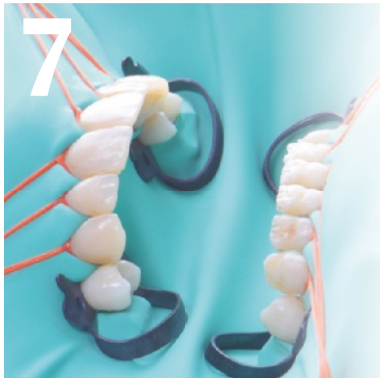6






Composite Shade Selection 135

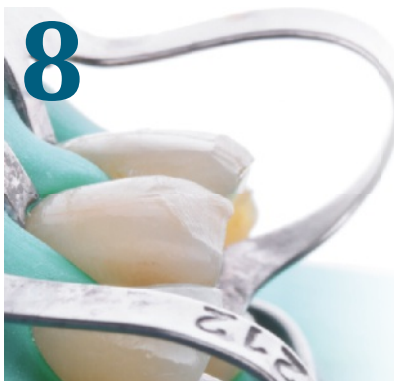- Tips for Shade Selection 136 
- Color Analysis With the Composite Button Technique 138

7




Isolation of the Operating Field 151

- Rubber Dam Isolation 152 
- Dental Floss Retraction 157 
- Clamp Retraction 162 
- Teflon Tape Application 166
- Isolation With Retraction Cords 168



8


Preparation 173

- Selective Composite Removal 174
- Class III Cavity Preparation 178
- Class IV Cavity Preparation 181
- Class V Cavity Preparation 184
- Direct Veneer Preparation 186 
- Veneer Preparation for Discolored Teeth 189



9

Adhesion 193

- Clinical Suggestions for Ideal Adhesion 194
- Composite Repair Protocol 202
- Reattachment Protocol for Crown Fractures 208 



10


Composite Layering 219

- Wetting Agents 220
- Layering Techniques According to Restorative Material Color 223
- Layering Techniques According to Restoration Type 224
 - Class III Restorations 224
 - Cervical Restorations 229 
 - Diastema Closure Restorations 232 
 - Peg-Shaped Lateral Incisor Restorations 242
 - Crown Fracture Restorations 244 
 - Direct Veneer Restorations 266 
 - Restoration of Discolored Teeth 280 
 - Injection Molding Technique 290 
 - Injectable Veneer Technique 292 
 - Composite Plastering Technique (CPT) 300 

11



Finishing, Surface Morphology, and Polishing 305

- Finishing Procedures for Composite Restorations 306 
- Polishing Procedures for Composite Restorations 338
- Dynamic and Static Occlusion Control and Adjustment 349
- Patient Instructions and the Control Appointment 349
- Follow-up Appointments 350

12



Complications and Solutions 353

- Postoperative Sensitivity 354
- Periodontal Problems 354
- Restoration Discoloration 364
- Color Mismatching Between Restorations and Teeth 372
- Marginal Adaptation Problems 380
- Iatrogenic Damage to Tooth Surfaces 385
- Restoration Fractures 386

Videos



Chapter 2

- Vital bleaching 38
- Icon application 49

Chapter 6

- Composite shade selection 138

Chapter 7

- Rubber dam application 1 155
- Rubber dam application 2 159
- Rubber dam application 3 163
- Rubber dam application 4 165

Chapter 8

- Preparation techniques 188

Chapter 9

- Reattachment of a complicated crown fracture 213
- Reattachment of an uncomplicated crown fracture 216

Chapter 10

- Cervical restoration 230
- Diastema closure: Free-hand monochromatic layering 234
- Diastema closure: Free-hand monochromatic layering 235

- Diastema closure: Layering with precontoured bands 236
 - Diastema closure: Layering with precontoured bands 237
 - Diastema closure: Layering with flowable composite 238
 - Diastema closure: Layering with flowable composite 239
 - Crown fracture restoration with silicone key 246
 - Crown fracture restoration with silicone key 248
 - Crown fracture restoration with Paladex 252
 - Crown fracture restoration with Paladex 254
 - Veneer restoration: Free-hand monochromatic layering 270
 - Veneer restoration: Polychromatic layering with Unica Anterior Matrix 278
 - Veneer restoration of discolored tooth 281
 - Veneer restoration of discolored tooth 286
 - Veneer restoration: Injection molding technique 290
 - Veneer restoration: Injection molding technique 291
 - Veneer restoration: Injectable veneer technique (iVeneer) 293
 - Composite plastering technique (CPT) 300
- ### Chapter 11
- Finishing, texturing, and polishing protocol 328
 - Finishing, texturing, and polishing protocol 336



VALO GRAND

Valo Grand (Ultradent) is a wireless polywave LED curing unit with a wavelength range of 385 to 515 nm (Fig 5-7). It is a one-of-a-kind curing unit with a tip diameter of 12 mm for restorative procedures (Fig 5-8). This tip allows for complete and effective occlusal surface polymerization, even for mesial-occlusal-distal (MOD) cavities of the mandibular molars. The tip angulation allows access up to the second molar, even with a jaw opening of 11 degrees. The curing unit is highly resistant to damage and scratches because it doesn't have a fiber tip.

Irradiances for the first two application modes for restorative procedures are 1,000 mW/cm² (1 × 10 s or 1 × 20 s) and 1,600 mW/cm² (3 × 4 s), respectively. The third mode, with an irradiance of 3,200 mW/cm², is suitable only for orthodontic procedures.

The tip filters are the same as for the Valo Cordless. Additionally, a unique White Light filter is available that provides 5,500K daylight and is used to select the shade of the restorative material. The penetration depth of this curing unit is very high, and the light scattering is very low (Fig 5-9).



Fig 5-7



Fig 5-8

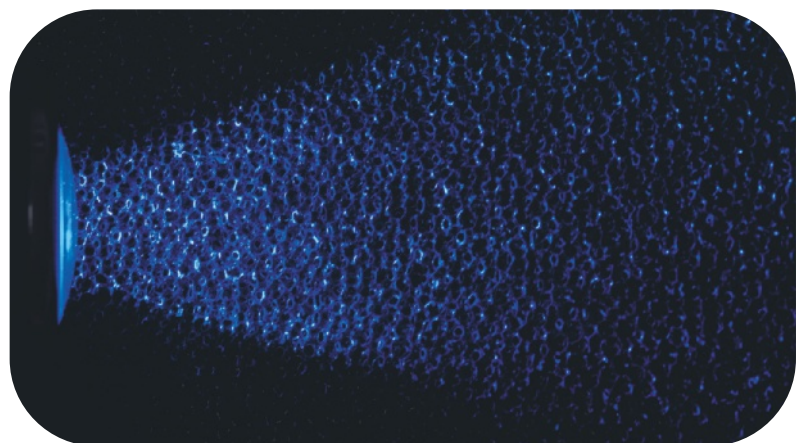


Fig 5-9

ELIPAR DEEPCURE-S

Elipar DeepCure-S (3M) is a wireless LED curing unit with a wavelength range of 430 to 480 nm (Fig 5-10). The tip has a diameter of 10 mm. It is fiber, which is a disadvantage in terms of the potential for damage and scratches (Fig 5-11). The tip angulation allows

access up to the second molar with a jaw opening of 15 degrees.

This curing unit is used for restorative procedures at 1,470 mW/cm² (1 × 10 s or 1 × 20 s) of irradiation. The penetration depth of the light is very high, and the scattering is very low (Fig 5-12).

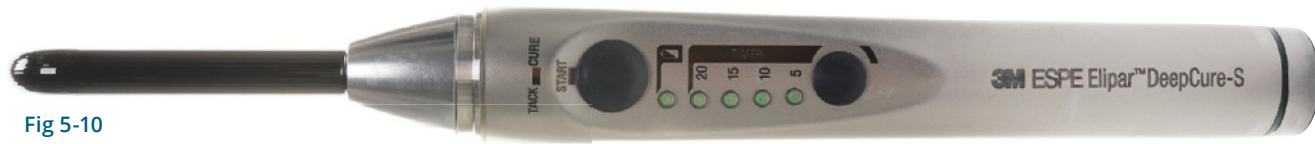

Fig 5-10




Fig 5-11




Fig 5-12

SMARTLITE PRO

SmartLite Pro (Dentsply Sirona) is a wireless poly-wave LED curing unit with a wavelength range of 405 to 480 nm (Fig 5-13). It has a tip diameter of 10 mm (Fig 5-14). It is resistant to damage and scratches because the tip is not fiber.

This curing unit is used for restorative procedures at 1,250 mW/cm² (1 × 10 s or 1 × 20 s) of irradiation. The penetration depth of the light is high, and the scattering is low (Fig 5-15). This curing unit also has a transillumination tip for the diagnosis of interproximal caries and the detection of cracks.



Fig 5-13



Fig 5-14




Fig 5-15

copyright by
not for publication

BLUEPHASE POWERCURE

The Bluephase PowerCure (Ivoclar Vivadent) wireless polywave LED curing device has a wide wavelength range of 385 to 515 nm (Fig 5-16). It has a fiber tip with a diameter of 9 mm (Fig 5-17). The fiber tip can be considered a disadvantage in terms of the risk of damage and scratches.

High mode in this device provides an irradiation of $1,200 \text{ mW/cm}^2$ ($1 \times 10 \text{ s}$) and can be used for all direct and indirect restorations. Turbo mode provides an irradiation of $2,000 \text{ mW/cm}^2$ ($1 \times 5 \text{ s}$) and is indicated for all direct and indirect restorations. The 3s mode is a contemporary restorative mode providing

an irradiation of $3,000 \text{ mW/cm}^2$ ($1 \times 3 \text{ s}$). This mode can be used to achieve curing in only 3 seconds but only for specific materials, such as Adhese Universal, Tetric PowerFill, and Tetric PowerFlow (all from Ivoclar Vivadent). The PreCure mode is indicated for the removal of excessive cement during indirect cementation procedures.

There is also a control system called Polyvision Technology that causes the device to vibrate when the tip moves away from the application field and simultaneously adds 10% time. The penetration depth of the light is very high, and the scattering is also very low (Fig 5-18).



Fig 5-16




Fig 5-17




Fig 5-18

D-LIGHT PRO

D-Light Pro (GC) is a polywave LED curing unit with a wavelength range of 400 to 465 nm (Fig 5-19). The diameter of the tip is 8 mm, and it is a fiber tip, a disadvantage in terms of the risk of damage and scratching (Fig 5-20).

The Low Power (LP) mode provides an irradiation of 700 mW/cm^2 ($1 \times 20 \text{ s}$), and the High Power (HP) mode provides $1,400 \text{ mW/cm}^2$ ($1 \times 20 \text{ s}$), which can be used for direct and indirect restorations.

This curing unit also has a Detection (DT) mode that enables the use of near UV light to detect infected dentin, dental plaque, microcracks, and old composite restorations. The penetration depth of the light is high, and the scattering is also low (Fig 5-21).



Fig 5-19




Fig 5-20




Fig 5-21




Fig 5-23

VALO X

Valo X (Ultradent) is a polywave cordless LED curing unit with a wavelength spectrum range of 385 to 515 nm (Fig 5-22). It is one of a kind, with a tip diameter of 12.5 mm for restorative procedures (Fig 5-23). It can be used to perform complete and effective occlusal surface polymerization even for MOD cavities of the mandibular molars. This curing unit is highly resistant to damage and scratches because it does not have a fiber tip.

The tip angulation enables reaching up to the second molar even with a jaw opening of 11 degrees. Irradiances for the two application modes are 1,100 mW/cm² for Standard Mode (1 × 10 s) and 2,200 mW/cm² for Extra Power Mode (2 × 5 s) for restorative procedures. Black Light and White Light diagnostic modes are integrated in the device, and there are also additional lenses for curing (Fig 5-24).

It has the same tip filters as the Valo Cordless. Additionally, it has a unique White Light filter, which provides 5,500 K daylight and is used to select the shade of the restorative material. The penetration depth of this curing unit is very high, while the light scattering is very low (Fig 5-25).



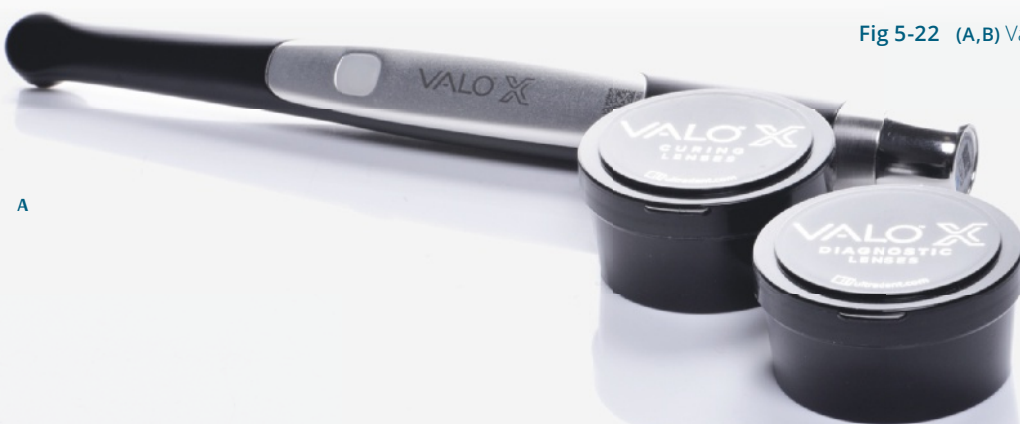
Fig 5-24 (A) Interproximal Lens. (B) Proxicare Ball Lens. (C) Translume Orange Lens. (D) Black Light Lens.




Fig 5-25



Fig 5-22 (A,B) Valo X.



B

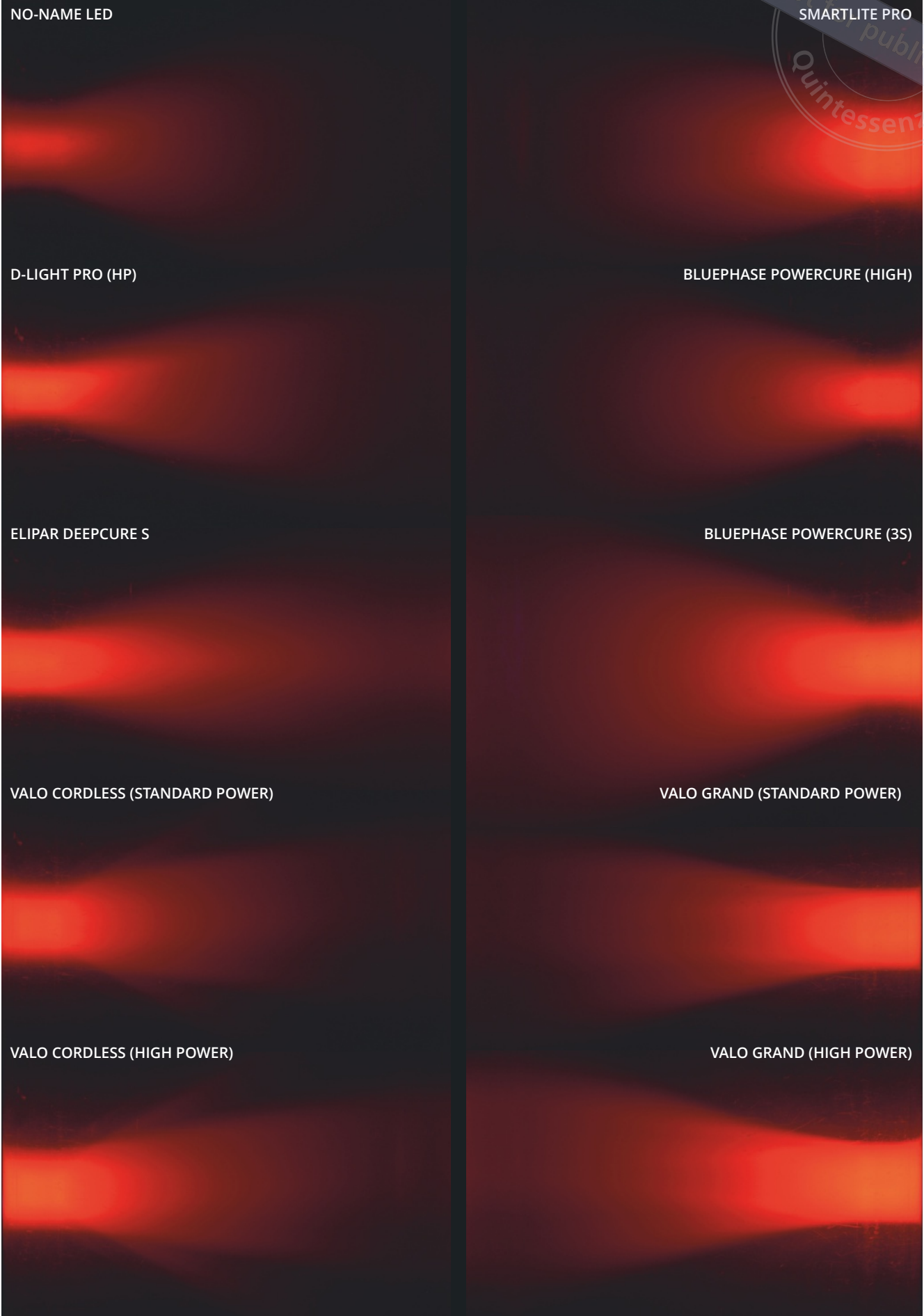


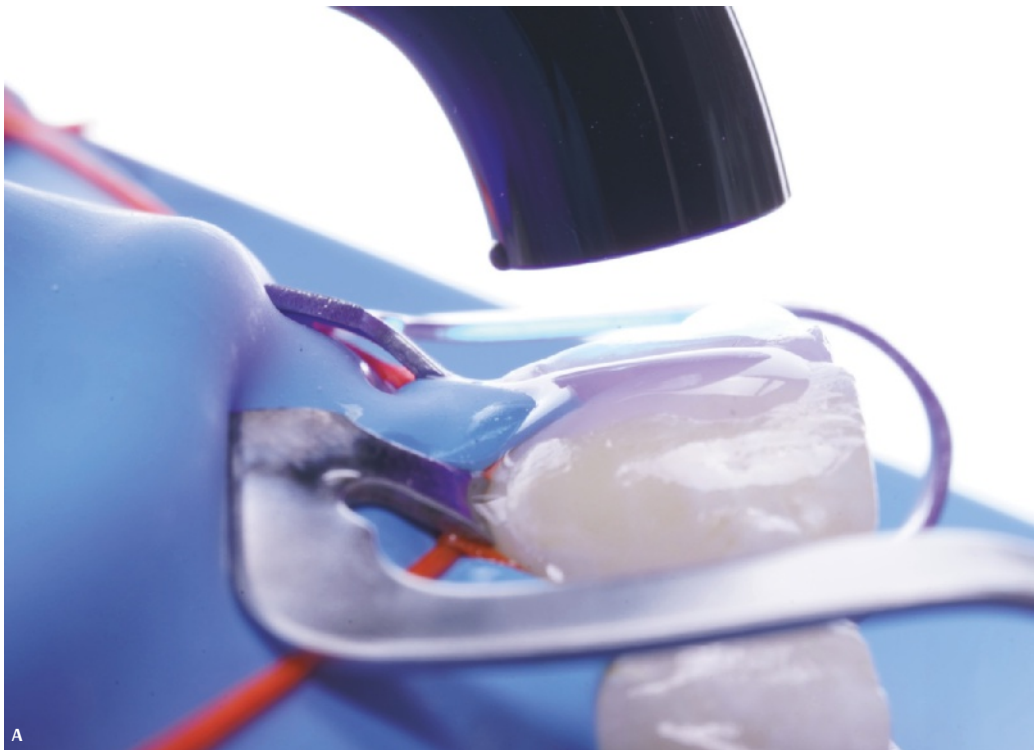
Fig 5-26 Penetration depth and light scattering.

SUGGESTIONS FOR CLINICAL APPLICATIONS

The tip of the curing unit should be positioned parallel and as close to the restoration surface as possible (Figs 5-27 and 5-28). Depending on the tip diameter of the selected curing unit and the dimensions of the restoration surface, the restoration surfaces can be divided as mesial and distal

for curing, and thus, the total curing time should be increased accordingly.

The irradiation of the curing unit should be measured periodically with an LED radiometer. The integrated radiometers on curing units are used for detecting differences in irradiation over time. Detected loss in irradiation should be compensated for by adding accordingly to the total curing time for effective polymerization.



CLINICAL TIP

The tip of the curing unit should be placed as close as possible to the restoration surface with minimum angulation. The tip should be clean, without cracks or scratches.

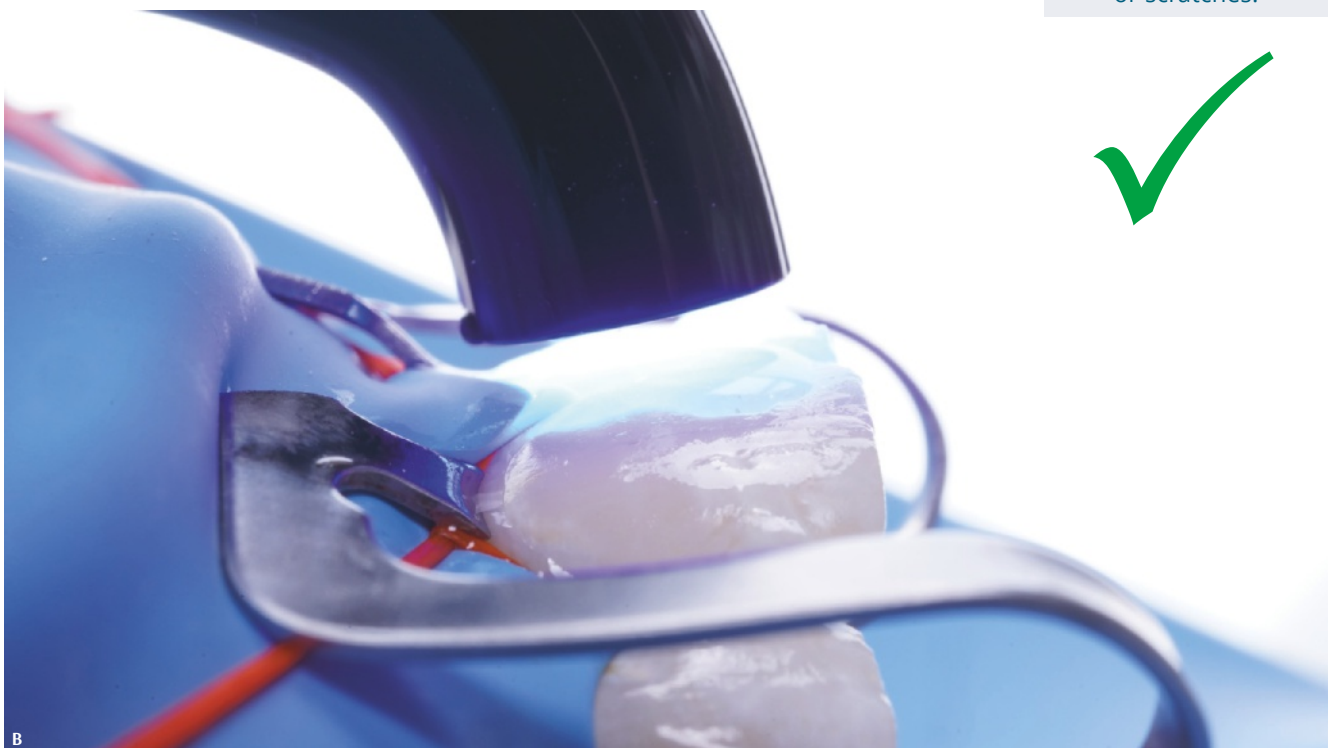


Fig 5-27 Positioning the tip of the curing unit.

It is very important to keep the tip of the curing unit undamaged and clean. The many photoreceptors inside the tip are mainly the fibers (Fig 5-29). Damaged or scratched tips may significantly reduce the irradiation of the device. Adhesive and resin composite residues remaining on the tip should not be scraped off with stainless steel instruments, due to the risk of creating scratches on the photoreceptors. Wooden instruments should be preferred. Additionally, to avoid decreasing the irradiation, PVC-based cling film should be applied in only a single layer when used to isolate the light device, or it shouldn't cover the tip.

Before clinical application, it should be ensured that the polymerization wavelength of the selected resin composite is within the range of the curing unit. Then, the resin composite should be cured with the recommended irradiation for the recommended time.

CLINICAL TIP

The irradiance of the curing unit should be measured periodically. The irradiance decreases as the machine ages, so curing times should be increased accordingly.

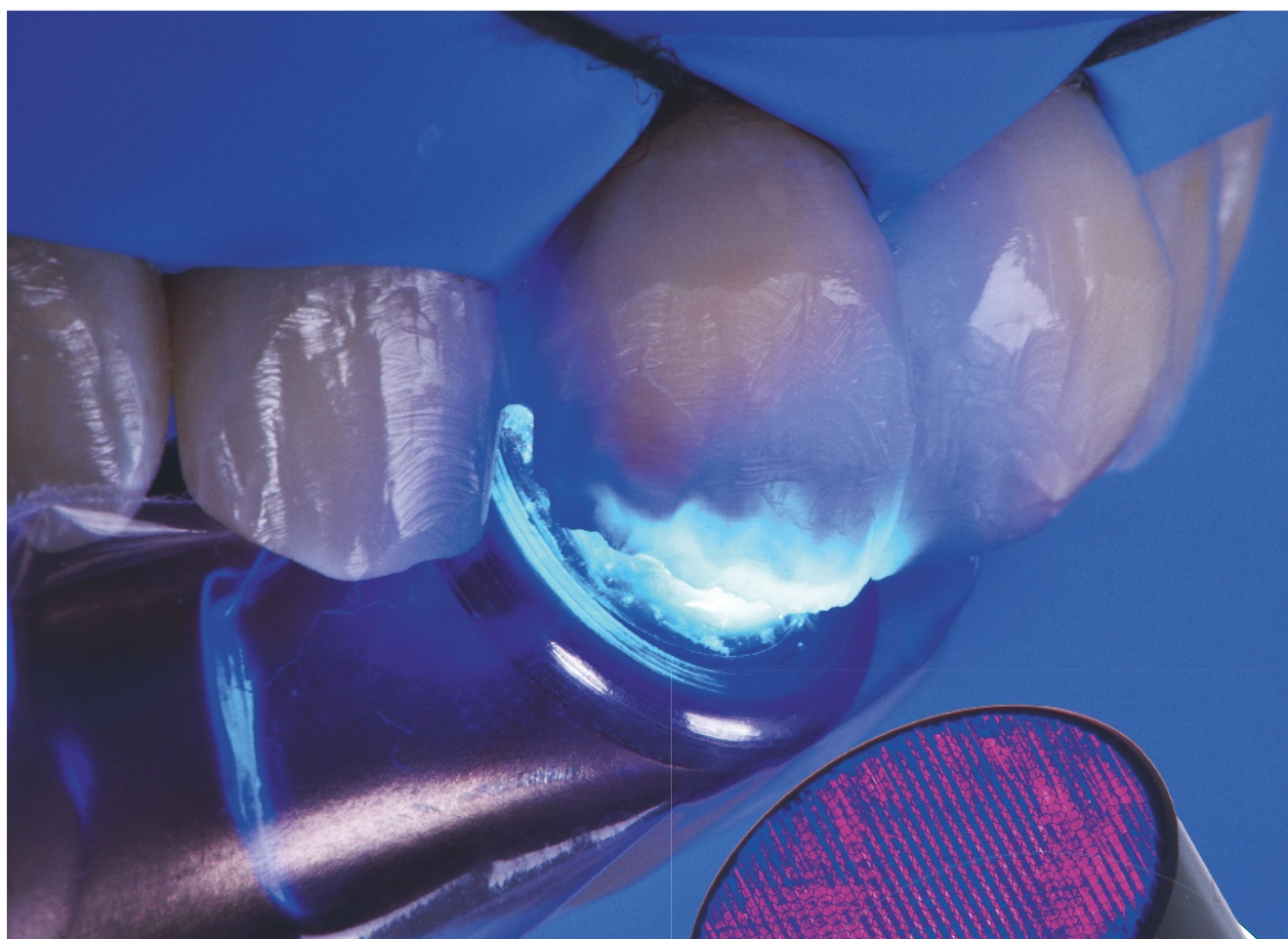


Fig 5-28




Fig 5-29

copyright by
not for publication
Essenz

REFERENCES

1. Stansbury JW. Curing dental resins and composites by photopolymerization. *J Esthet Dent* 2000;12:300–308.
2. Federlin M, Price R. Improving light-curing instruction in dental school. *J Dent Educ* 2013;77:764–772.
3. Dikova T, Maximov J, Todorov V, Georgiev G, Panov V. Optimization of photopolymerization process of dental composites. *Processes* 2021;9:779–793.
4. Dunne SM, Millar BJ. Effect of distance from curing light tip to restoration surface on depth of cure of composite resin. *Prim Dent Care* 2008;4:147–152.
5. França FMG, Hor, FS, Santos AJSD, Lovadino JR. The effect of insertion and photopolymerization techniques on microleakage of class V cavities: A quantitative evaluation. *Braz Oral Sci* 2005;19:30–35.
6. Bhatt S, Ayer CD, Price RB, Perry R. Effect of curing light and restoration location on energy delivered. *Compend Contin Educ Dent* 2015;36:208–210.
7. Price RB, Felix CA, Andreou P. Evaluation of a second-generation LED curing light. *J Canadian Dent Assoc* 2003;69:666a–666h.
8. Samaha S, Bhatt S, Finkelman M, et al. Effect of instruction, light curing unit, and location in the mouth on the energy delivered to simulated restorations. *Am J Dent* 2017;30:343–349.
9. Korkut B, Tarçın B, Topbaşı NM, Yılmaz Atalı P. Photopolymerization in restorative dental treatment. In: Evreklioglu C (ed). *Academic Studies in Health Sciences*, vol 1. Gece Kitaplığı/Gece Publishing, 2020:91–106.
10. Korkut B. Resin composite restorations in anterior aesthetics. In: Kulak Ozkan Y, Aslan U (eds). *Smile Aesthetics and Lamina Veneer Restorations*. Quintessence Turkey, 2022:172–192.
11. Bud M, Zlăvog M, Jitaru Ş, Korkut B, Spataru S, Delean A. The outcome of direct composite restorations using the dental operating microscope. *Med Pharm Rep* 2021;94:477–482.
12. Korkut B, Dokumacıgil G, Murat N, Atalı PY, Tarçın B, Gocmen GB. Effect of polymerization on the color of resin composites. *Oper Dent* 2022;47:514–526.
13. Korkut B, Bud M, Kukey P, Sancaklı HS. Effect of surface sealants on color stability of different resin composites. *Med Pharm Rep* 2022;95:71–79.

copyright by
not for publication
Quintessenz





Composite Shade Selection

Shade mismatch in anterior composite restorations is an irreversible complication!

TIPS FOR SHADE SELECTION

Composite shade selection is the very first thing that should be done at an appointment for restorative treatment. It is a very important step. Errors in composite shade selection for anterior restorations are irreversible and usually require replacement of the restoration.

The natural dental tissues dehydrate while clinicians take photographs and perform clinical procedures.

This produces temporary color changes. These changes are mainly related to increases in the value parameter of color, which causes the tooth to appear more opaque (Fig 6-1). The level of dehydration varies from patient to patient and from tooth to tooth. That's why shade selection should be performed before any clinical interventions that might cause complications related to dehydration and color changes.

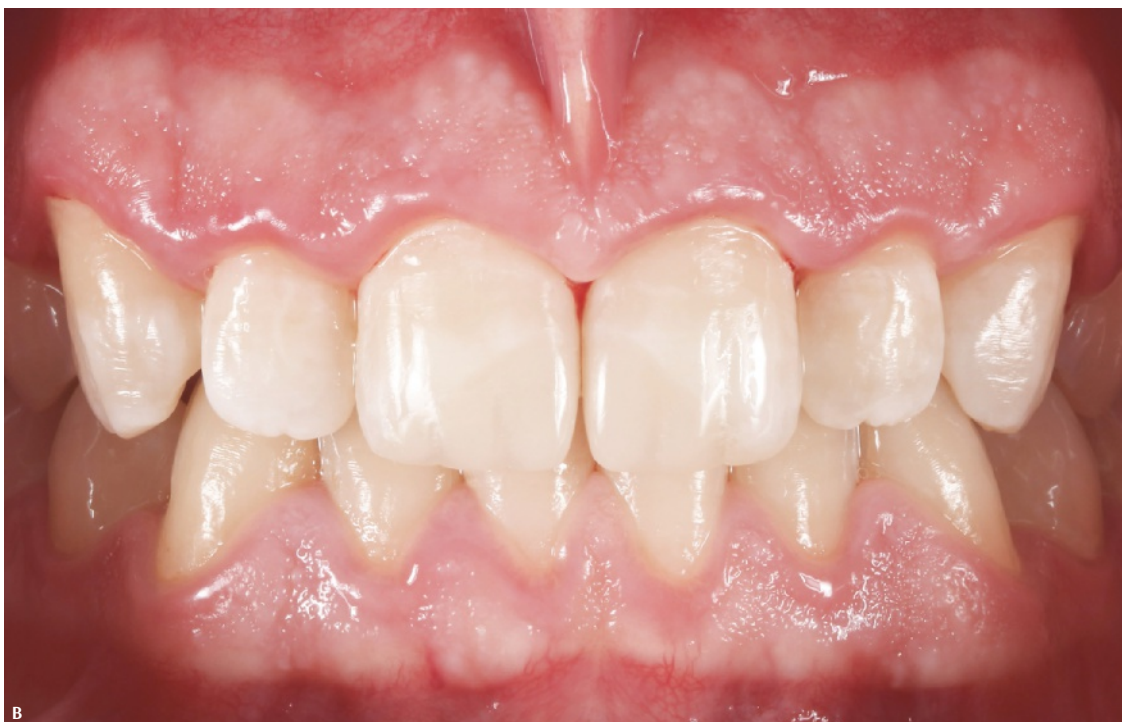
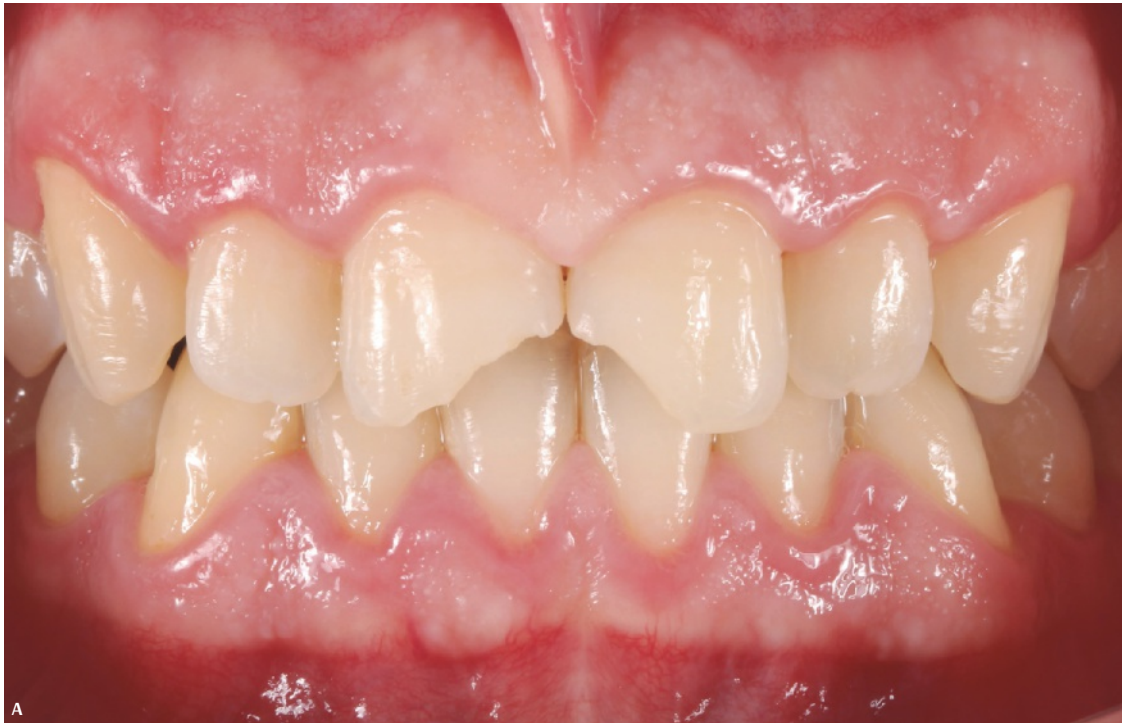
Fig 6-1 (A) Before restoration (hydrated dental tissues). (B) Immediately after restoration (dental tissues dehydrated for 2 hours).

Color change is perceptible at the 2-minute marker after dehydration begins and increases with time. Even after the teeth are rinsed with water or covered with saliva for a while, rehydration (and return to the normal color) usually requires 24 hours. As a result, if shade selection cannot be completed within the first 2 minutes of an appointment, there is no chance to try again the same day. However, it is important to note that restorations usually appear darker than the teeth immediately after they are performed, even if the shade is selected properly. This is because the natural dental tissues are also dehydrated during restorative procedures, resulting in a more opaque white appearance. This temporary color mismatch should be ignored, and a color matching evaluation should be performed a minimum of 24 hours after rehydration.

Dental color consists of three main parameter: hue, value, and chroma. Additionally, in accordance with some recent scientific evidence, translucency can be considered a fourth parameter. The sum of the individual effects of these parameters at different levels generates the final color. In particular, value plays an important role in determining dental color (Fig 6-2).

Vita shade guides are specially designed for indirect ceramic restoration materials and should never be used for composite shade selection. Even if manufacturers claim that certain composite materials have shades compatible with the Vita Classical Shade Guide, making general color determinations can lead to missteps in clinical practice. Likewise, digital colorimeters and spectrophotometers are also designed to quantitatively determine the color of indirect ceramic materials, CAD/CAM materials, and natural dental tissues. Therefore, accurate and reproducible composite shade selection is not always obtained with these devices. Even shade guides designed for the relevant materials in composite kits can be misleading because of the incompatibility between the fixed composite sample thicknesses and the final thicknesses of restorations.

CLINICAL TIP

Color consists of three parameters: hue, value, and chroma. The value of a color (the amount of light reflected from the surface) should be well understood for the attainment of good color matching.

CLINICAL TIP

The value of a color decreases with increases in chroma and/or translucency.

CLINICAL TIP

That is why the masking ability of highly chromatic shades and highly translucent enamel shades is generally low.

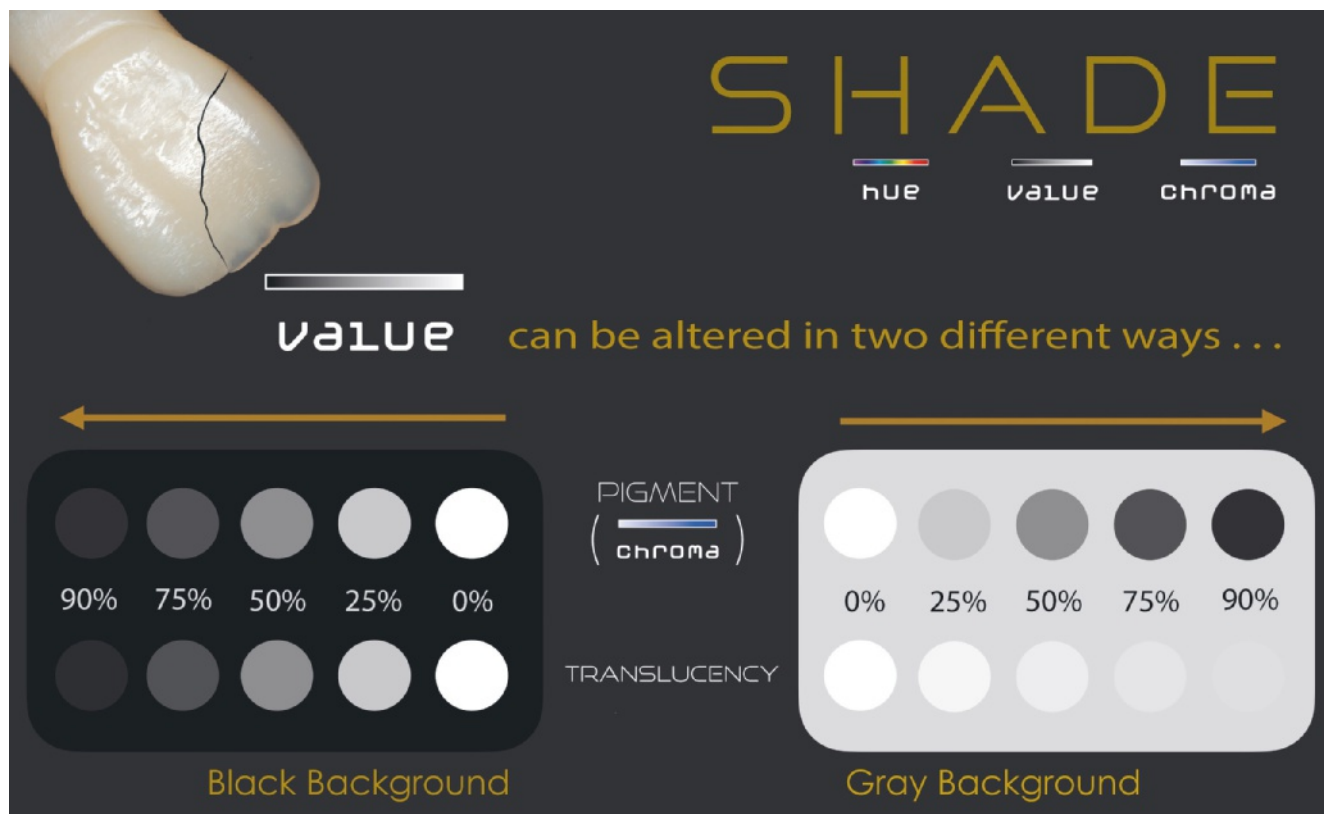


Fig 6-2 The three main parameters of color and their interactions.

COLOR ANALYSIS WITH THE COMPOSITE BUTTON TECHNIQUE

One of the best techniques for selecting a composite shade is the Composite Button Technique, which minimizes errors in color analysis.

In this technique, a few small, round composite pieces of different shades are placed on the vestibular surface of the tooth that will be restored or the adjacent/symmetrical tooth. The buttons are selected from the shade options in the composite kit that are most likely to be used and considered closest to the shade of the tooth in question. It is important not to apply any adhesive procedures to the tooth surface. The composite buttons are usually 1.5 to 2 mm thick, which is the average composite layering thickness for restorations. Button thickness can, however, be adjusted according to whatever the thickness of the future restoration is estimated to be.



Composite buttons can be grouped for the cervical third, mid third, and incisal third if these surfaces are different colors (Fig 6-3). The buttons placed in the cervical and mid third should be shades of medium to high opacity (body, dentin, and opaque dentin shades), whereas in the incisal third, translucent and opalescent shades (enamel shades) should be placed (see chapter 3). The buttons at the incisal third should be positioned slightly beyond the incisal edge to assess the translucency of the shade (see Fig 6-3). In some cases, the shades in a single composite kit are not sufficient for precise shade matching, so having alternative composite kits available and experience with them can be advantageous in clinical practice.

To minimize shade selection errors due to light reflections, the surfaces of composite buttons should be flattened, and convex surfaces should be avoided. Additionally, it is very important that the composite buttons are appropriately polymerized before shade assessment. This is because resin-based materials may change color after polymerization, usually becoming approximately 1 to 1.5 shades lighter.

Finally, the composite buttons are evaluated either visually or with dental photography equipment. It is vital that all the procedures that must be performed prior to this evaluation are completed within 2 minutes to avoid dehydration and skewed shade matching (Fig 6-4).

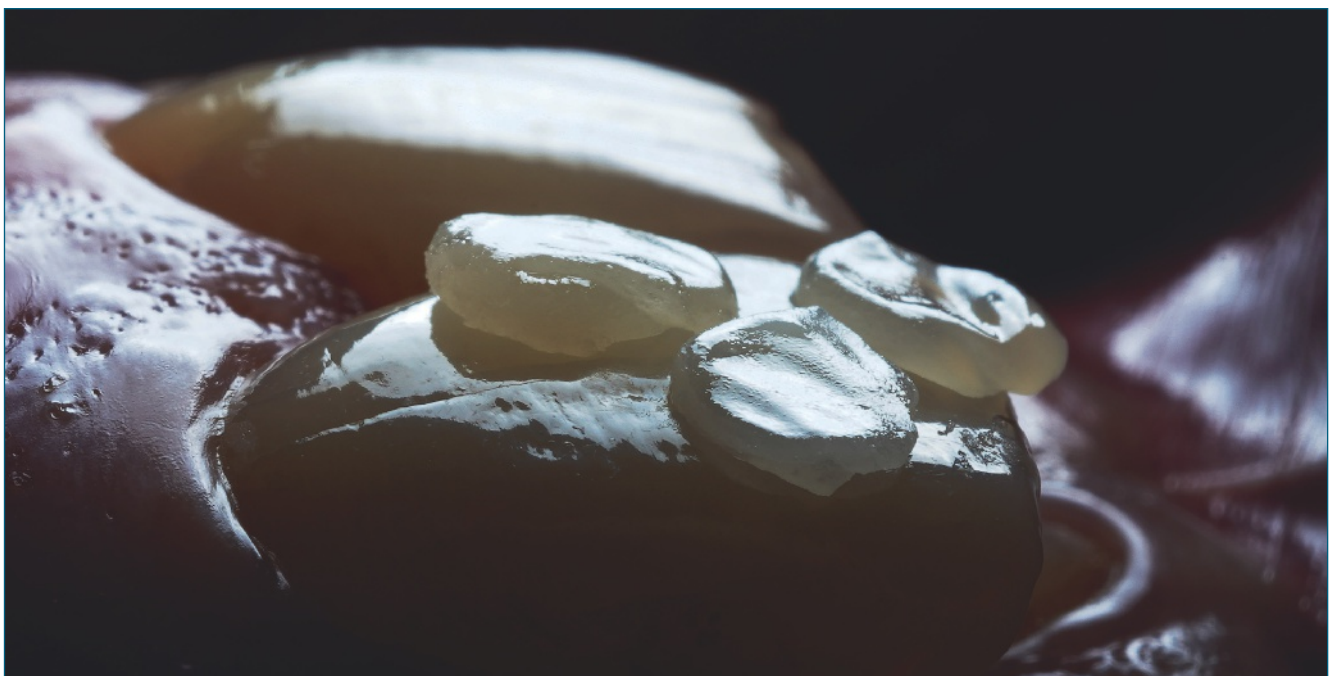

Fig 6-3 Composite button technique.

REATTACHMENT PROTOCOL FOR CROWN FRACTURES

The first goal with anterior crown fracture restorations should be to preserve and properly provide reattachment of the fractured tooth fragment. It is a well-known fact that even the best restoration will not be better than the fragment of the tooth itself in terms of esthetics and function.

In cases of crown fracture, patients should be instructed not to discard the broken fragment and to keep it in a safe and clean container including a solution such as the patient's own saliva, milk, or saline until the treatment session. In addition, trauma cases should be carefully evaluated and detailed questions and examinations should be made to determine the vitality of the tooth before treatment. In complicated crown fractures involving the pulp tissue, the tooth should first be evaluated endodontically and treated if necessary. It should be remembered that vitality scores may be misleading shortly after a traumatic incident and provide false positives or negatives. Even in uncomplicated crown fractures, the patient should be informed that regular follow-ups will be necessary and that the tooth may require endodontic treatment in the future.

Although there are multiple clinical protocols for the reattachment of fractured crown fragments, the currently accepted method is to prepare minor internal grooves in the fractured fragment and in the tooth fragment and to perform the adhesion process afterward. Additional corrections on the vestibular surface can be performed as a last step to achieve better esthetic outcomes.

In the dentin tissue of the broken fragment and the tooth fragment, circular inner grooves that are approximately 1 mm deep and 1 mm wide are prepared first (Fig 9-9). The retaining grooves are intended to increase bond strength. However, depending on the fracture shape, there are also simple reattachment protocols that do not require the generation of grooves (Fig 9-10). If there is more than one fracture fragment, the fragments should first be attached to each other and then to the tooth (Fig 9-11).

After generating the grooves, the relevant tooth fragment is isolated in the mouth and the opposing surfaces are roughened with phosphoric acid etching. The etching should be performed over a larger area, especially on the vestibular surface. After etching, the adhesive agent is applied to the roughened surfaces but preferably not light cured to avoid a thick film layer. This protocol is not valid, however, for universal adhesives that can provide a relatively very thin film thickness of 3 to 5 μm .

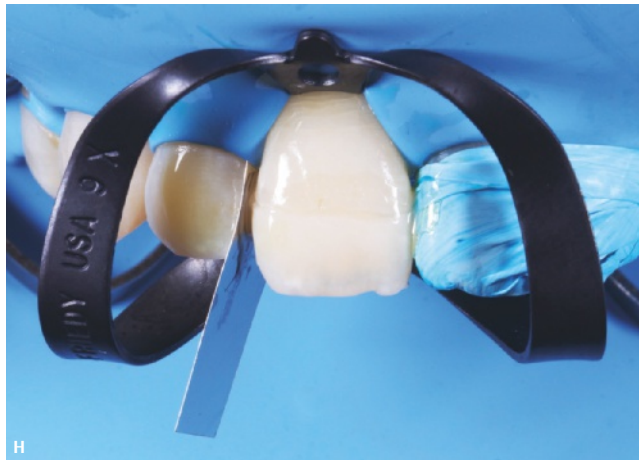
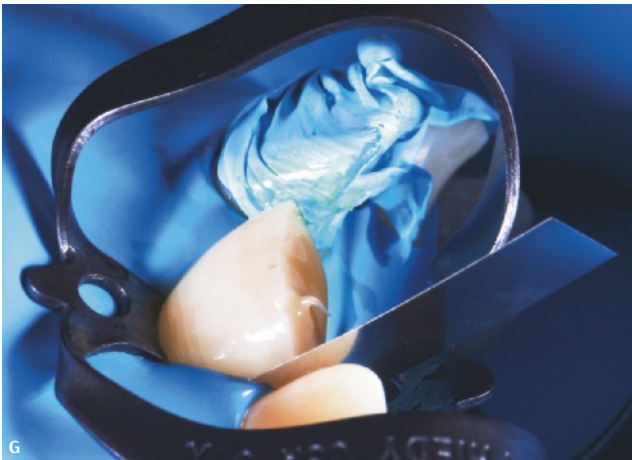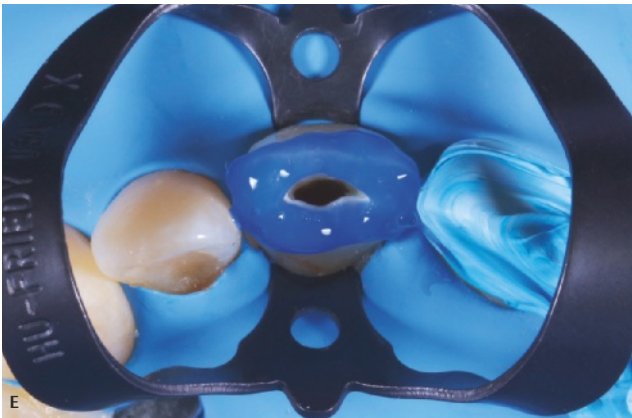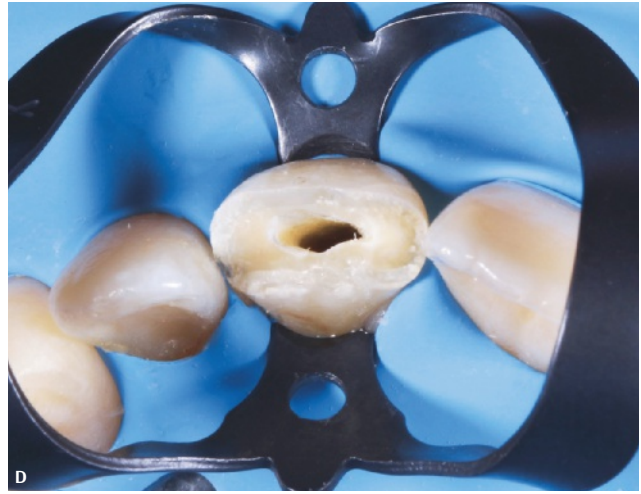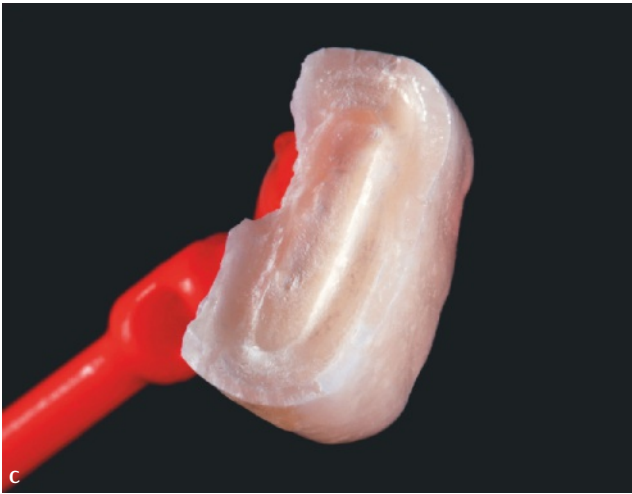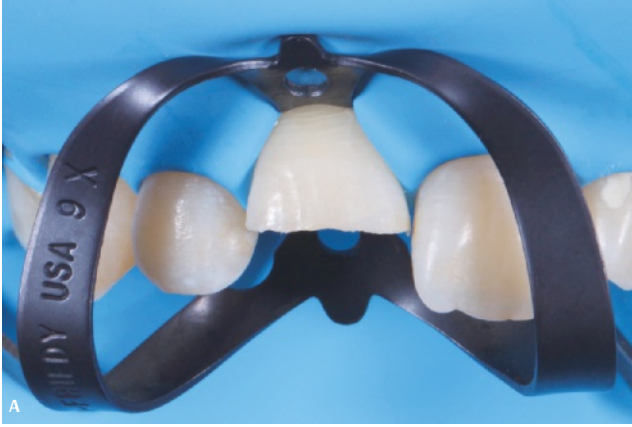Either a resin cement or a highly filled flowable composite can be used for luting. After the luting composite is placed on both surfaces, the fracture fragment is attached with pressure (see Figs 9-9G,H). Before light curing, the excessive composite material is carefully removed. Afterward, the polymerization is done from the vestibular and lingual/palatal surfaces.

Without appropriate vestibular surface beveling, a poor esthetic appearance may result due to the different refraction indexes of light on the two surfaces that are divided by a sharp fracture line. Therefore, the vestibular surfaces of both sides of the fracture line are slightly beveled with a suitable diamond bur (see Fig 9-9I).

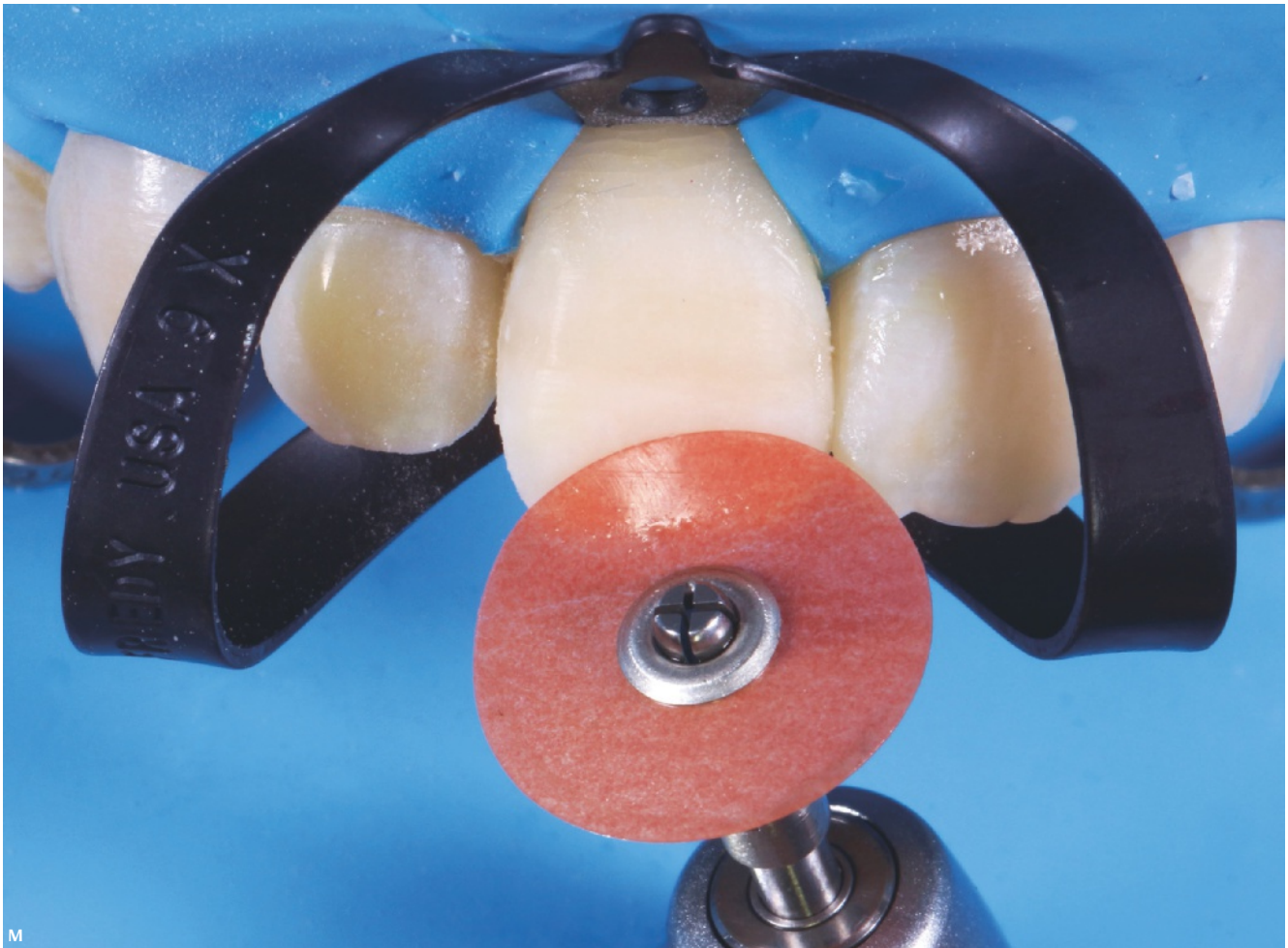
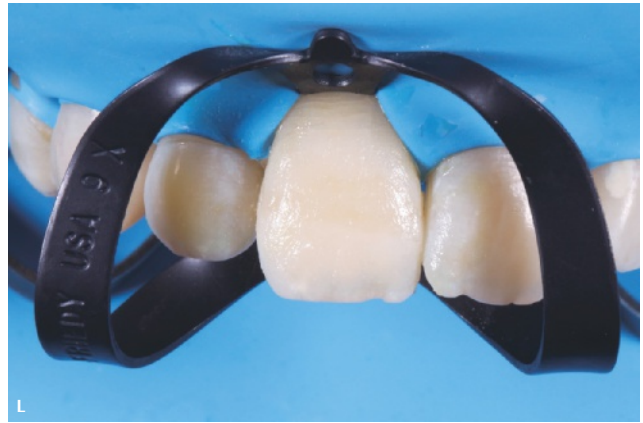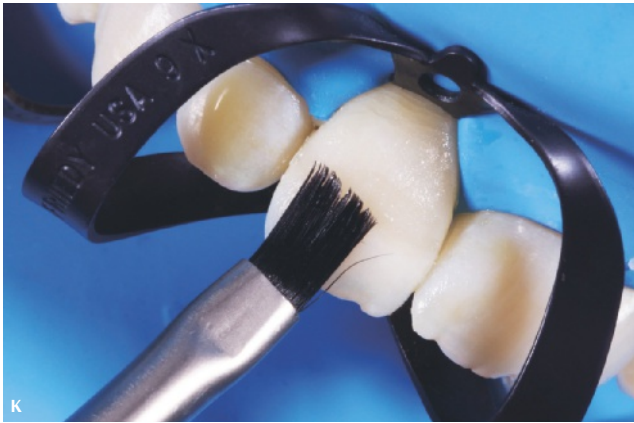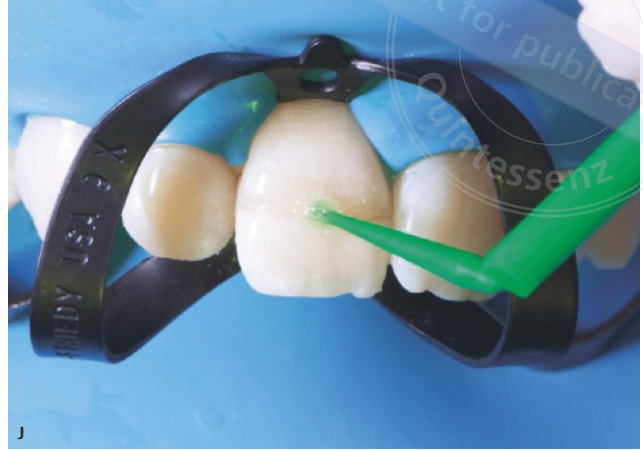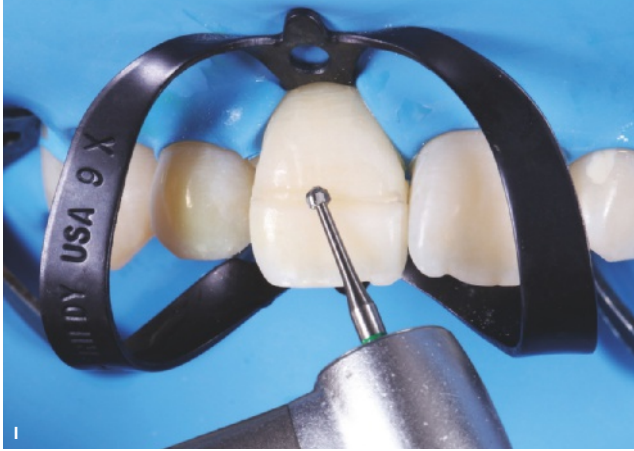After beveling, acid etching and adhesive agent application procedures are repeated on this surface (see Fig 9-9J). Preferably, the etching should be performed slightly beyond the beveling borders. Finally, the beveled surface is restored with a body or dentin shade resin composite (see Figs 9-9K,L). Following restoration, polishing procedures are performed at the same appointment and repeated at least 24 hours after, at the control appointment (see Figs 9-9M to Q).

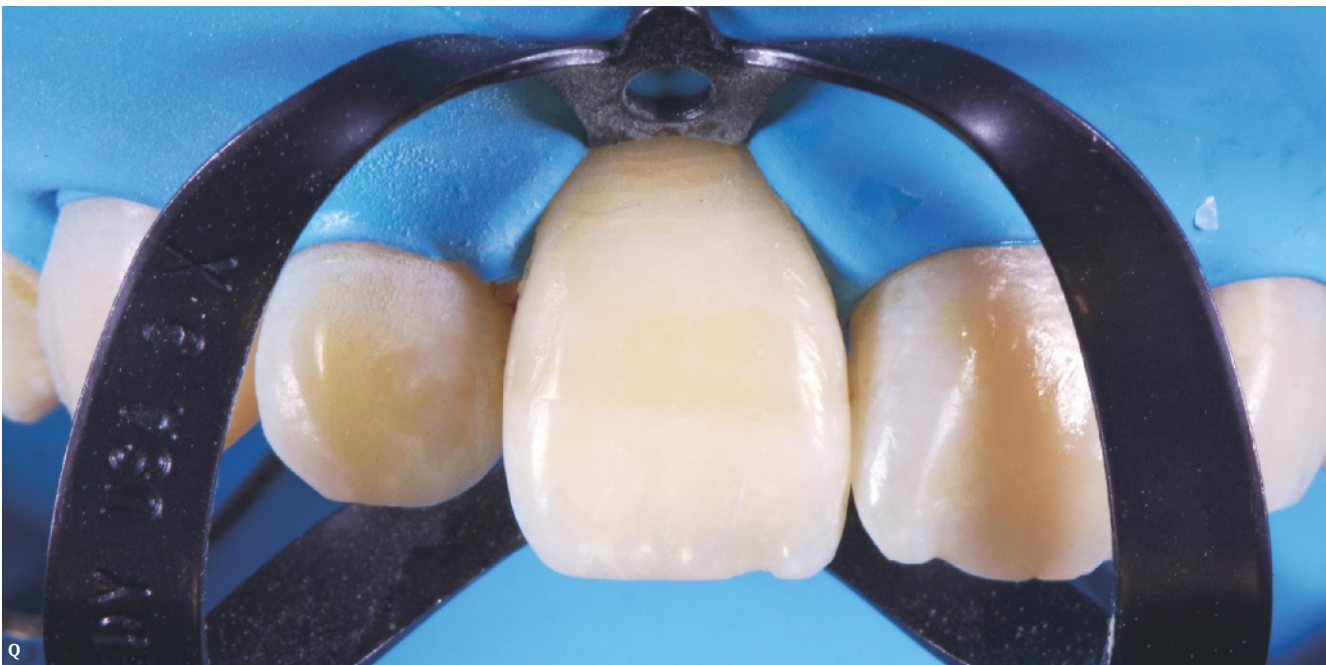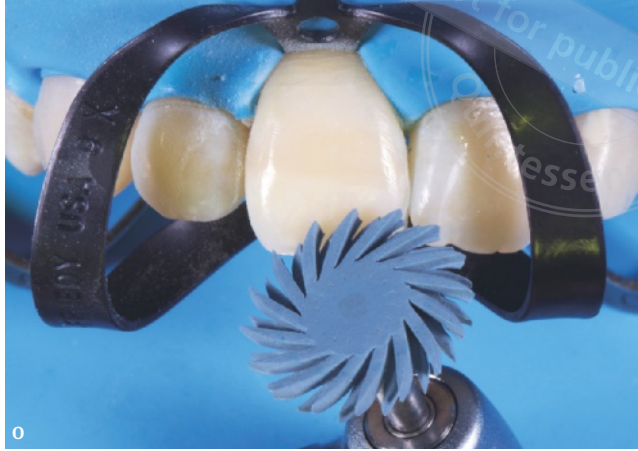Additionally, splinting of the traumatized anterior teeth can be performed following the reattachment procedure to stabilize the teeth and thereby aid the healing mechanisms of the dental and supportive tissues.

Fig 9-9 (A) Rubber dam isolation. (B) Dentin groove preparation. (C) Fractured fragment and the dentin groove. (D) Cleaning the attachment surface. (E) Roughening the attachment surface with etching. (F) Roughening the fragment surface with etching. (G) Adhesive agent and flowable composite application. (H) Reattachment of the fragment. (I) Beveling on the labial surface of the fracture line. (J) Adhesive agent application. (K,L) Composite layering. (M) Surface finishing with the polishing disk. (N,O) Surface polishing with the spiral polishing wheels. (P) Interdental polishing. (Q) Final.



copyright by
not for publication
Quintessenz



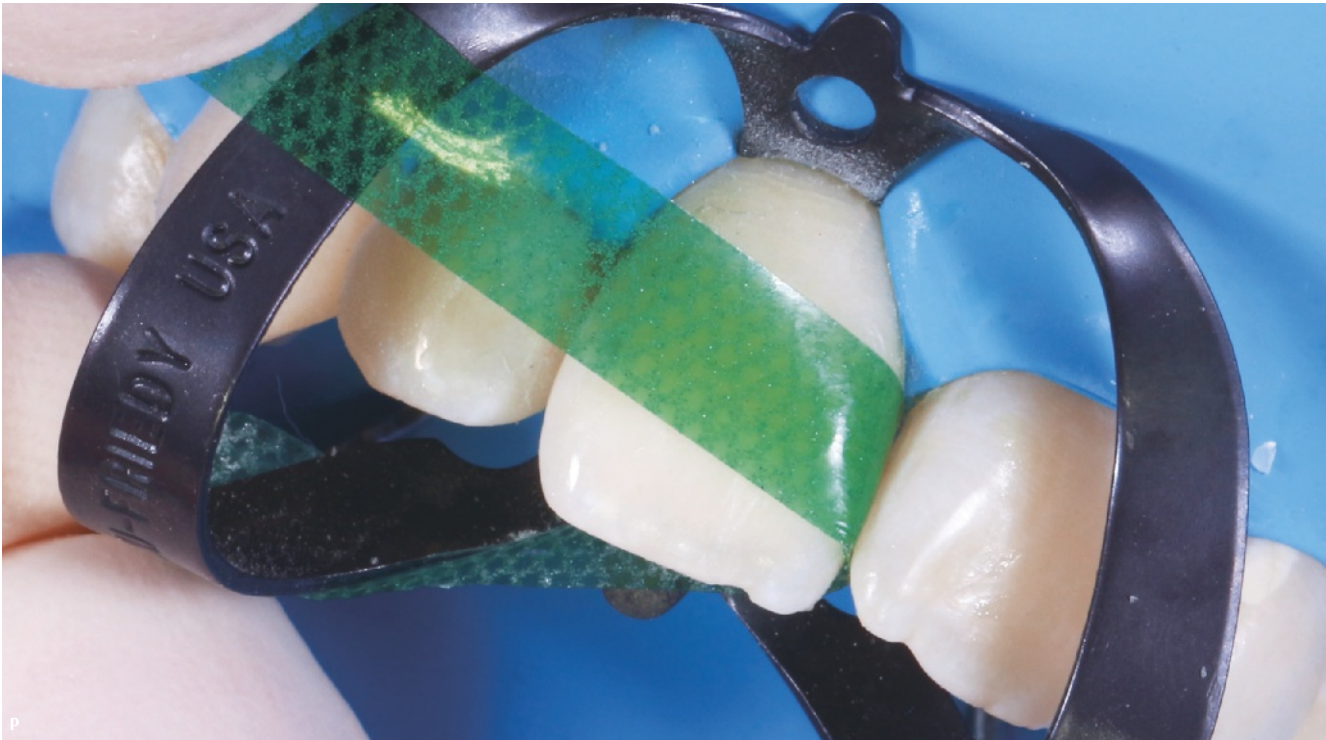
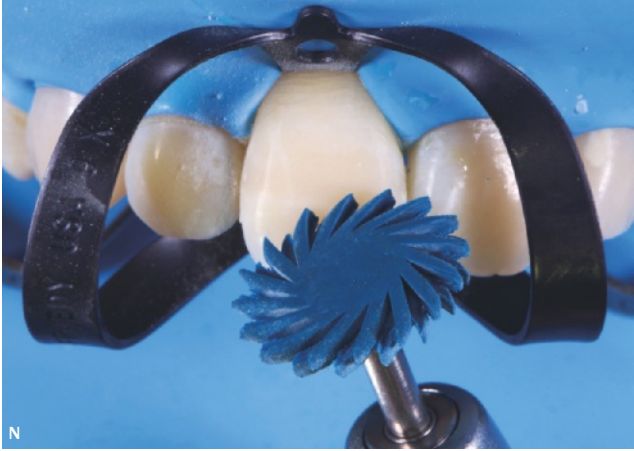
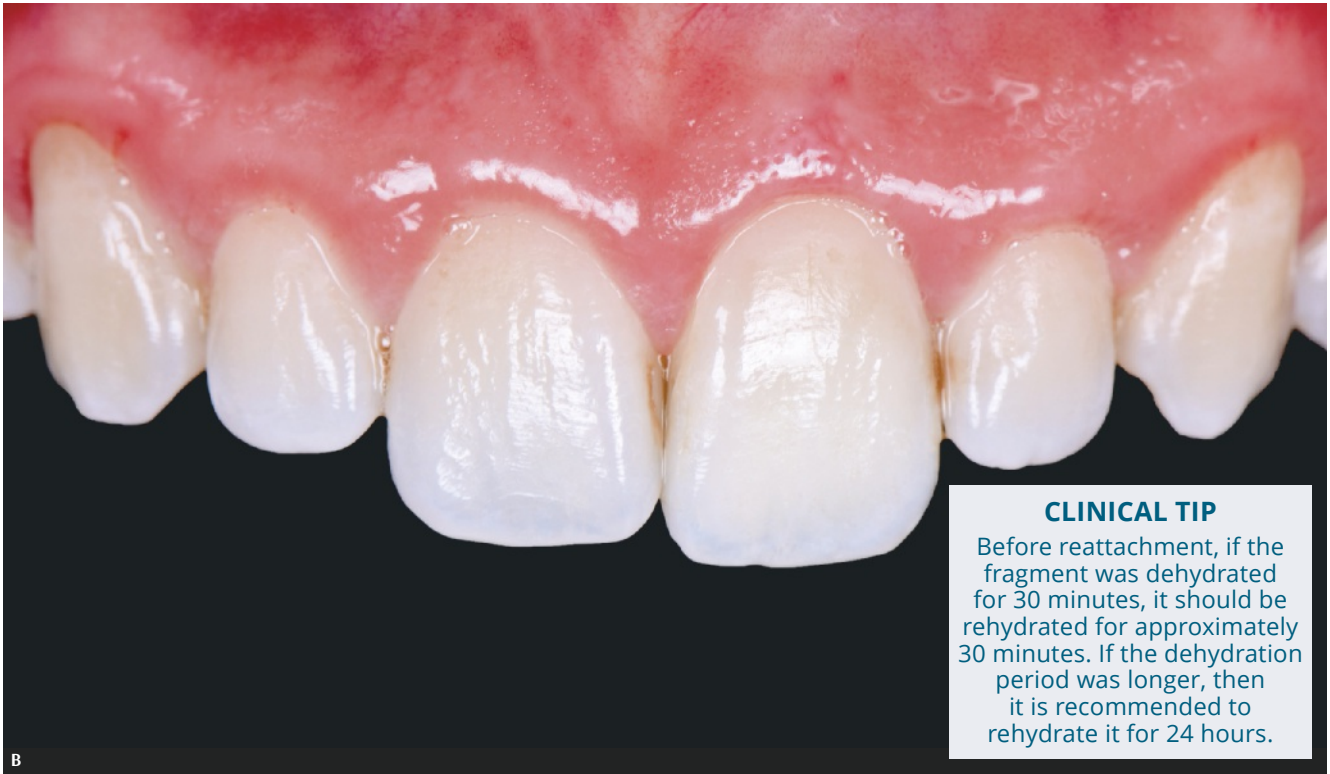
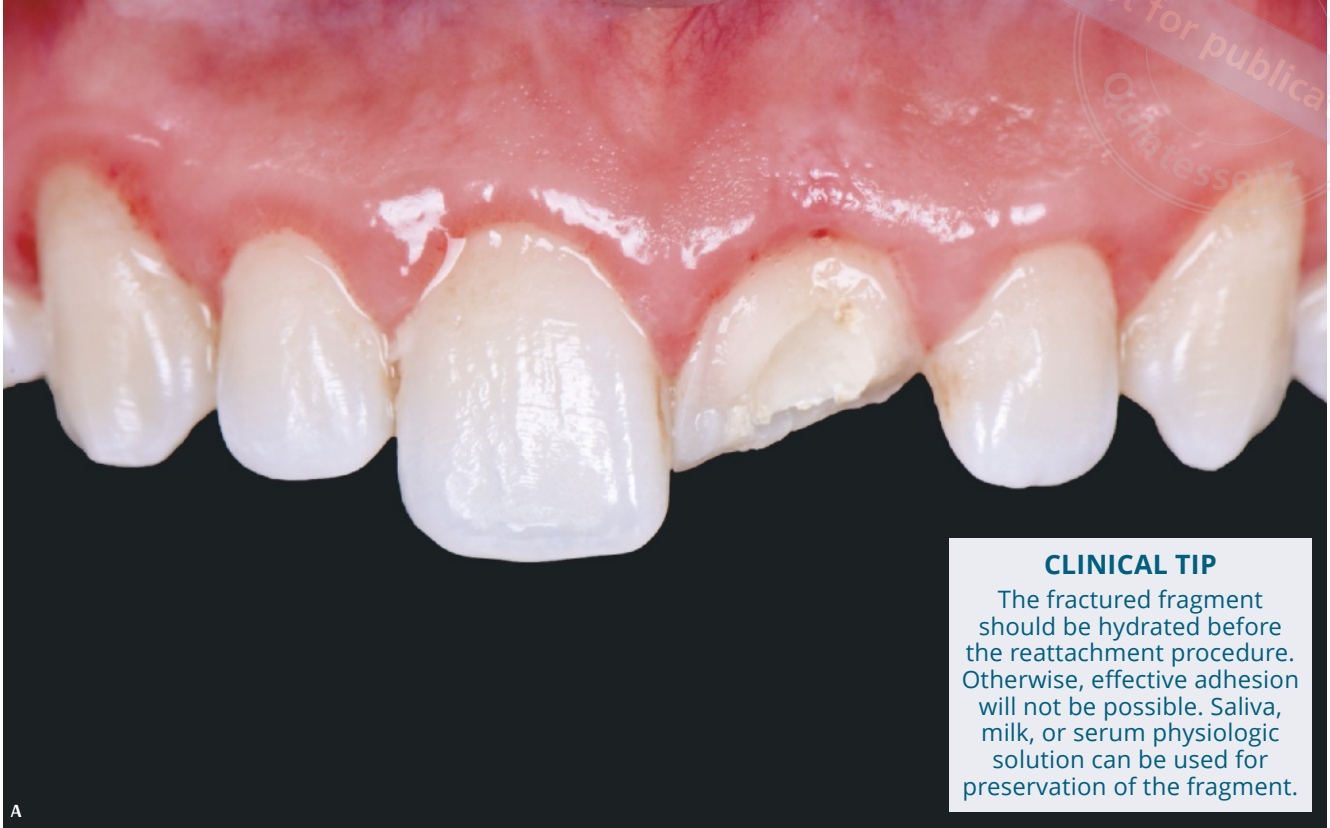


Fig 9-10 (A,B) Before and after deep reattachment procedure.

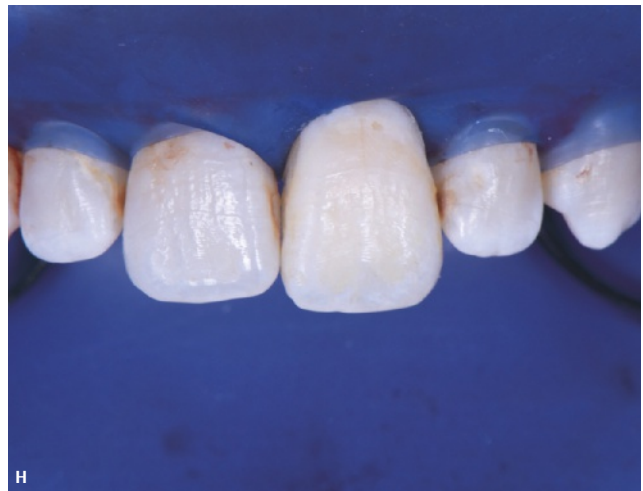
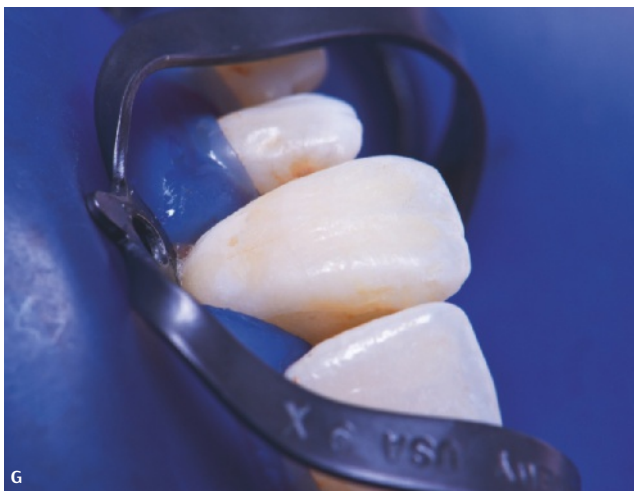
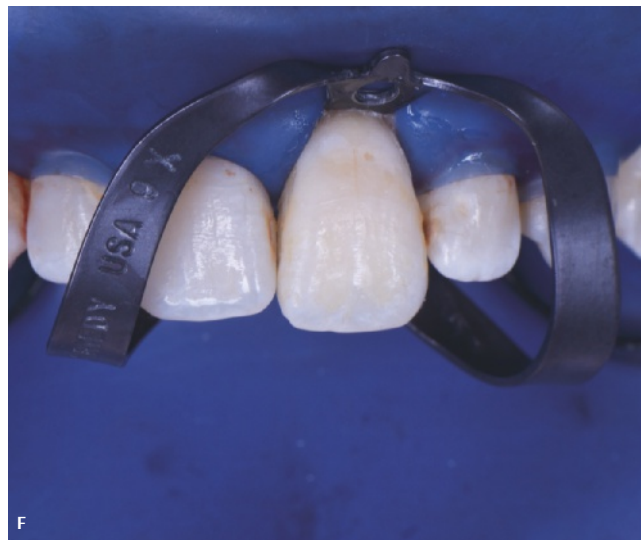
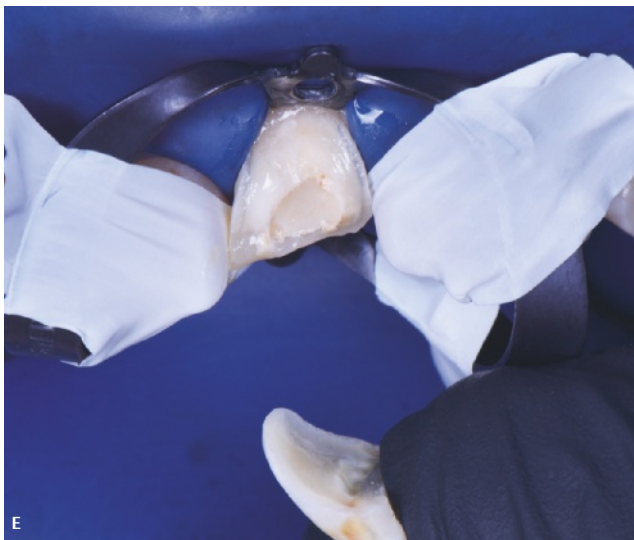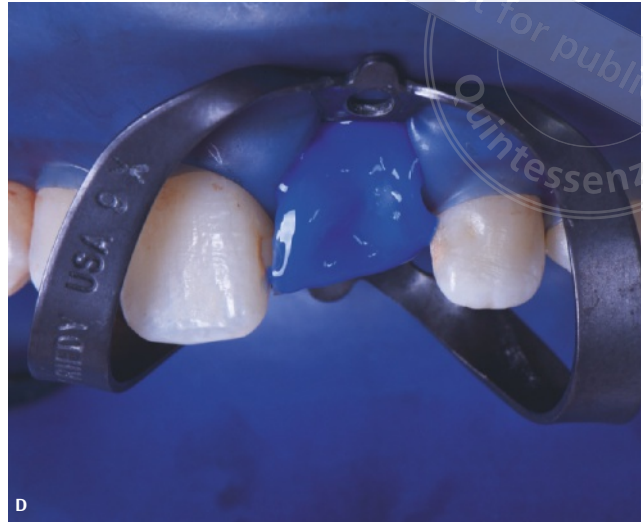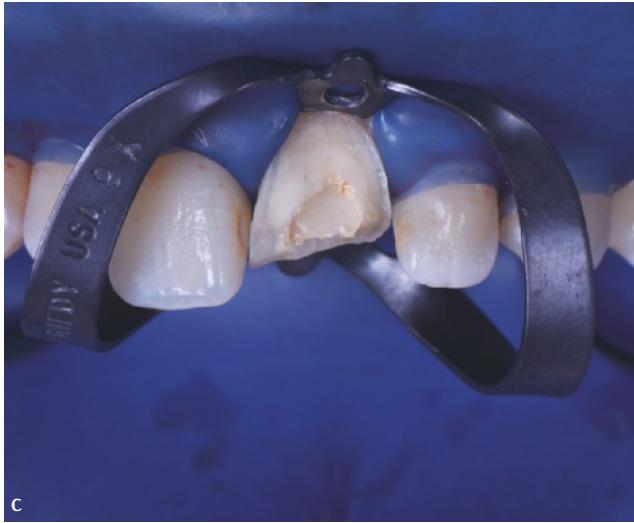Fig 9-10 (C) Crown fracture encompassing the entire vestibular surface. (D) Isolation and the adhesive protocol. (E) Reattachment of the fragment with flowable composite. (F,G) Surface polishing. (H) Final.



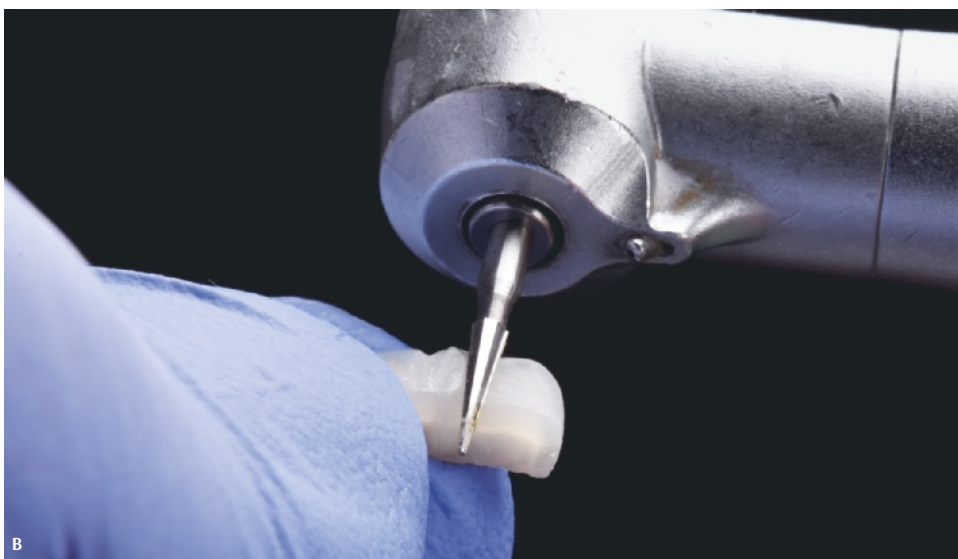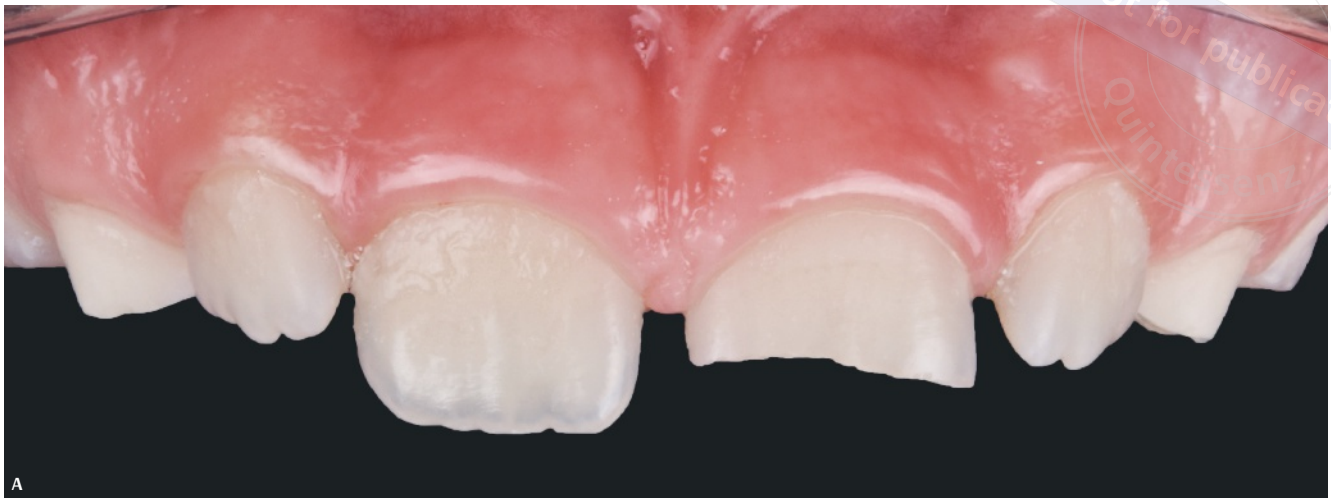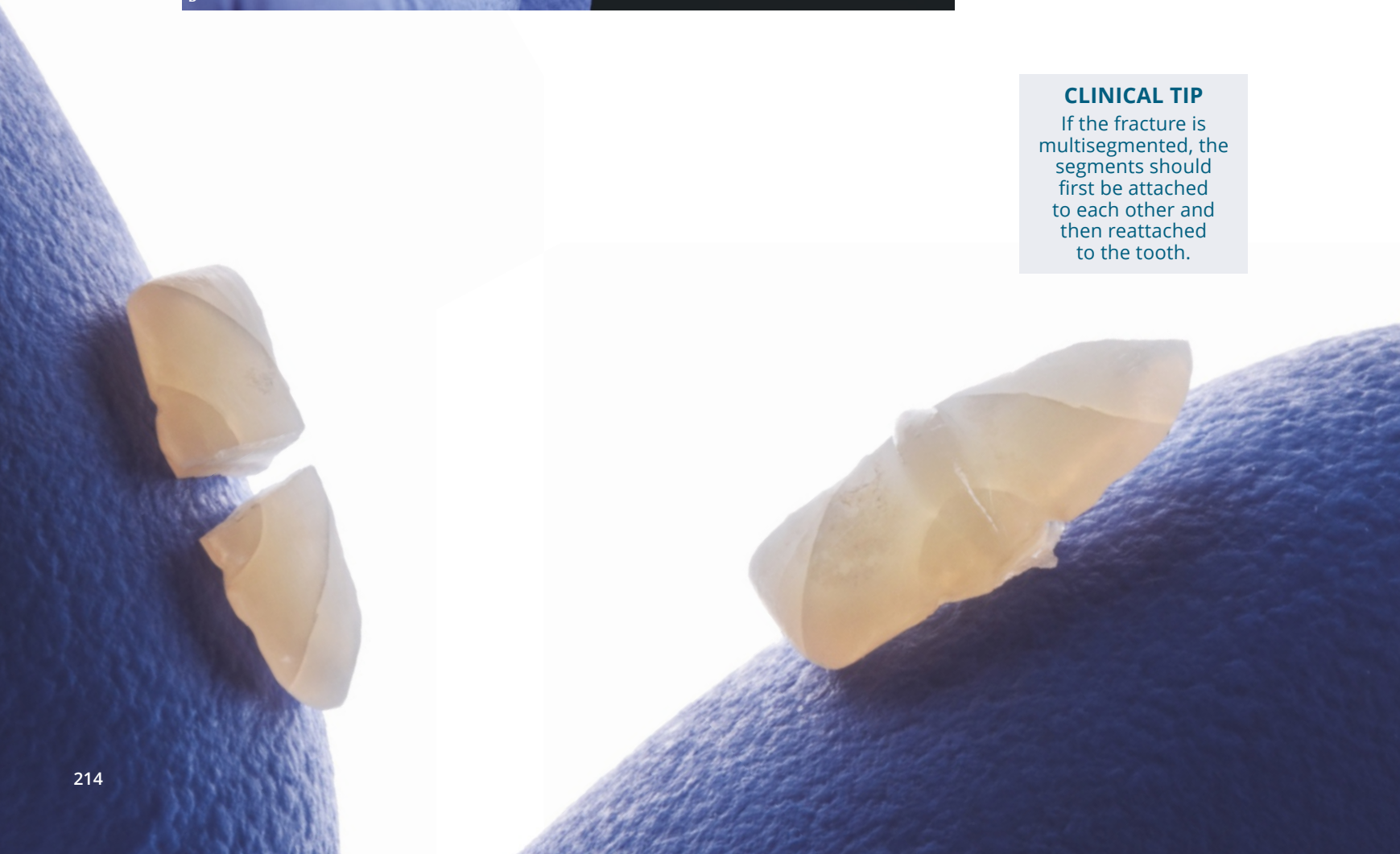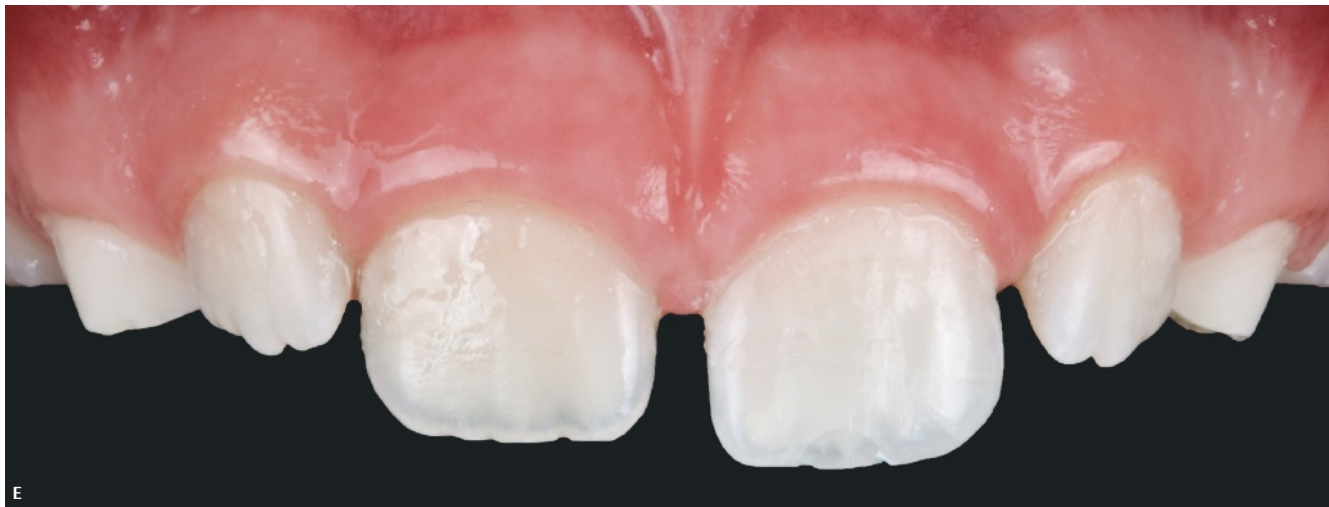
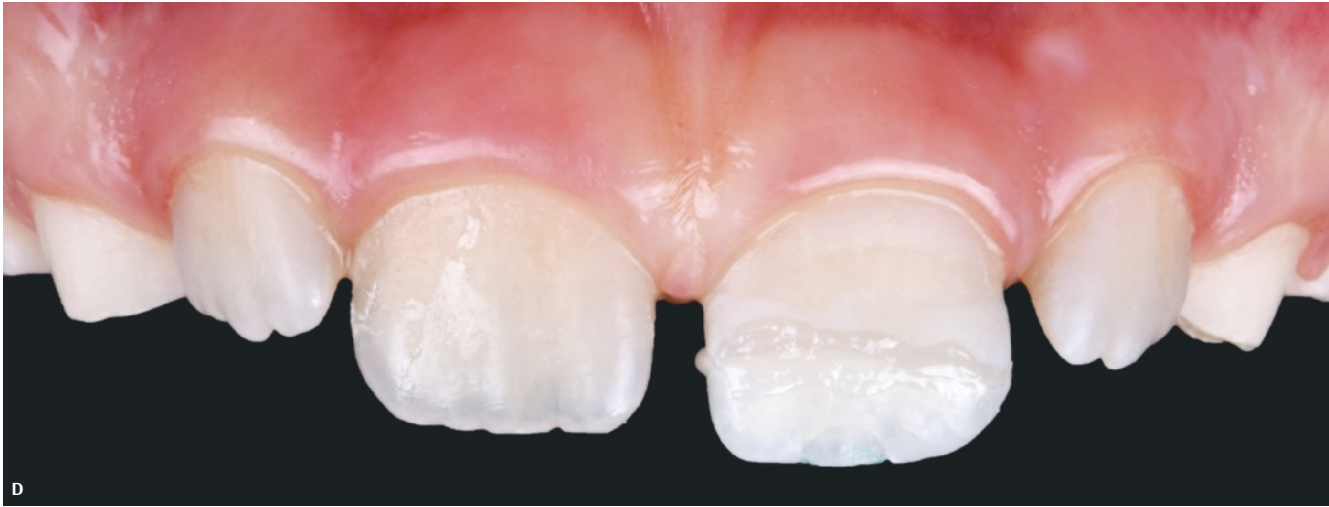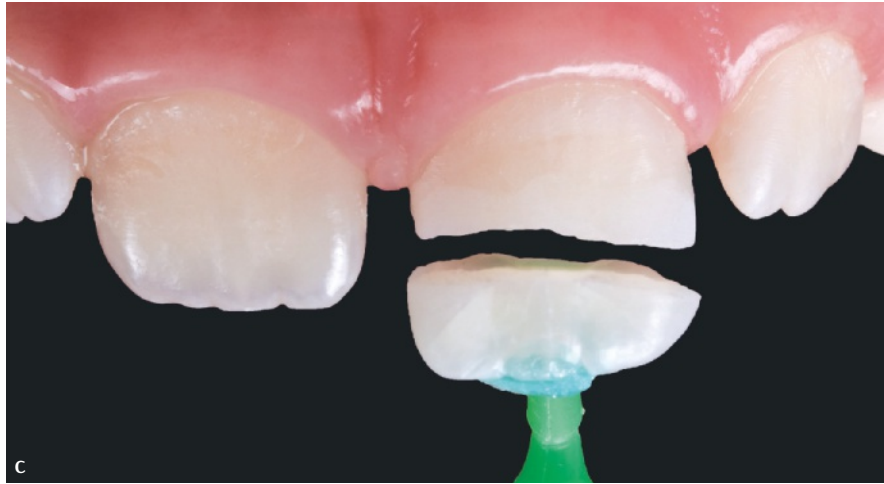
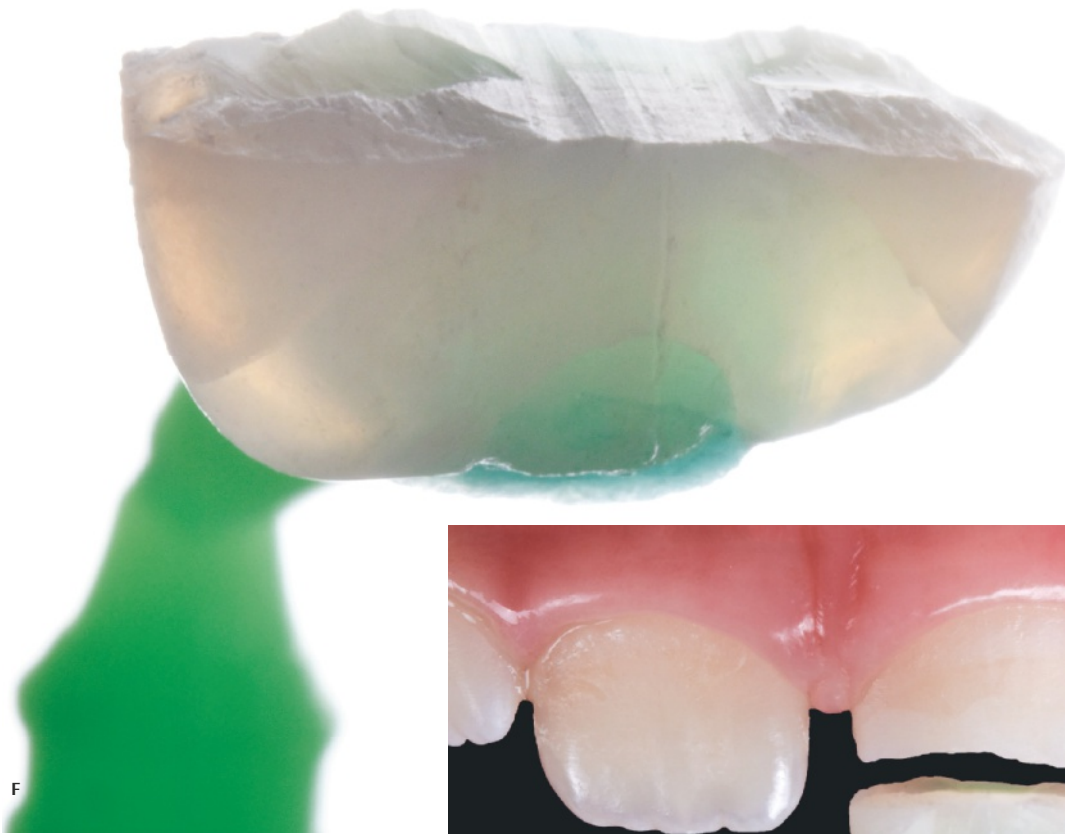


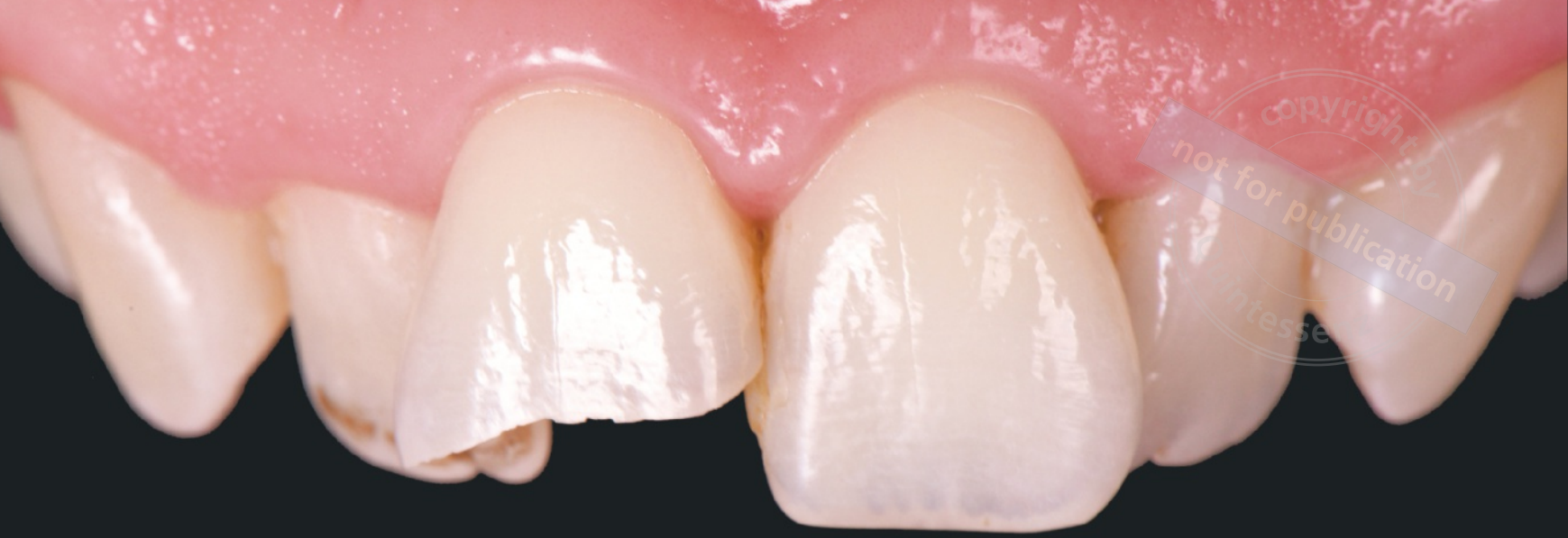Fig 9-11 (A-H) Clinical steps for the re-attachment protocol of a multisegmented fracture.

CLINICAL TIP

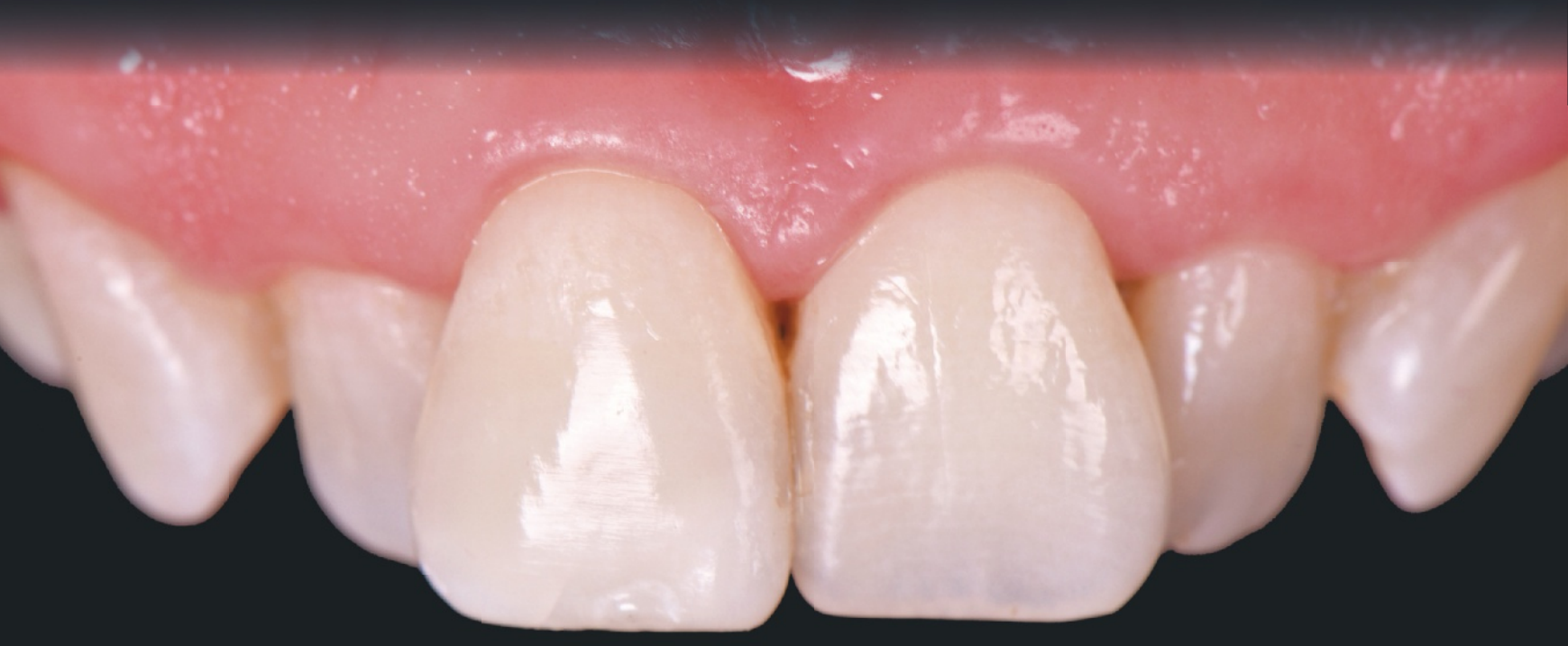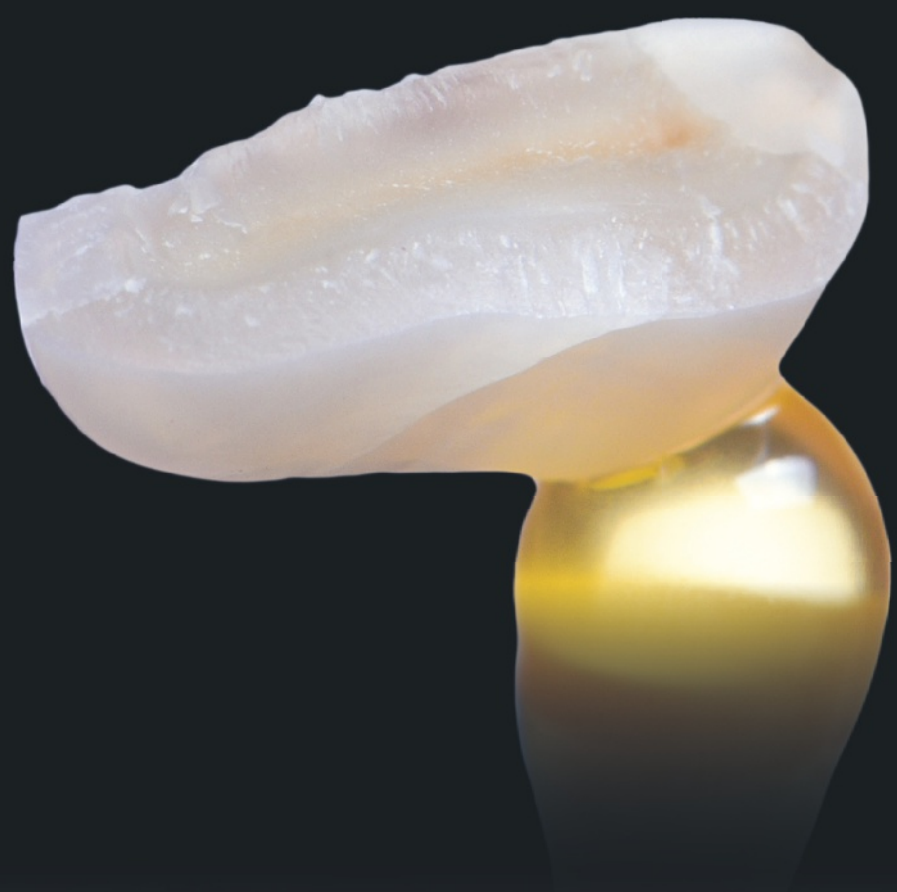If the fracture is multisegmented, the segments should first be attached to each other and then reattached to the tooth.





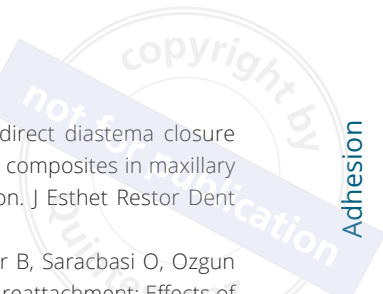


copyright ©
not for publication
Intesse



REFERENCES

1. Ahmed MH, De Munck J, Van Landuyt K, Peumans M, Yoshihara K, Van Meerbeek B. Do universal adhesives benefit from an extra bonding layer? *J Adhes Dent* 2019;21:117–132.
2. Bissinger R, Müller DD, Hickel R, Kühnisch J. Survival analysis of adhesive reattachments in permanent teeth with crown fractures after dental trauma. *Dent Traumatol* 2021;37:208–214.
3. Cuevas-Suarez CE, de Oliveira da Rosa WL, Lund RG, da Silva AF, Piva E. Bonding performance of universal adhesives: An updated systematic review and meta-analysis. *J Adhes Dent* 2019;21:7–26.
4. Da Rosa WLDO, Piva E, da Silva AF. Bond strength of universal adhesives: A systematic review and meta-analysis. *J Dent* 2015;43:765–776.
5. De Paris Matos T, Perdigo J, De Paula E, et al. Five-year clinical evaluation of a universal adhesive: A randomized double-blind trial. *Dent Mater* 2020;36:1474–1485.
6. Hardan L, Bourgi R, Kharouf N, et al. Bond strength of universal adhesive to dentin: A systematic review and meta-analysis. *Polymers* 2021;13:814.
7. Heintze SD, Rousson V, Hickel R. Clinical effectiveness of direct anterior restorations--A meta-analysis. *Dent Mater* 2015; 31:481–495.
8. Kanzow P, Wiegand A. Retrospective analysis on the repair vs replacement of composite restorations. *Dent Mater* 2020; 36:108–118.
9. Korkut B, Türkmen C. Longevity of direct diastema closure and recontouring restorations with resin composites in maxillary anterior teeth: A 4-year clinical evaluation. *J Esthet Restor Dent* 2021;33:590–604.
10. Pusman E, Cehreli ZC, Altay N, Unver B, Saracbası O, Ozgun G. Fracture resistance of tooth fragment reattachment: Effects of different preparation techniques and adhesive materials. *Dent Traumatol* 2010;26:9–15.
11. Suda S, Tsujimoto A, Barkmeier WW, et al. Comparison of enamel bond fatigue durability between universal adhesives and two-step self-etch adhesives: Effect of phosphoric acid pre-etching. *Dent Mater* 2018;37:244–255.
12. Van de Sande FH, Moraes RR, Elias RV, et al. Is composite repair suitable for anterior restorations? A long-term practice-based clinical study. *Clin Oral Investig* 2019;23:2795–2803.
13. Shirani F, Malekipour MR, Manesh VS, Aghaei F. Hydration and dehydration periods of crown fragments prior to reattachment. *Oper Dent* 2012;37:501–508.
14. Korkut B, Ozcan M. Longevity of direct resin composite restorations in maxillary anterior crown fractures: A 4-year clinical evaluation. *Oper Dent* 2022;47:138–148.
15. Korkut B. Resin composite restorations in anterior aesthetics. In: Kulak Ozkan Y, Aslan U (eds). *Smile Aesthetics and Lamina Veneer Restorations*. Quintessence Publishing Turkey, 2022:172–192.
16. Korkut B, Unal T, Can E. Two-year retrospective evaluation of monoshade universal composites in direct veneer and diastema closure restorations. *J Esthet Restor Dent* 2023;35:525–537.



copyright by
not for publication
Quintessenz

