

FRANCESCO CAIRO



PERIO ESTHETICS

ESTHETIC AND RECONSTRUCTIVE PERIODONTAL AND PERI-IMPLANT SURGERY

First published as:

Perio Aesthetics - Chirurgia estetica e ricostruttiva parodontale e peri-implantare.
Quintessence Publishing Italia, 2026.



ISBN: 978-88-7492-224-6



Copyright © 2026 Quintessenza Edizioni, Milano

Quintessenza Edizioni S.r.l.
Via Dante Alighieri, 18 - 20017 Rho (MI) Italy
Tel.: +39.02.93.18.08.21
E-mail: info@quintessenzaedizioni.it
www.quintessenzaedizioni.com

Editing of the English translation: Alexandra Rendón DDS MSc

All rights reserved. This book or any part thereof may not be reproduced, stored in a retrieval system, or transmitted in any form or by any means, electronic, mechanical, photocopying, or otherwise, without prior written permission of the publisher.

Printed by Caratteri Mobili srl - Figino Serenza (Como, Italy)



"Quintessence Publishing Group, in its commitment to protecting the environment and the world's forest heritage, has made an effort to use paper sourced from certified mills and supply chains. The paper certification ensures that the product comes from a responsibly managed forest and supply chain."



To Vincenzo, my Dad



Foreword Mariano Sanz	IX
Foreword Giovan Paolo Pini Prato	X
Foreword Maurizio Tonetti	XI
Preface	XII
Curricula	XIII
Acknowledgements	XIX
Video Index	XX

1 PERIODONTAL AND PERI-IMPLANT ANATOMY. HEALTHY CONDITIONS AT TEETH AND IMPLANTS 2

Authors:
F. Cairo,
M. Di Martino,
A. Bandel, D. Laforana,
M. De Sanctis

Introduction	4
Gingiva	7
Histology of the dento-gingival unit	8
Connective tissue	11
Periodontal ligament	15
Root cementum	16
Bone	18
Microscopic anatomy	18
Biological width	20
Periodontal phenotypes	23
Periodontal blood supply	26
Periodontal innervation	26
Definition of healthy periodontal conditions	26
Peri-implant mucosa	28
Osseointegration process	31
Structure and composition	31
Vascularization	31

2 CONCEPTS OF PERIODONTAL PATHOLOGY AND THERAPY. SURGICAL PRINCIPLES 34

Authors:
F. Cairo, M. Di Martino,
A. Bandel

Gingivitis and mucositis	36
Periodontitis and peri-implantitis	38
Effect of nonsurgical therapy in the treatment of periodontitis	45
Principles of surgical treatment	51
Surgical instruments and suture materials	51
Incision patterns and flap thickness in periodontal surgery	57
Primary intention healing and wound stability	67
Healing of the surgical wounds	67
Systemic factors affecting periodontal tissue healing	70

3 GINGIVAL AUGMENTATION AROUND TEETH 74

Author:
F. Cairo

Introduction, historical perspective, and current indications for gingival augmentation	76
Gingival augmentation procedures	82
Bone denudation and/or periosteal exposure	82
Epithelialized free gingival graft	84
Connective tissue graft for gingival augmentation	88
Biomaterials for gingival augmentation	106
Conclusions	107

4

HARVESTING PALATAL GRAFTS

108

*Authors:**F. Cairo, M. Di Martino,
C. Della Via*

Introduction and clinical indications	110
Epithelialized free gingival graft	110
Connective tissue graft	110
The palatal mucosa	112
Donor area anatomy	112
Neurovascular considerations	113
Histological and histo-morphometric analysis	115
Palatal wound healing	118
Biological and genetic aspects of primary and secondary intention healing	119
Harvesting techniques	120
Trap door technique	120
Parallel incisions technique	121
Single-incision technique	123
L-incision technique	124
The free gingival graft harvesting technique	128
Maxillary tuberosity grafting technique	134
Patient morbidity and complications	138
Selecting the graft harvesting area	140
Therapeutic outcomes	141

5

PERIODONTAL PLASTIC SURGERY FOR SINGLE RECESSIONS

144

*Authors:**F. Cairo, C. Rupe*

Etiology, diagnosis, and classification of gingival recession	146
Clinical and esthetic objectives of root coverage treatment	151
Prognostic factors for root coverage	155
Patient-related factors	155
Tooth-related factors	155
Treatment factors	156
Surgical techniques for root coverage	157
Coronally advanced flap	157
Coronally advanced flap and connective tissue graft	172
Coronally advanced flap with biomaterials	185
CEJ reconstruction and root coverage	188
Other root coverage techniques	196
Laterally positioned flap and connective tissue graft	196
Other techniques	200
Histological healing after root coverage	202
Clinical outcomes and long-term stability	203

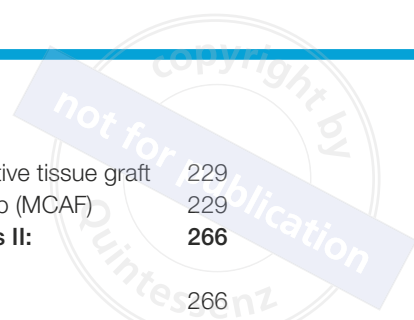
6

PERIODONTAL PLASTIC SURGERY FOR MULTIPLE RECESSIONS

206

*Authors:**F. Cairo, A. Bandel*

Introduction	208
Surgical procedures for the treatment of multiple recessions I: the multiple coronally advanced flap and its combinations	209
Multiple coronally advanced flap with vertical releasing incisions	209
Multiple coronally advanced flap without vertical releasing incisions (MCAF)	213
Multiple coronally advanced flap with connective tissue graft	219



Multiple coronally advanced flap with selective use of connective tissue graft	229
Surgical modifications of the coronally advanced envelope flap (MCAF)	229
Surgical procedures for the treatment of multiple recessions II:	266
tunnel techniques	
Traditional tunnel technique (Zabalegui Technique)	266
Modified coronally advanced tunnel technique	266
Laterally closed modified tunnel	268
Mixed tunnel with coronally advanced flap approach	268
Conclusions and selection of surgical technique	269

7 CLINICAL CROWN LENGTHENING IN THE ESTHETIC ZONE AND GUMMY SMILE TREATMENT 282

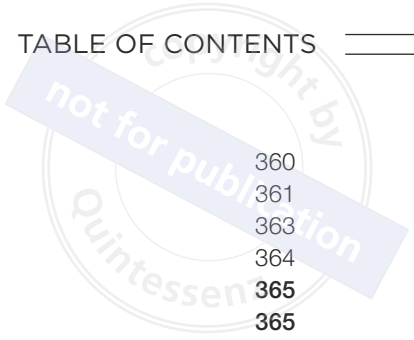
Authors:
F. Cairo, W. Castelluzzo

Clinical crown lengthening in the esthetic zone	284
Indications	284
Concept of biological dimension	284
Clinical crown lengthening	286
Crown lengthening and related rationale in the esthetic area	292
Altered passive eruption and gummy smile	305
Diagnosis of a gummy smile	307
Treatment of altered passive eruption	308
Gingivectomy	308
Apically positioned flap	312

8 REGENERATIVE PERIODONTAL SURGERY 338

Authors:
F. Cairo, M. Di Martino

Biological principles of periodontal regeneration	340
Outcomes of periodontal wound healing	341
Patient-related factors	343
Plaque control	343
Cigarette smoking	343
Uncontrolled diabetes	343
Local factors in periodontal regeneration	344
Classification of osseous defects	344
Defect location	347
Tooth mobility	347
Endodontic conditions	348
Indications for regenerative therapy	350
Suprabony defects	350
Infrabony defects	350
Furcation defects	350
Surgical procedures	352
Hard tissue defect morphology	352
Soft tissue morphology	353
Pre-surgical defect management	354
Surgical technique	355
Papilla preservation techniques	355
Flap design	356
Entire papilla preservation technique	357
Extended flap	358
Coronally advanced flap	358



Connective tissue wall technique	360
Non-incised papilla surgical approach (NIPSA)	361
Sutures	363
Application of biomaterials	364
Bone grafts	365
Biologic products	365
Selection of regenerative procedure according to defect type	367
Clinical application of periodontal regeneration	368
Treatment outcomes and long-term stability	368

9

TREATMENT STRATEGIES FOR EDENTULOUS RIDGE RECONSTRUCTION AND IMPLANT-PROSTHETIC THERAPY IN THE ESTHETIC ZONE 412

Authors:
F. Cairo, C. Rupe,
L. Barbato, R. Cavalcanti,
P. Venezia

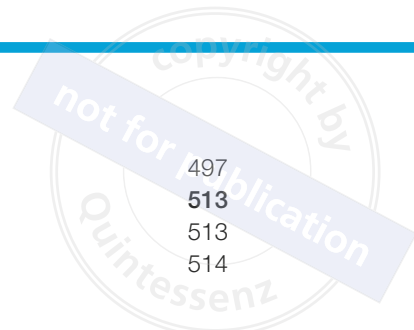
Esthetic and functional soft tissues problems after tooth extraction	414
Classification of ridge defects	416
Reconstruction of the edentulous ridge through soft-tissue augmentation	418
Onlay graft	418
Roll flap technique	418
Inlay graft	419
Combined onlay-inlay grafts	419
Envelope procedure and connective tissue graft	420
Connective tissue platform technique	420
Prosthetic soft-tissue conditioning of the edentulous ridge	424
Rationale for implant therapy in the esthetic area	436
Timing for implant placement in the esthetic zone	442
Immediate implant placement (type 1)	442
Early implant placement with soft tissue healing (type 2)	458
Early implant placement with partial bone healing (type 3)	458
Delayed implant placement (type 4)	458

10

HARD TISSUE RECONSTRUCTION AROUND DENTAL IMPLANTS 464

Authors:
F. Cairo, C. Rupe,
L. Barbato, R. Cavalcanti,
P. Venezia

Introduction	466
Healing of the alveolar socket	466
Dimensional changes after tooth extraction	467
Characteristics of the edentulous ridge	468
Biology of bone regeneration	470
Alveolar ridge preservation (ARP)	471
Rationale for ARP	471
ARP techniques	471
Evidence-based outcomes	471
Lateral bone regeneration	484
Introduction	484
Basic concepts of guided bone regeneration (GBR)	484
Surgical procedure	484
Biomaterials for GBR membranes	485
Evidence-based results	486
Complications	487
Other techniques for lateral bone augmentation	487
Vertical guided bone regeneration	496
Introduction	496



Evidence-based results	497
Maxillary sinus floor elevation	513
Lateral maxillary sinus floor elevation	513
Transalveolar maxillary sinus floor elevation	514



Authors:
F. Cairo, W. Castelluzzo

SOFT TISSUE MANAGEMENT AROUND DENTAL IMPLANTS	528
Clinical relevance of peri-implant soft tissues	530
Peri-implant tissues and esthetics	533
Clinical evaluation of peri-implant tissues	535
Soft tissue augmentation techniques	535
Soft tissue augmentation techniques prior to implant placement	536
Free gingival grafts	536
Alternatives to free gingival grafts – collagen matrices	536
Connective tissue graft techniques	537
Soft tissue augmentation at implant placement or uncovering	544
Apically repositioned flap	544
Free gingival grafts	544
Connective tissue grafts	544
Collagen matrices	545
Roll technique	545
Peri-implant papilla reconstruction	560
Coverage of peri-implant mucosal recessions	564
Peri-implant soft tissue conditioning and final prosthetic treatment	570
Finalization of complex esthetic cases	575



Author:
F. Cairo

POST-OPERATIVE PATIENT MANAGEMENT AND POSSIBLE COMPLICATIONS	598
Pain management: anti-inflammatory drugs	600
Cortisone-based medications	600
Bleeding management	600
Antibiotics	601
Suture removal	601
Post-operative hygiene	601
Post-operative indications list	601
Complications	602
Intra-surgical complications	602
Infectious complications	602
Traumatic post-surgical complications	602

Foreword

Historically, dentistry has been considered a profession combining science and art, in which the balance of impact on clinical practice between new knowledge, professional skills, and the use of new technologies and tools has more often tilted toward human factors rather than scientific advances. This has been particularly true in interventions aimed at rehabilitating the esthetics and function rather than arresting or curing the diseases affecting the oral cavity. However, over the past decades, significant advances in our understanding of tissue biology, wound healing, and regenerative principles have expanded our ability to develop predictable therapies for managing soft- and hard-tissue deficiencies around teeth and dental implants. These advances have evolved alongside the rise of periodontal and periimplant plastic surgery, offering clinicians unprecedented opportunities to restore both function and esthetics in their patients.

This book provides a structured, evidence-based overview of contemporary periodontal and peri-implant plastic and regenerative surgery, with particular emphasis on treatment in the esthetic area. It provides a comprehensive synthesis of current knowledge in periodontal and peri-implant plastic surgery, grounded in evidence-based principles and enriched by decades of clinical experience. From the fundamental understanding of periodontal anatomy and health to advanced reconstructive procedures, each chapter has been meticulously crafted to provide clinicians with both theoretical foundations and practical guidance for managing the most challenging clinical scenarios. Each surgical technique is supported by current evidence

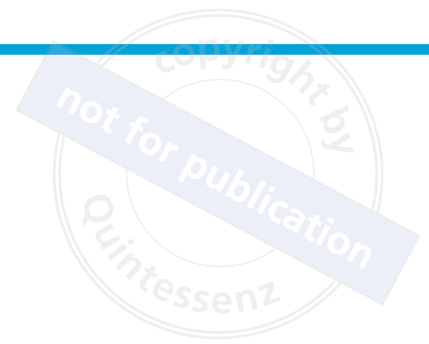and illustrated with clinical cases that demonstrate both the potential and the limitations of various approaches. Special attention has been devoted to soft tissue management, integrating minimally invasive approaches and advanced biomaterials to improve our ability to reconstruct lost periodontal and peri-implant tissues and to recognize their critical importance in achieving optimal functional and esthetic outcomes.

The final chapters acknowledge the reality of contemporary practice, where implant dentistry has become integral to comprehensive treatment planning. The timing of implant placement, ridge augmentation techniques, and management of peri-implant soft tissues are explored in depth, providing clinicians with the knowledge necessary to achieve predictable, long-term success.

This book is intended for periodontal specialists, oral surgeons, general dentists with an interest in advanced periodontal procedures, and dental students seeking to deepen their understanding of periodontal and peri-implant plastic surgery. While some procedures require advanced training and experience, we believe that understanding the principles underlying these techniques will benefit all clinicians who care for patients with periodontal and peri-implant needs.

I am confident this work will contribute to excellence in periodontal and peri-implant care, and ultimately to improved oral health and quality of life for the patients we serve.

Mariano Sanz
Professor of Periodontology
University Complutense of Madrid (Spain)



Foreword

The publication of this volume, “Perio Esthetics, Esthetic and Reconstructive Periodontal and Peri-Implant Surgery,” conceived and written by Professor Francesco Cairo and his colleagues, enriches the cultural landscape of a highly sophisticated and unique surgical specialty: esthetic periodontal and peri-implant surgery.

It is a remarkably structured book, with approximately 650 pages, 11 chapters, and over 2,100 high-quality images. The text is complemented, in a new and modern editorial approach, by 34 videos of surgical procedures performed using an operating microscope.

The various chapters, starting from the essential knowledge of the pathophysiology of anatomical structures, illustrate lesions of the soft and hard tissues of the jaws and propose, based on solid scientific evidence, precise indications for regenerative/ reconstructive treatments around teeth and implants.

The surgical techniques, described step-by-step in detail and illustrated with beautiful photographs and videos, provide to the reader a truly refined guide. Of particular interest is the appendix, which discusses patient management in the postoperative period, including potential immediate and late complications of treatment.

The clinical and scientific message conveyed by the author is very clear, concise, and incisive. The beautiful iconography, combined with the availability of videos, facilitates understanding of all the

surgical techniques proposed. The text, due to the sophistication and completeness of the technical indications, is aimed not only at all specialists already expert in the field who wish to improve their knowledge and clinical performance in periodontal and peri-implant plastic surgery, but is also indispensable for young graduates who wish to embark on a responsible journey in this magnificent and fascinating specialty.

Therefore, this comprehensive work demonstrates not only the recognized and personal scientific value of Prof Francesco Cairo, but above all his passionate work as a University Professor, which has received great international recognition through the establishment of a European School of Periodontology and Implantology at the University of Florence.

Sincere congratulations also to Quintessence, who chose to present the book in a very refined and modern editorial version. To Professor Francesco Cairo and his diligent collaborators, we wish a great and well-deserved success, which will surely repay the enormous effort and commitment in creating this beautiful work.

Giovan Paolo Pini Prato
Full Professor of Periodontology
Universities of Siena and Firenze (Italy)
President of SIdP 1993-95

Foreword

It is with great pleasure and pride that I present Prof Francesco Cairo's book on esthetic and reconstructive periodontal and implant surgery. Among the plethora of books on this topic, this text stands out because it masterfully combines three aspects that I believe are fundamental to our clinical practice:

- Italian clinical excellence as a method.
- Scientific evidence as a compass.
- Ethics as a central value of clinical practice.

Prof Cairo embodies these three elements with his personal history as a clinician, researcher, and teacher, trained within one of Europe's most renowned schools: that of his teacher, mentor, and friend, Prof Giovan Paolo Pini Prato, and within the broader context that Florence has held as a privileged place for clinical and scientific innovation in periodontology. Francesco is a product of what has been called the Italian Renaissance of Periodontology and is today one of its most illustrious representatives. Over the years, I've had the pleasure and honor of sharing part of his growth journey, and I've found a sincere friend whom I admire.

I read the book with curiosity and attention, drawing useful insights. Methodologically, the book aims to support the clinician who reads it in doing the right things well. The extensive photographic iconography, accompanied by over 30 videos, guides and inspires operational excellence, a truly

fundamental aspect of esthetic and reconstructive surgery. Beyond the "how," the clinical and scientific knowledge nuggets help in making operational decisions in terms of "if," "what," and "when," focusing on the appropriateness of the procedure and the essential dimension of patient benefits: the "why."

If you embark on a path of professional development in this field, the logical and systematic approach will be useful in supporting your growth, stimulating your interests, and nurturing your aspirations.

If you're already an expert, this book is a useful resource for comparison and refresher courses, packed with important details and truly helpful suggestions, and in some ways a challenge to measure yourself against.

For all of us, this book is an opportunity to reflect and evaluate our daily work and therefore a stimulus to continue on a path of growth.

With great affection, I would like to thank my friend Francesco for his efforts in this beautiful book, which is not just another of many, but a text that will surely earn a place in our practice libraries.

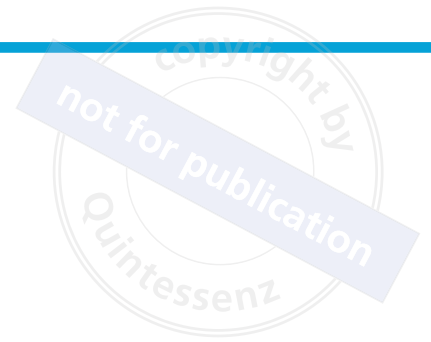Happy reading!

Maurizio Tonetti

Chair Professor, Shanghai Jiao Tong University
School of Medicine, Shanghai, China

Editor Journal of Clinical Periodontology 2007-22

Presidente SIdP 2014-15



Preface

For Alexander Baumgarten, an eighteenth-century German philosopher, esthetics “is the science of sensory knowledge.” The esthetic sense is not a simple individual inclination, but a profound cultural trait and defining identity. From the Renaissance onward, “beautiful” has taken on a value that goes far beyond the visual dimension: it has become an organizing principle of thought, a criterion of judgment, a form of relationship with the world. Likewise, the “reconstructive” approach of modern surgery has a radical and noble meaning: putting things back together like a craftsman, restoring their proper form and function, respecting the individual and their deepest needs.

The esthetics of the smile, in fact, is not merely a cosmetic factor, but an essential component of psychological and relational well-being. A healthy smile communicates health, confidence, openness, and vitality. And it is no coincidence that the modern periodontist today finds himself faced with the challenge of combining technical expertise with esthetic sensitivity.

These two souls, esthetic and reconstructive, are the deepest vocations of the book that I am pleased to present to you: “Perio Esthetics, Esthetic and Reconstructive Periodontal and Peri-Implant Surgery.” A long journey that has concluded today, as I write these few introductory words, but that began about five years ago. A highly ambitious

project: to attempt to share with the reader the cultural revolution in the world of Periodontology and Implantology over the last twenty years, under the banner of esthetic and reconstructive surgery. A revolution of which I have been a direct witness, but also an agitator and promoter, and which today allows young periodontists, dental specialists, or simply enthusiasts, to approach treatment in a modern and more comprehensive way: esthetic reconstruction not as a possible therapeutic option, but as an unavoidable and predictable necessity in daily clinical practice.

A journey that touches the principles of reconstructive surgery, single and multiple gingival recession surgery, gummy smile surgery, esthetic prosthetic treatment and regenerative periodontal surgery. And for implants, it covers implant placement procedures in the esthetic zone, hard tissue reconstruction techniques, and various soft tissue reconstruction procedures. A journey that I hope will instill in you passion for the quality of care and a constant sense of improving your skills. A journey that I hope will excite and ultimately hypnotize you, with the underlying idea that surgical treatment may help patients in restore also their own sense of harmony.

Happy reading!

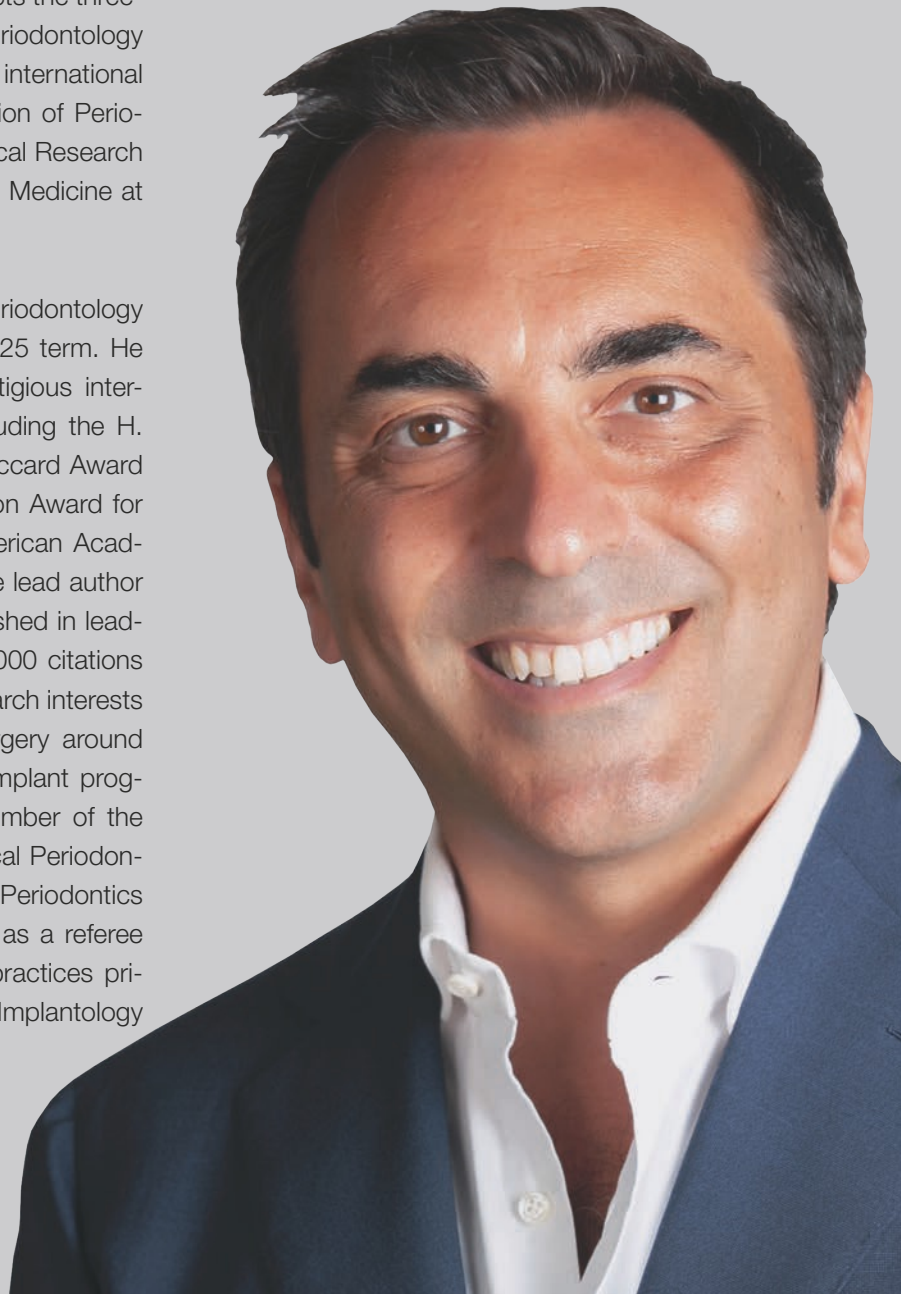Francesco

not for publication

Francesco Cairo

Professor of Periodontology at the University of Florence, Florence, Italy. Director of the Oral Surgery Specialty School. He founded and directs the three-year, full-time Master's Program in Periodontology and Implantology, accredited as an international school by the EFP (European Federation of Periodontology) in 2022. He heads the Clinical Research Unit in Periodontology and Periodontal Medicine at the same University of Florence.

President of the Italian Society of Periodontology and Implantology (SIdP) for the 2024-25 term. He has received some of the most prestigious international clinical research awards, including the H. Goldman Award from the SIdP, the Jaccard Award from the EFP, and the R. Earl Robinson Award for periodontal regeneration from the American Academy of Periodontology (AAP). He is the lead author or co-author of over 120 articles published in leading international journals, with over 6,000 citations and an H index of 43. His primary research interests include plastic and reconstructive surgery around teeth and implants, periodontal and implant prognosis and Periomedicine. He is a member of the editorial boards of the Journal of Clinical Periodontology and the International Journal of Periodontics and Restorative Dentistry, and serves as a referee for leading international journals. He practices privately, focusing on Periodontology and Implantology in his office in Florence.



(Photo: Piero Lazzari, www.pierolazzari.com)





Acknowledgements

The list of people I would like to thank is very long.

To Professor Giovan Paolo Pini Prato, my teacher and mentor, who instilled in me a passion for clinical research. I knew I wanted to be a University Professor the first time I attended one of his lectures.

To Maurizio Tonetti, my friend and role model, undoubtedly the greatest clinical researcher I have ever met.

To my wife Vania and my children Alessandro and Matteo, who are my world.

To my mother Assunta and my brother Paolo, but also to my dad Vincenzo, who are and always will be my roots.

To my colleagues in my daily work and all my students at the EFP Specialty School at the Florence University.

To Quintessenza Edizioni, especially Maria Grazia Monzeglio, Cristina Reina, and Alessio Buono, for the incredible support behind this book.

Thank you, thank you, thank you

Francesco



Video Index

Chapter 1

Video 1: Clinical examination of healthy periodontal tissues (p. 27)

Chapter 2

Video 1: Clinical examination in periodontitis (p. 38)

Chapter 3

Video 1: Free gingival graft (p. 96)

Video 2: Free gingival graft for retreatment (p. 97)

Chapter 4

Video 1: Connective tissue harvesting with the trap door technique (p. 121)

Video 2: Connective tissue harvesting with the linear incision technique (p. 123)

Video 3: Connective tissue harvesting with the L-incision technique (p. 128)

Video 4: Free gingival graft harvesting (p. 131)

Chapter 5

Video 1: Coronally advanced flap for single recession (p. 163)

Video 2: Coronally advanced flap with connective tissue graft for a single recession (p. 183)

Video 3: Coronally advanced flap with collagen matrix for a single recession (p. 187)

Video 4: Laterally positioned flap with connective tissue graft for a single recession (p. 199)

Chap. 6

Video 1: Coronally advanced flap with vertical incisions for multiple recessions (p. 212)

Video 2: Coronally advanced flap without vertical incisions with connective tissue graft for multiple recessions (p. 224)

Video 3: Coronally advanced flap with site-specific connective tissue graft for multiple recessions (p. 242)

Video 4: Coronally advanced flap with connective tissue graft for multiple recessions at the level of the lower premolars (p. 252)

Video 5: Coronally advanced flap with connective tissue graft for multiple recessions (p. 272)

Video 6: Coronally advanced flap with connective tissue graft for multiple recessions in a very demanding esthetic case (p. 279)

Chapter 7

Video 1: Osseous resective surgery for clinical crown lengthening in a prosthetic case on upper central incisors (p. 286)

Video 2: Osseous resective surgery for the treatment of gummy smile (p. 329)

Chapter 8

Video 1: Periodontal regeneration with a minimally invasive procedure and amelogenins (p. 371)

Video 2: Periodontal regeneration with a resorbable membrane and deproteinized bovine bone (p. 380)

Video 3: Periodontal regeneration in tooth with a compromised apex (p. 401)

Video 4: Periodontal regeneration in furcation defect at lower molar (p. 403)

Chapter 9

Video 1: Post-extractive implant with full-coverage using connective tissue graft (p. 447)

Video 2: Post- extractive implant with buccal connective tissue graft (p. 459)

Chapter 10

Video 1: Lateral guided bone regeneration (p. 491)

Video 2: Vertical guided bone regeneration (p. 499)

Video 3: Maxillary sinus lift procedure (p. 515)

Video 4: Repair of membrane perforation during maxillary sinus lift procedure (p. 520)

Chapter 11

Video 1: Post-extractive implant with lateral guided bone regeneration (GBR) (p. 562)

Video 2: Horizontal and vertical connective tissue graft after GBR (p. 563)

Video 3: Post-extractive implant with GBR (p. 571)

Video 4: Soft tissue augmentation with connective tissue graft during the second surgical phase (p. 571)

These anatomical findings require meticulous attention to achieve optimal results while minimizing risks and discomfort. In a classic cadaver study, Reiser et al (1996) studied the location of the palatine artery in relation to the CEJ of the premolars, demonstrating that the distance in high palates is 17 mm, in average palates 12 mm and in shallow palates only 7 mm (**Fig 7**).

Figures 8 to 10 show examples of identification on computerized tomography of the bony groove, through which the palatine artery runs, of the greater palatine canal and of the thickness of the palatine mucosa. Furthermore, **figure 11** presents a simulation of the position of the palatine artery according to the meta-analysis data of Tavelli et al, 2019.

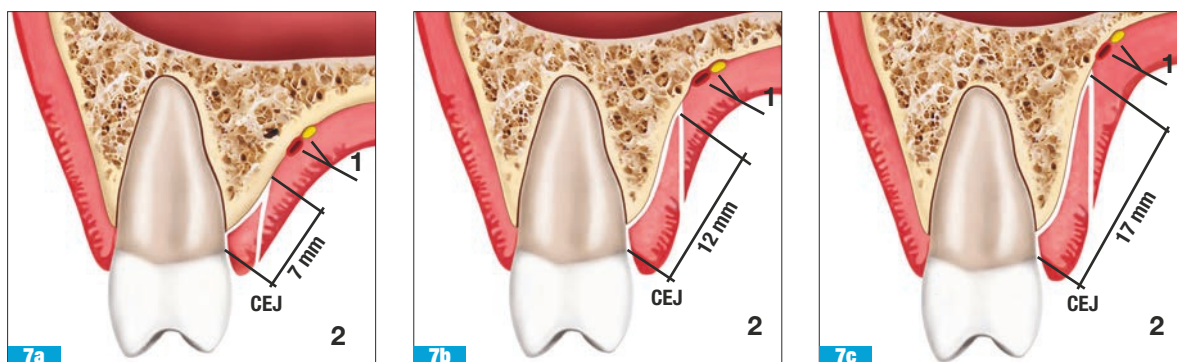
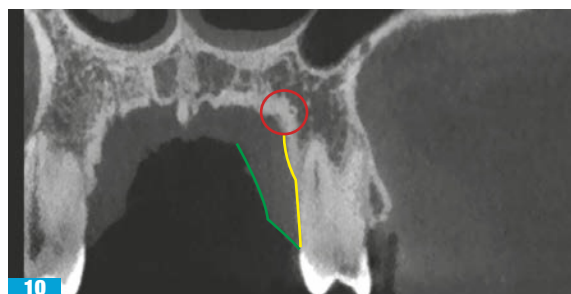


Fig 7 Schematic of the location of the palatine artery on **a)** the flat palate, **b)** the middle palate, and **c)** the deep palate, according to the study by Reiser et al, 1996.

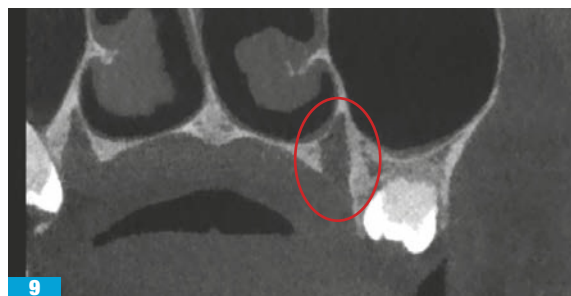
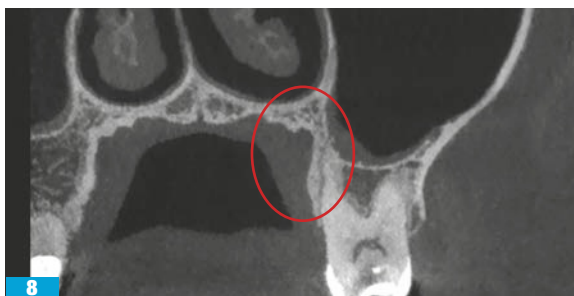
Fig 8 Location of the bony groove for the passage of the greater palatine artery apical to the palatine root of an upper second premolar (sagittal section of computed tomography). **Fig 9** Location of the greater palatine canal palatally between the impacted second molar and wisdom maxillary teeth (sagittal section of computed tomography).

Fig 10 Thickness of the palatine mucosa in a sagittal section of computed tomography. Apically, the bony groove for the passage of the palatine artery is outlined in red.



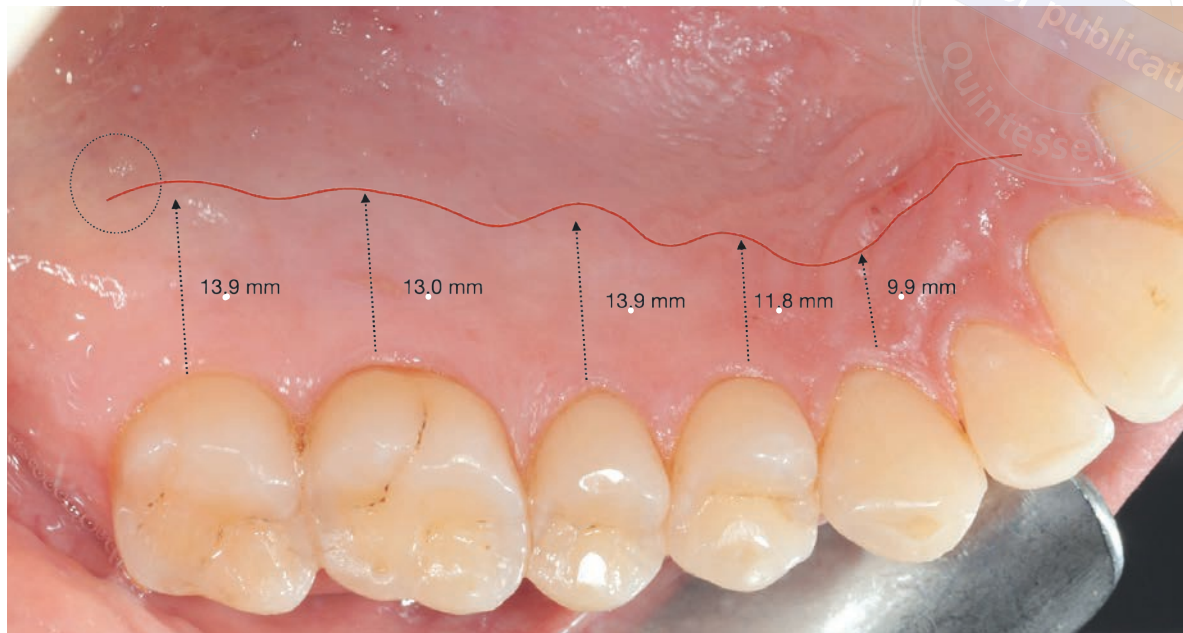


Fig 11 Simulation of the location of the greater palatine artery with respect to the palatine margin of the teeth, according to the meta-analysis by Tavelli et al, 2019. The circle indicates the probable location of the palatine artery exit from the greater palatine canal.

Histological and histo-morphometric analysis

Visual analysis of the palatal mucosa reveals significant changes in mid-distal progression (**Figs 12 to 14**). Histological analysis reveals that the palatal mucosa is composed of three primary layers: the epithelium, the lamina propria, and the submucosa (Harris et al, 2003).

Epithelium

This layer is characterized by ortho-keratinization and has a thickness of approximately 300 μm –600 μm (0.6 mm), corresponding to the gingival epithelium. It features a thick, ortho-keratinized squamous epithelium, with occasional areas of para-keratinized epithelium with nuclei retained in

the keratin scales. This layer provides protection against mechanical stress and microbial invasion.

Lamina propria (LP)

This is a layer of dense connective tissue. It contains a high percentage of intercellular substance, produced by fibroblasts, predominantly collagen fibers (primarily types I and II, and a few types V and VI), which are responsible for the mechanical properties of the palatal mucosa. The LP has finger-like projections (papillae) that interlock with the overlying epithelium, improving adhesion and ensuring that oxygen and nutrients reach the surface cells by diffusion. The LP is made up of two sublayers: a superficial papillary layer (PL) and a deep reticular layer (RL) (Garcia-Caballero et al, 2023).

L-incision technique

The L-incision technique offers an advanced approach to graft harvesting, allowing for a precise dissection of a split-thickness flap. This method allows for harvesting the graft after flap raising ensuring optimal control of flap thickness. Incorporating an anteriorly releasing L-incision, the technique improves visibility, allowing the clinician to work with greater precision when harvesting the connective tissue graft. One of the main advantages of this approach is its ability to maintain a minimal and predictable thickness of the overlying flap, while ensuring excellent control over the harvested subepithelial connective tissue graft, improving predictability and reducing donor site complications (Bhatavadekar & Gharpure, 2018). (Clinical case 1: Figs 25 to 36).

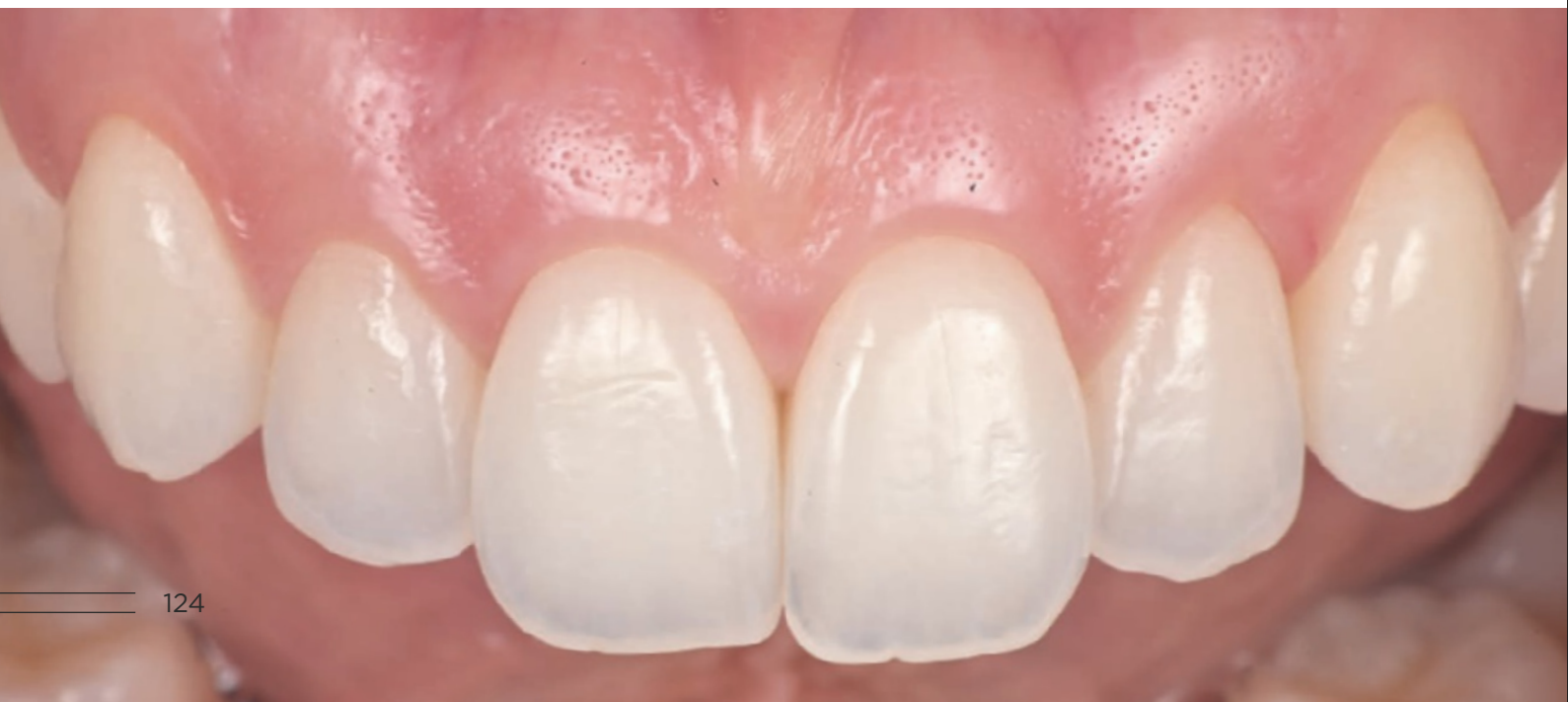Technically, the procedure begins with a horizontal incision, positioned 2 mm submarginally and extending anteriorly from the first molar. At the anterior end of this incision, a vertical L-cut is made to improve access. A thick, split-thickness flap is then carefully raised from the incision margins, leaving a thin layer of periosteum intact above the palatal bone.

Using tissue elevator, the reflected flap is held in place while the graft is harvested by separating it from the deeper site. Care is taken to leave a 1.5 mm thick flap to promote proper healing. The donor site is then sutured closed.

In **Clinical case 2 (Figs 37 to 43)** further details of the technique, and also in **figure 44** an image for a link to a video (**Video 3**) of this procedure.

L-INCISION TECHNIQUE	ADVANTAGES	LIMITS
<ul style="list-style-type: none"> • A horizontal incision and a mesial vertical incision to create an L-shape • The connective tissue graft is harvested from the underlying area • The area is sutured to achieve primary closure 	<ul style="list-style-type: none"> • Adequate visibility for harvesting • Uniform harvesting procedure • Primary closure, reducing the risk of necrosis 	<ul style="list-style-type: none"> • Adequate learning curve • Possible complications such as bleeding, dehiscence, or infection due to the large wound required

Table 3



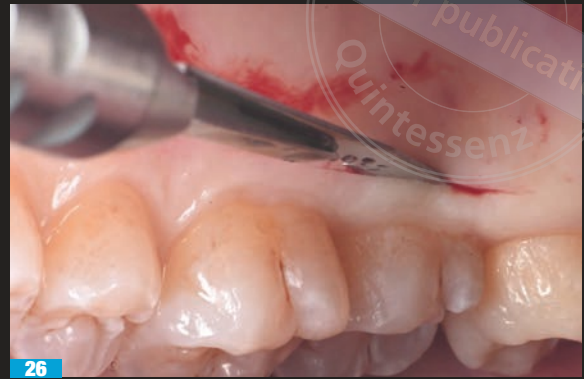
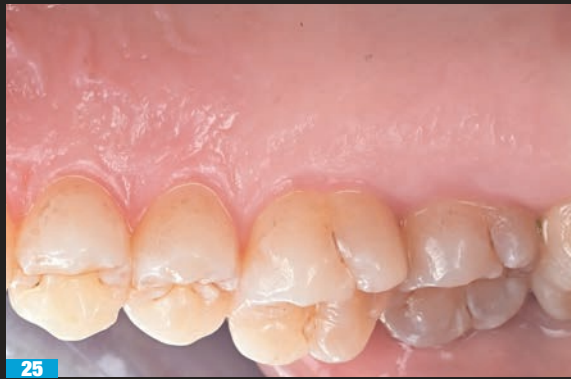
Fig 25 Initial case of a harvest using the L-shaped technique. **Fig 26** Split-thickness horizontal incision with the blade perpendicularly positioned to the surface to delimit a trap-door flap thickness of approximately 1.5 mm.

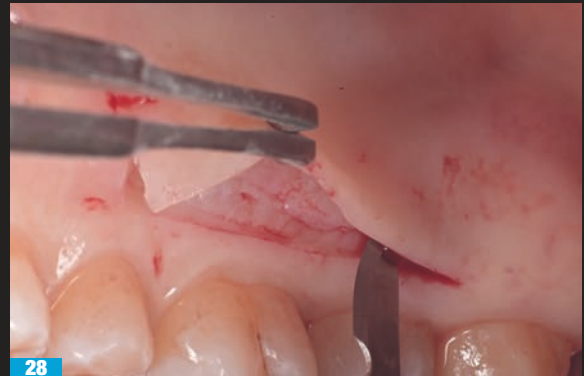
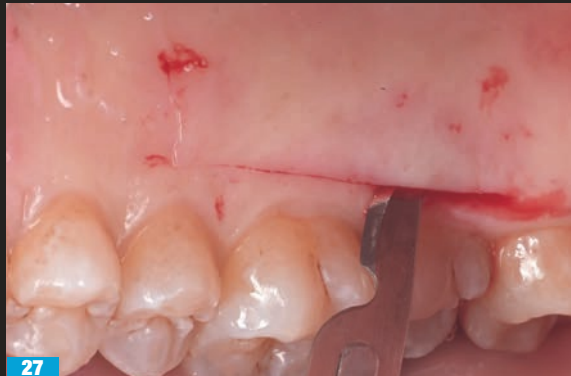
Fig 27 Change of blade inclination, moving it apically in a split-thickness direction with an inclination parallel to the long axis of the teeth. **Fig 28** After vertical releasing incision, the trap-door is raised up with partial-thickness approach.

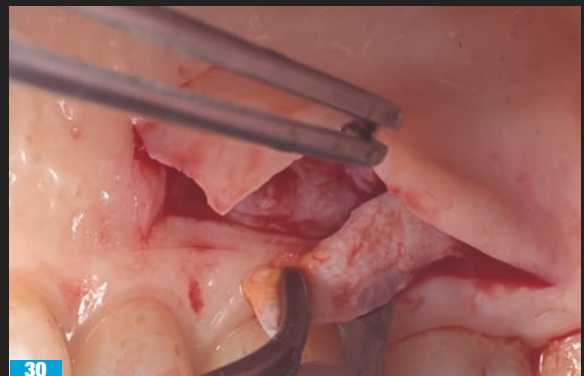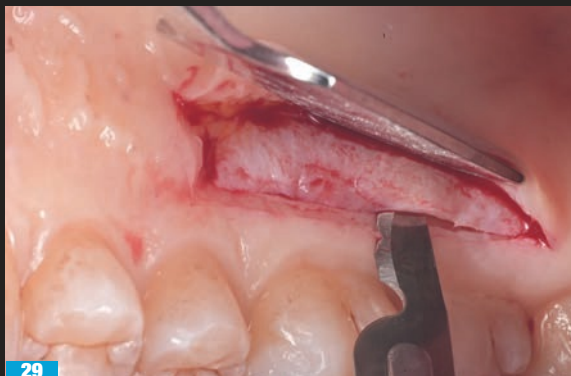


Fig 29 Once the trapdoor is raised up, the connective tissue can be harvested. The graft incision is approximately 1 mm apically than the initial incision. **Fig 30** The graft is progressively separated from the underlying layer.

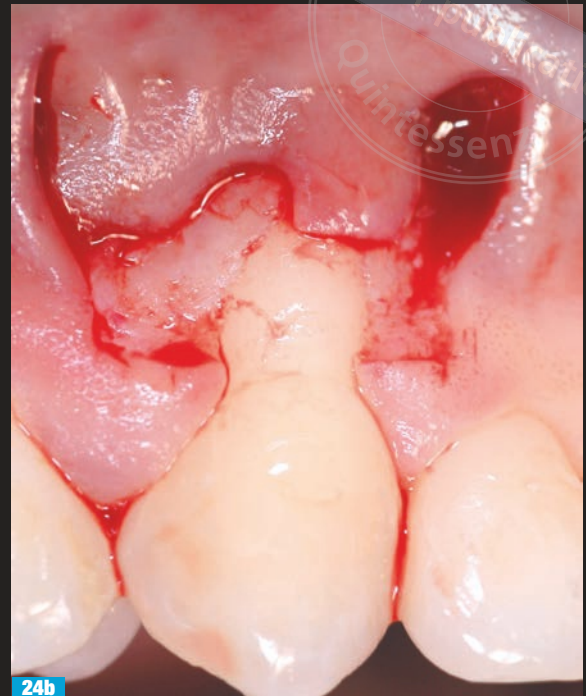
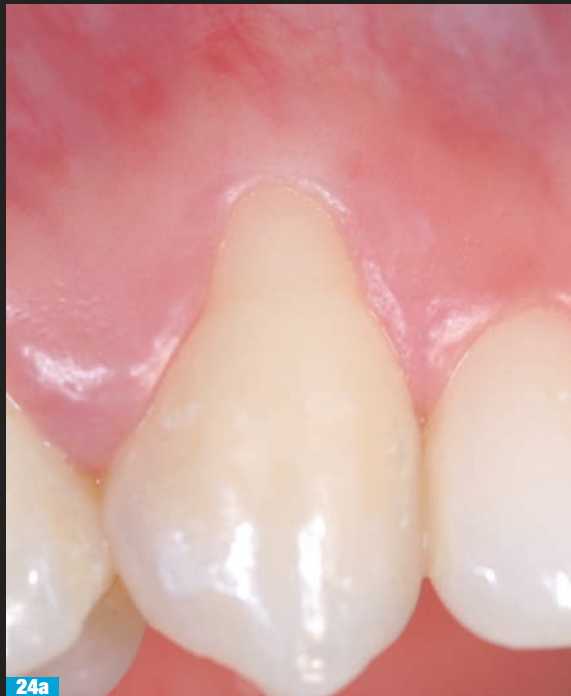

Fig 24a Baseline 4 mm recession at 13 before surgery. **Fig 24b** CAF elevation.

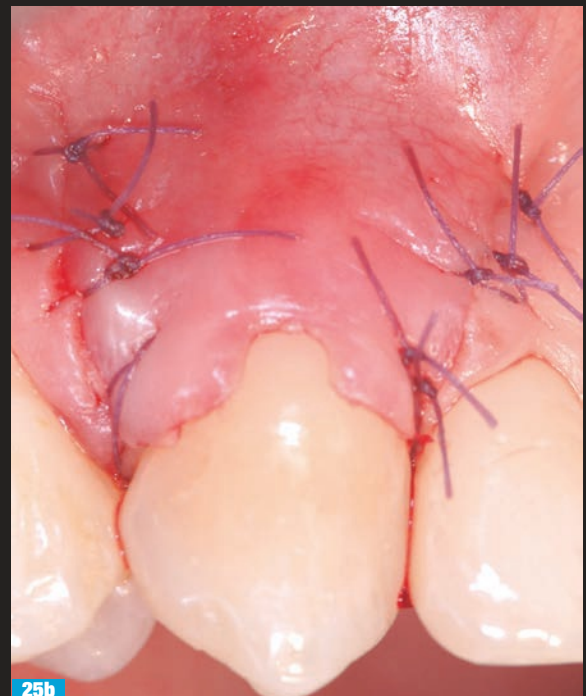
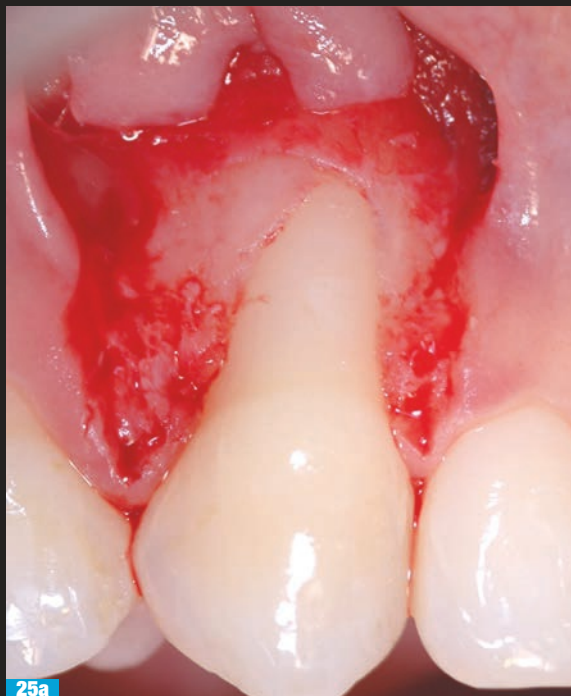

Fig 25a CAF after de-epithelialization of the anatomical papilla. **Fig 25b** CAF sutured coronally to the CEJ.

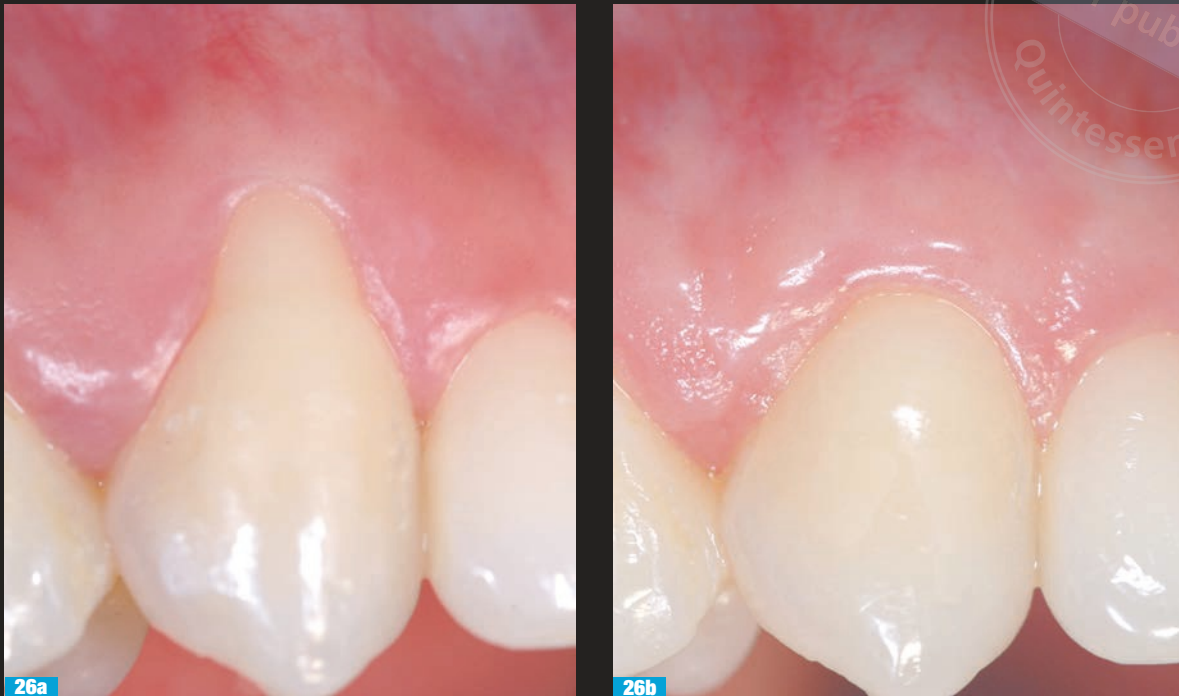

Fig 26 Baseline recession (**a**) and 1-year outcome (**b**) comparison.

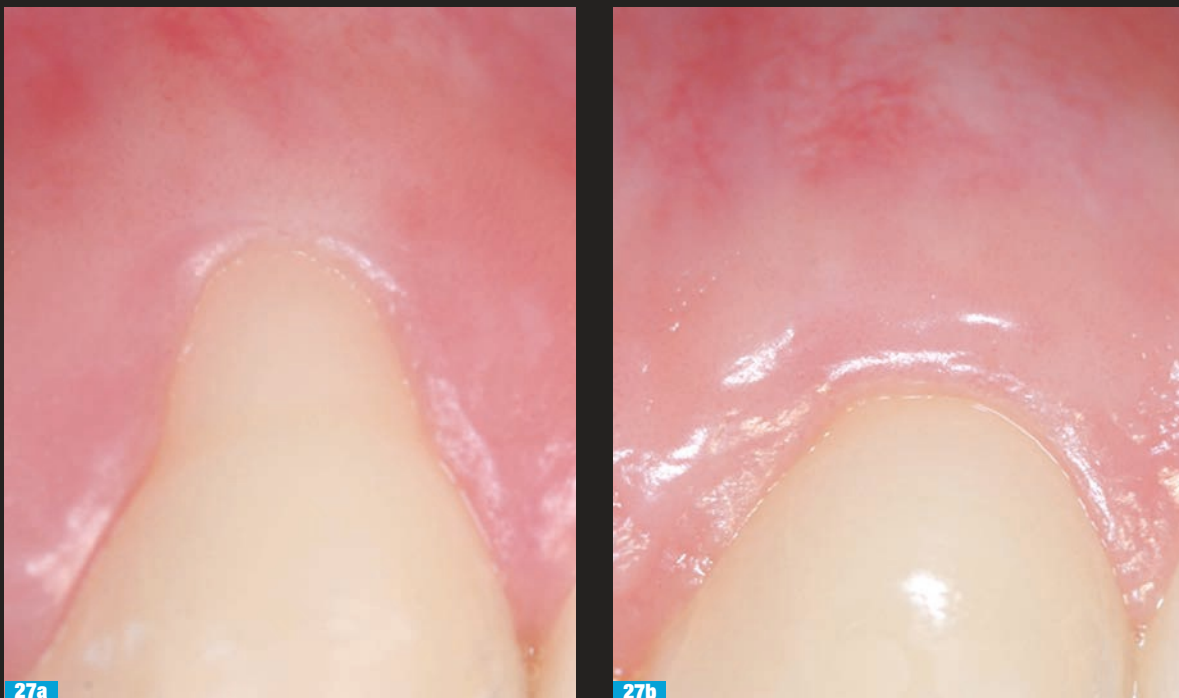
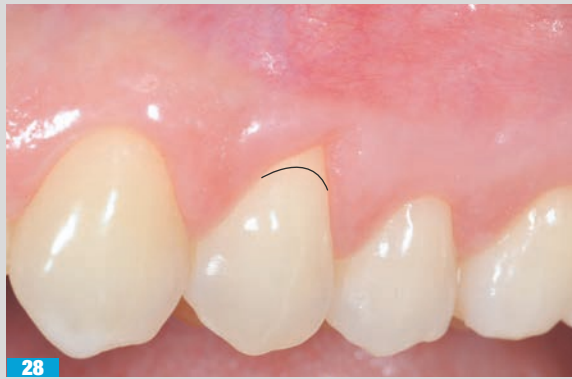
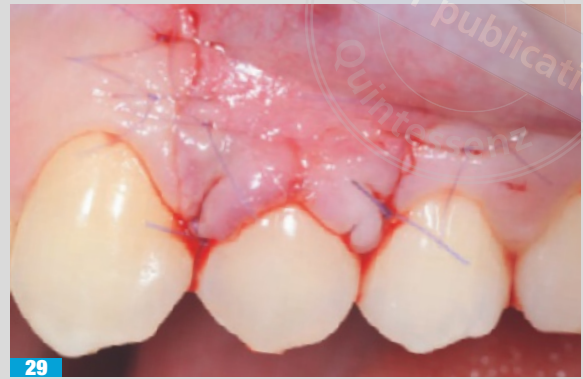Fig 27 Initial recession (**a**) and 1-year outcome (**b**) comparison (magnified).

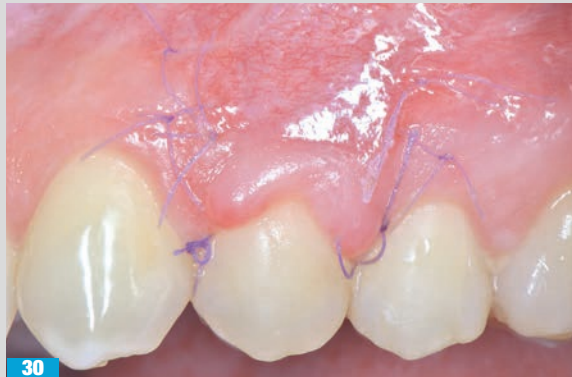

28

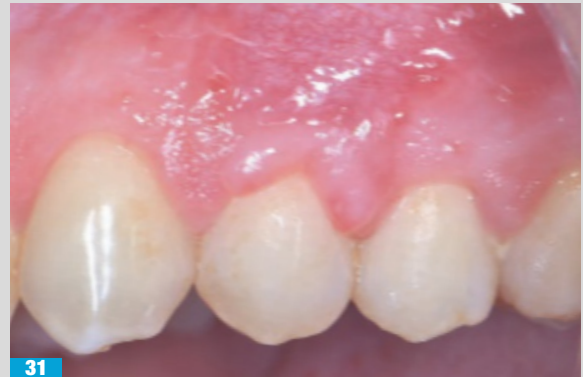

29

Fig 28 CAF healing model. Baseline recession at 24. **Fig 29** CAF sutured approximately 1.5 mm coronally to the CEJ.

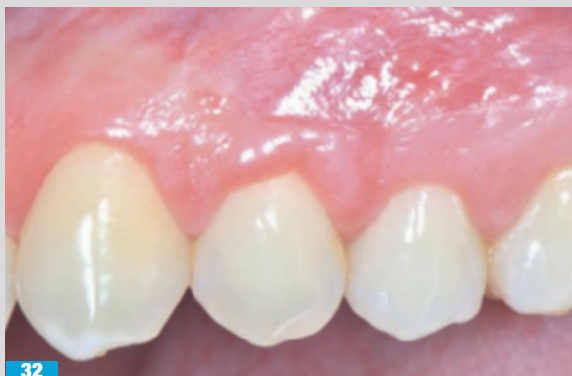

30

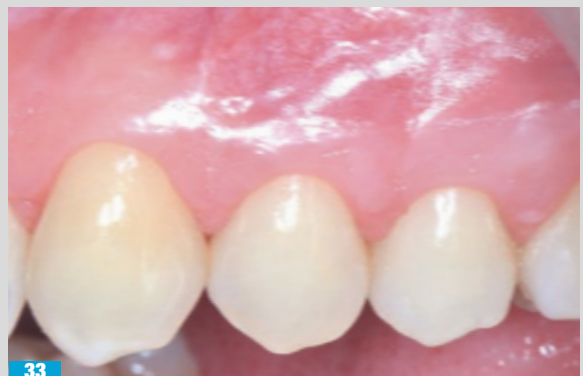

31

Fig 30 View at 10 days, note the stable flap and ongoing inflammatory phase. **Fig 31** View at 20 days, the edema is reduced.



32



33

Fig 32 View at 3 months, the edema has resolved and the gingival margin has slightly contracted. **Fig 33** View at 6 months, the tissues is stabilized after post-surgical contraction and complete root coverage has been achieved.

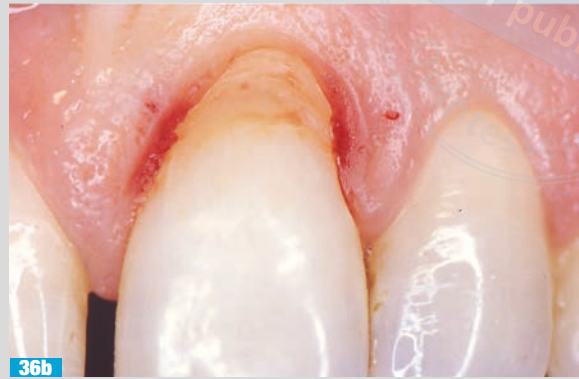
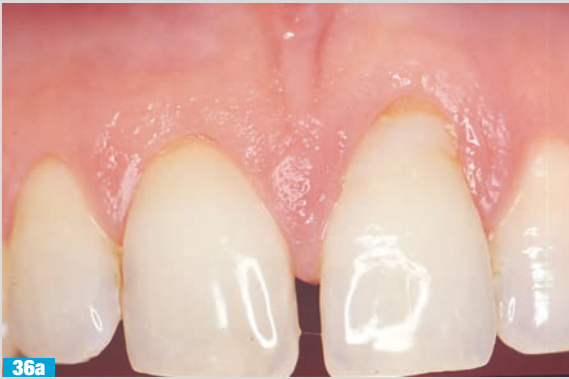
Fig 36a Baseline recession on tooth 21 with composite restoration applied over the root. **Fig 36b** Clinical appearance after restoration removal.

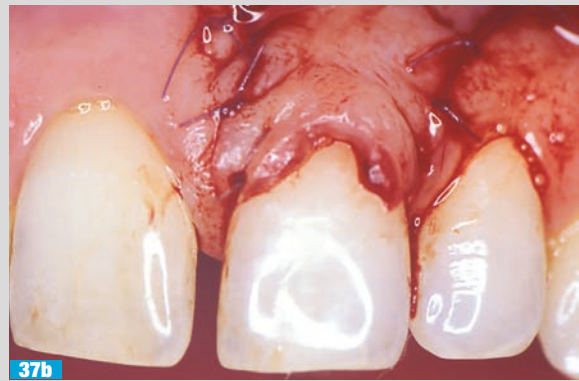
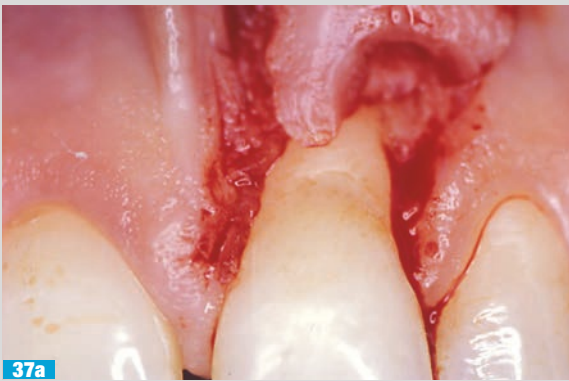
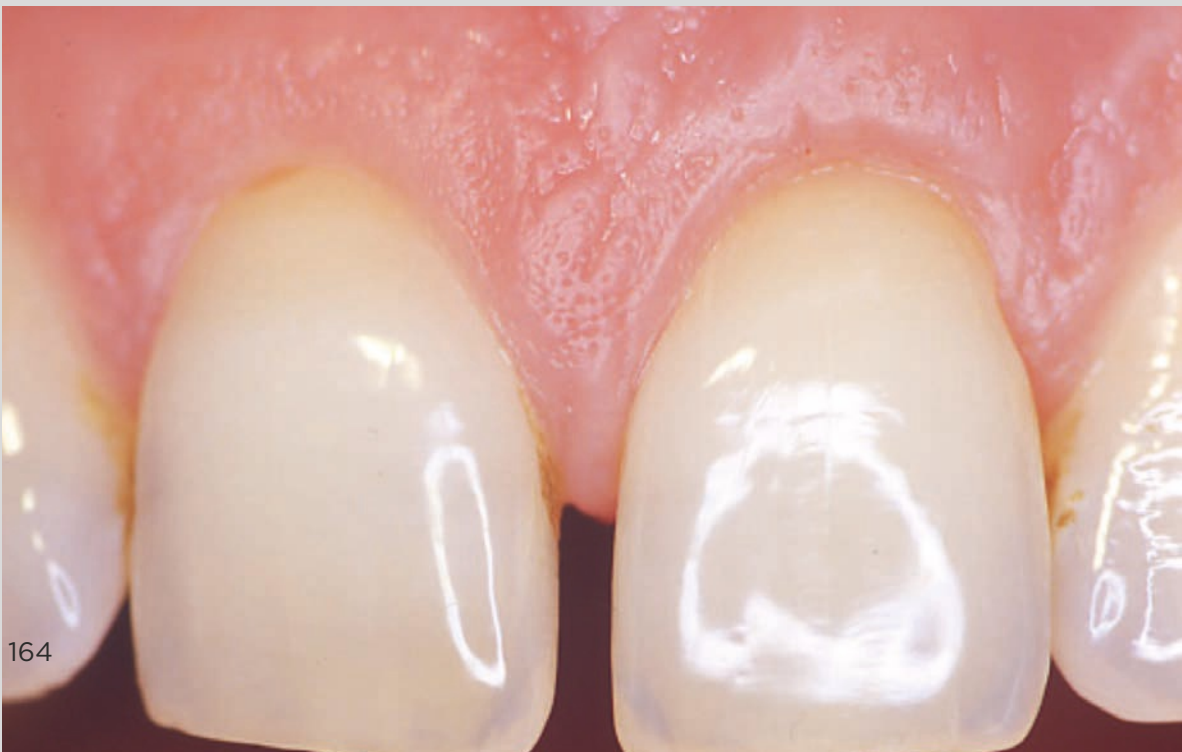
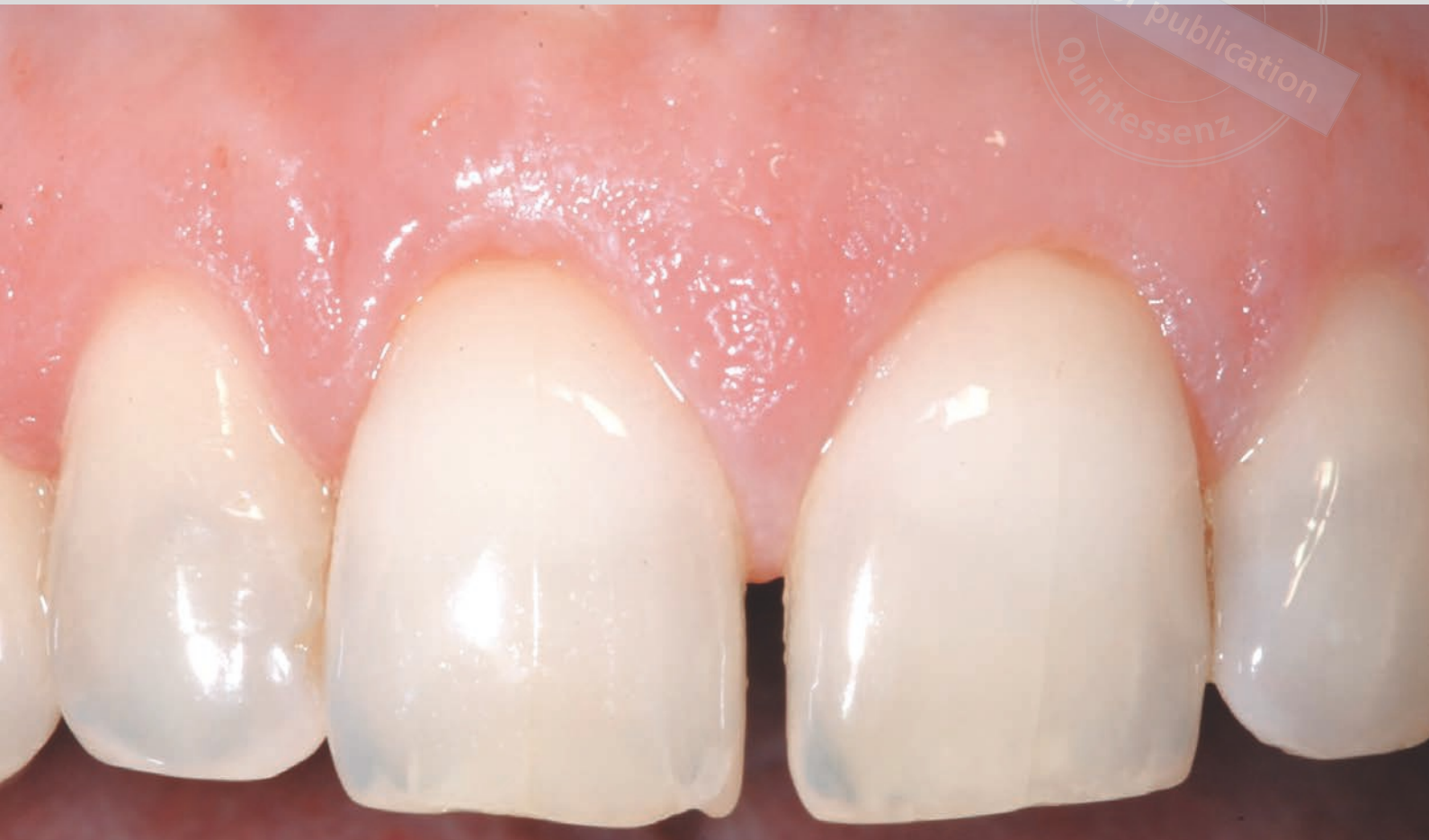
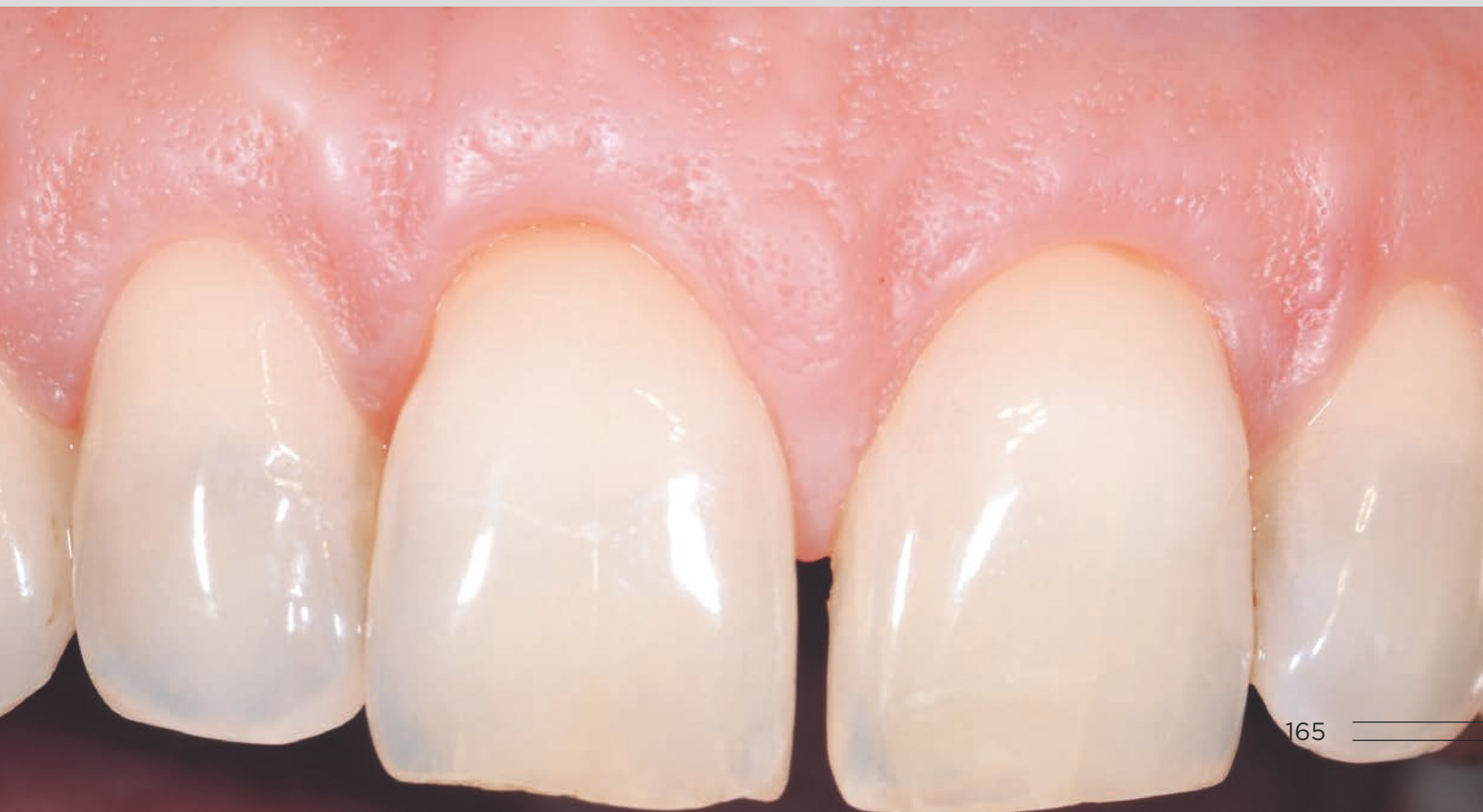Fig 37a CAF design. **Fig 37b** Sutured CAF.

Fig 38 Complete coverage at 1 year.





Figs 39, 40 (top) Clinical conditions after 10 years. Stability of results after 20 years (bottom).



Surgical Technique

Papilla preservation techniques

Surgical techniques leading to periodontal regeneration have become increasingly efficient through incisions designed to preserve interdental tissues.

Papilla preservation techniques aim to maintain the integrity of the papillary body by placing incisions either on the palatal or buccal aspect. These incisions allow improved wound closure, clot protection, and primary intention healing.

The first papilla preservation procedure was described by Takei (Takei et al, 1985), recommending a palatal semilunar incision that left the papilla attached to the buccal flap. The author noted that a buccal incision could be chosen when the defect was located palatally.

In 1995, Cortellini et al introduced the Modified Papilla Preservation Technique (MPPT), employing a buccal incision designed to increase the regenerative space and ensure primary flap closure at the interdental area, while maintaining a simplified surgical approach.

A full-thickness palatal flap, including the interdental papilla, is elevated to expose the interproximal defect.

The combination of the buccal incision with a partial-thickness buccal incision increases the likelihood of flap closure over non-resorbable titanium-reinforced membranes.

This procedure can be successfully applied when the width of the interdental space is at least 2 mm at the apical portion of the papilla.

For narrower interdental spaces, the Simplified Papilla Preservation Flap (SPPF) was proposed (Cortellini et al, 1999).

This technique involves an oblique incision through the papilla associated with the defect, extending from the buccal line angle of the involved tooth toward the middle portion of the interdental papilla below the contact point of the adjacent tooth.

The papilla is thus splitted into two different part: the buccal portion is elevated with the buccal flap, and the lingual part with the lingual flap (Cortellini & Tonetti, 2015).

The interdental space may be described either as a “clinical diastema”, a space larger than 0.5 mm between proximal surfaces, or an “anatomic diastema”, defined as an increased space between roots measured at the supracrestal portion of the papilla (**Figs 21 and 22**).

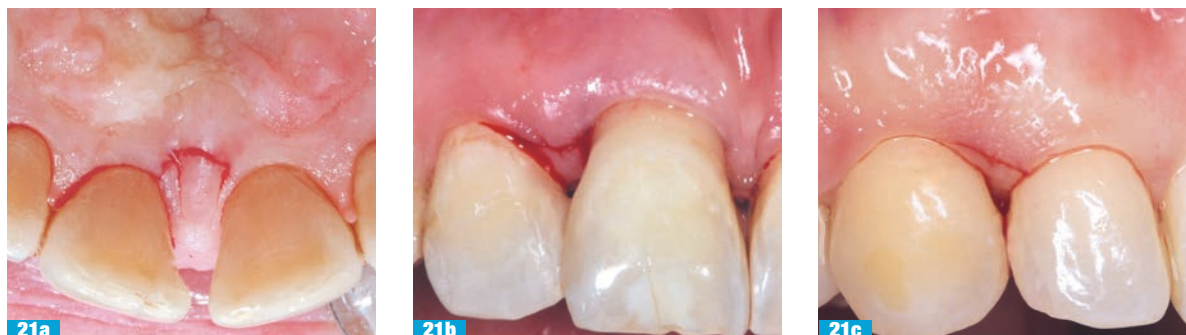

Fig 21 Incision techniques for the interdental papilla. **a)** Palatal incision according to Takei et al. **b)** Modified papilla preservation technique. **c)** Simplified papilla preservation technique.

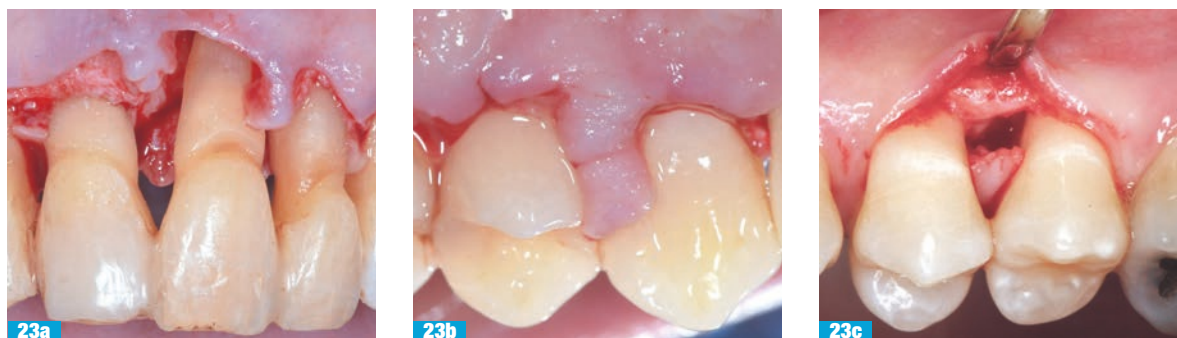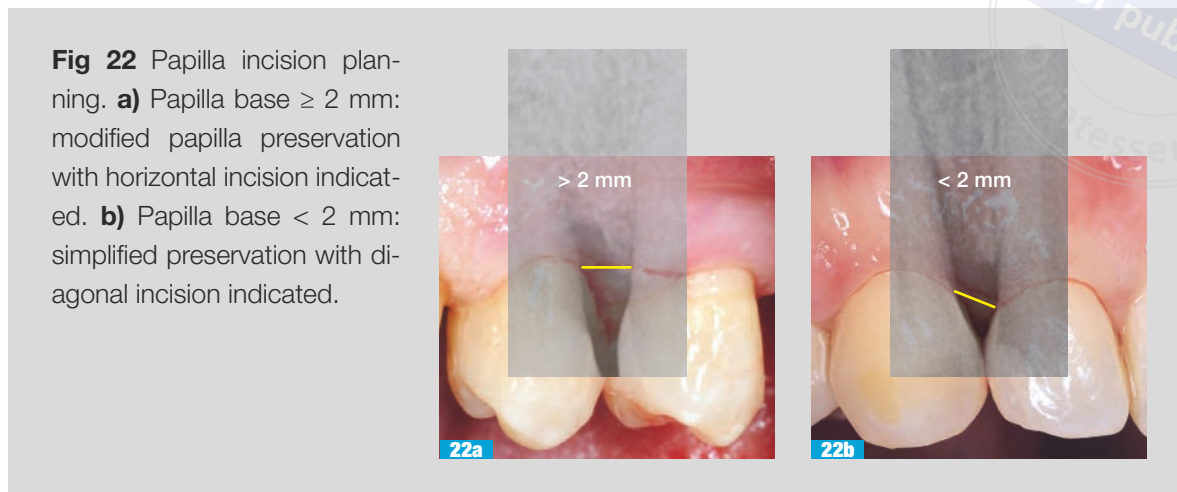


Fig 23 Papilla preservation techniques. **a)** Takei technique. **b)** Modified preservation with palatally rotated papilla. **c)** Minimally invasive papilla incision technique.

Flap design

Minimally invasive surgery

the term minimally invasive surgery (MIS) describes a minimally traumatic approach for the treatment of intrabony defects, involving intrasulcular incisions, preservation of the entire interdental papilla, and minimal flap elevation to access the osseous defect (Harrel et al, 1999; Cortellini & Tonetti, 2007). The literature consistently reports that periodontal regeneration of intrabony defects results in clinical attachment level (CAL) gain, probing pocket depth (PPD) reduction, and minimal gingival recession (REC).

More recently, new techniques have been introduced to further reduce flap dimensions, healing

time, and patient discomfort (M-MIST) (Cortellini et al, 2009) (**Figs 23 and 24**).

The flap procedure employs a papilla preservation technique in all circumstances and is particularly indicated for single defects with interproximal and buccal involvement. Within this field, several technical modifications have been described, such as the single-flap approach (SFA) or the modified minimally invasive surgical technique. The surgical approach consists of a small interdental access in which only a small triangular buccal flap is elevated, while the papilla is left in place, connected to the root of the involved tooth by the supracrestal fibers (Trombelli et al, 2009).

These modified approaches are associated with minimal morbidity and excellent clinical outcomes

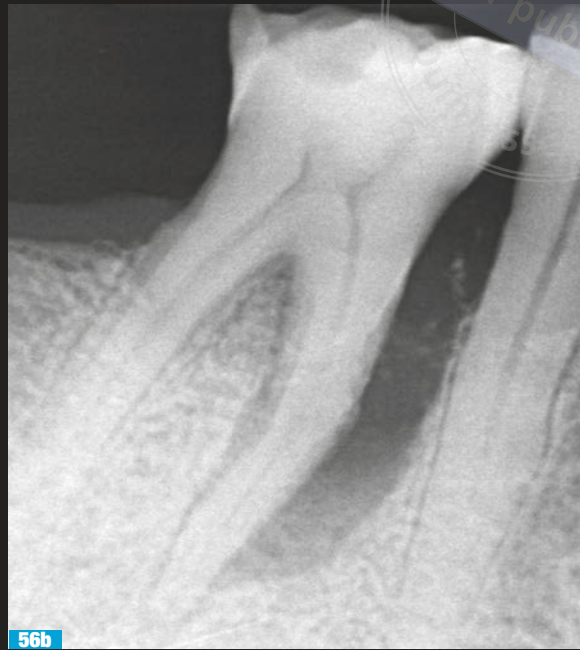
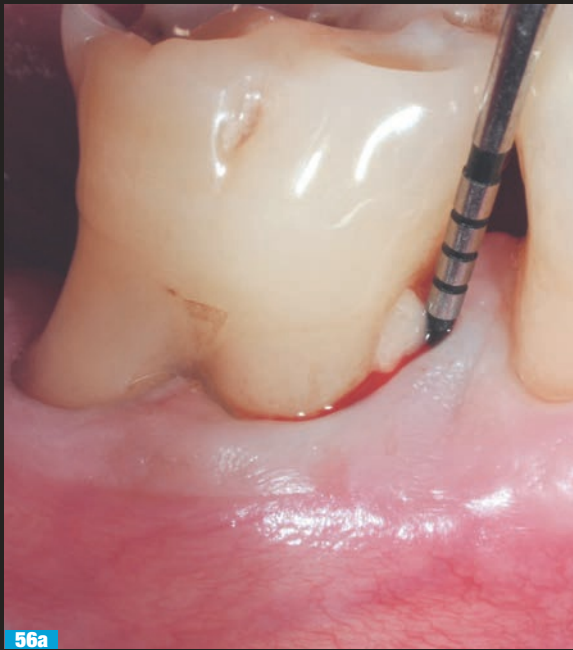
Fig 56 Deep site-specific pocket with persistent inflammation/infection mesial to 46 (a) with a very deep bone defect (b).

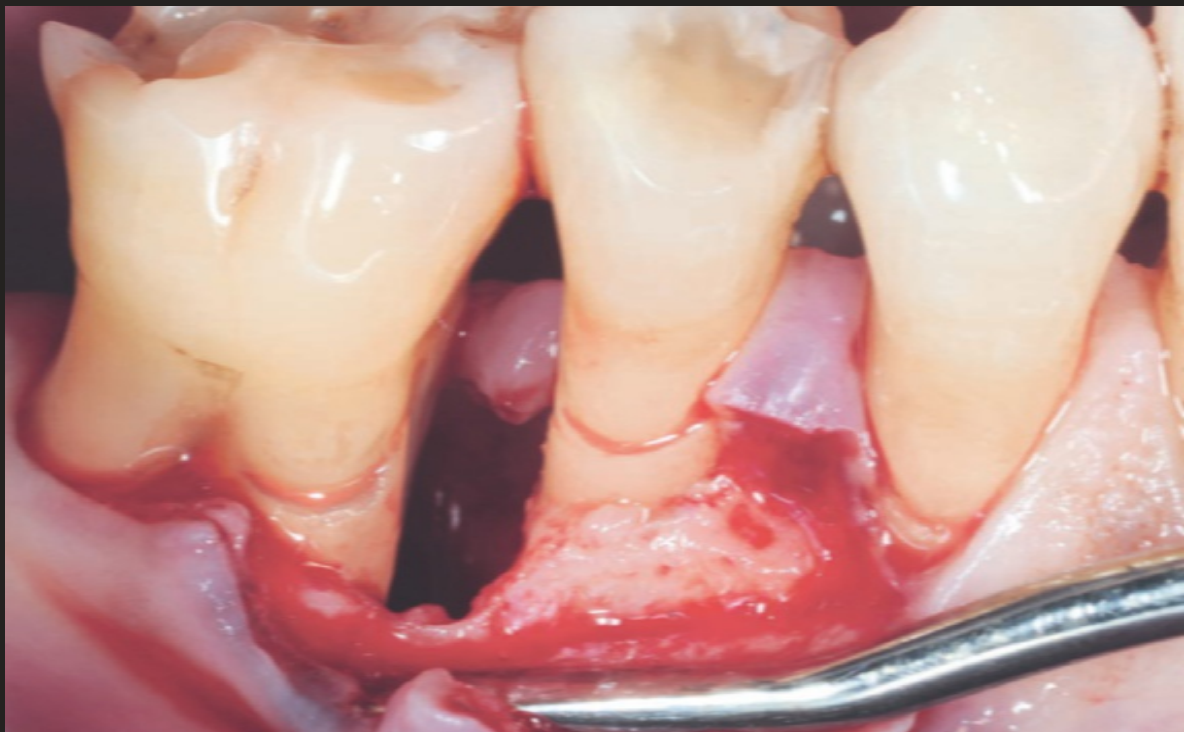

Fig 57 Minimally invasive surgery performed only on the buccal aspect; corresponding papillae are incised but not reflected.

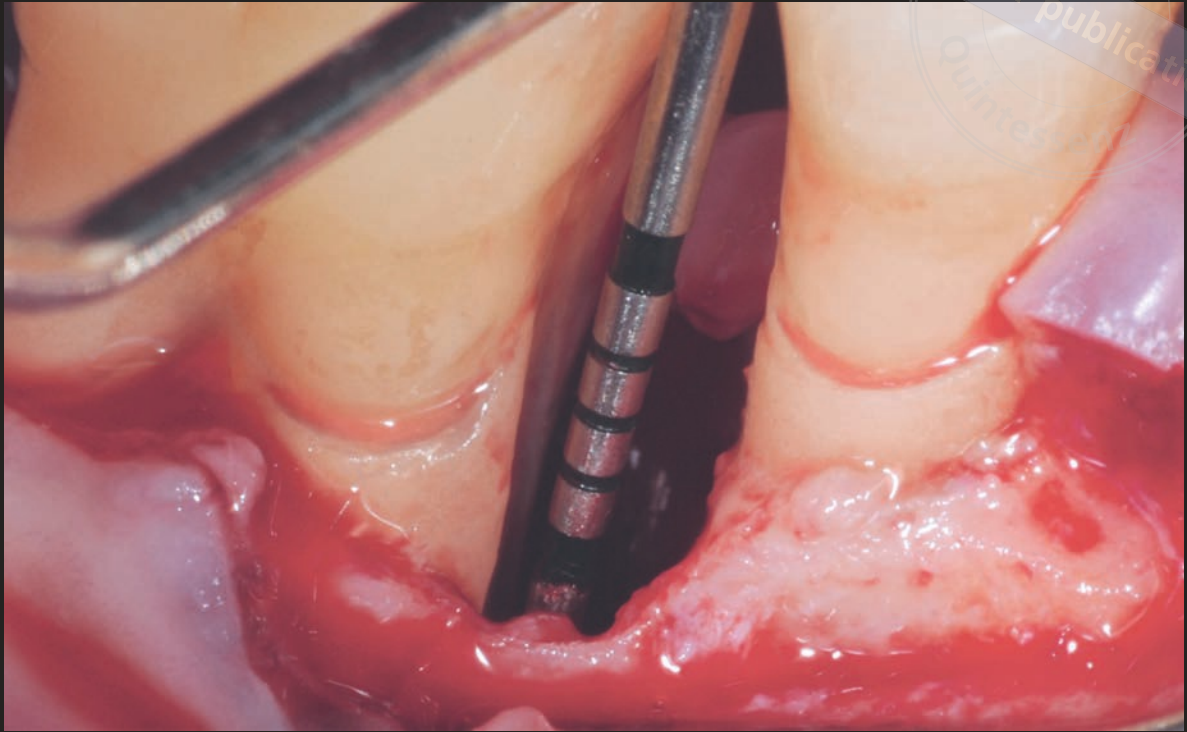


Fig 58 Identification of 11-mm depth infrabony defect.

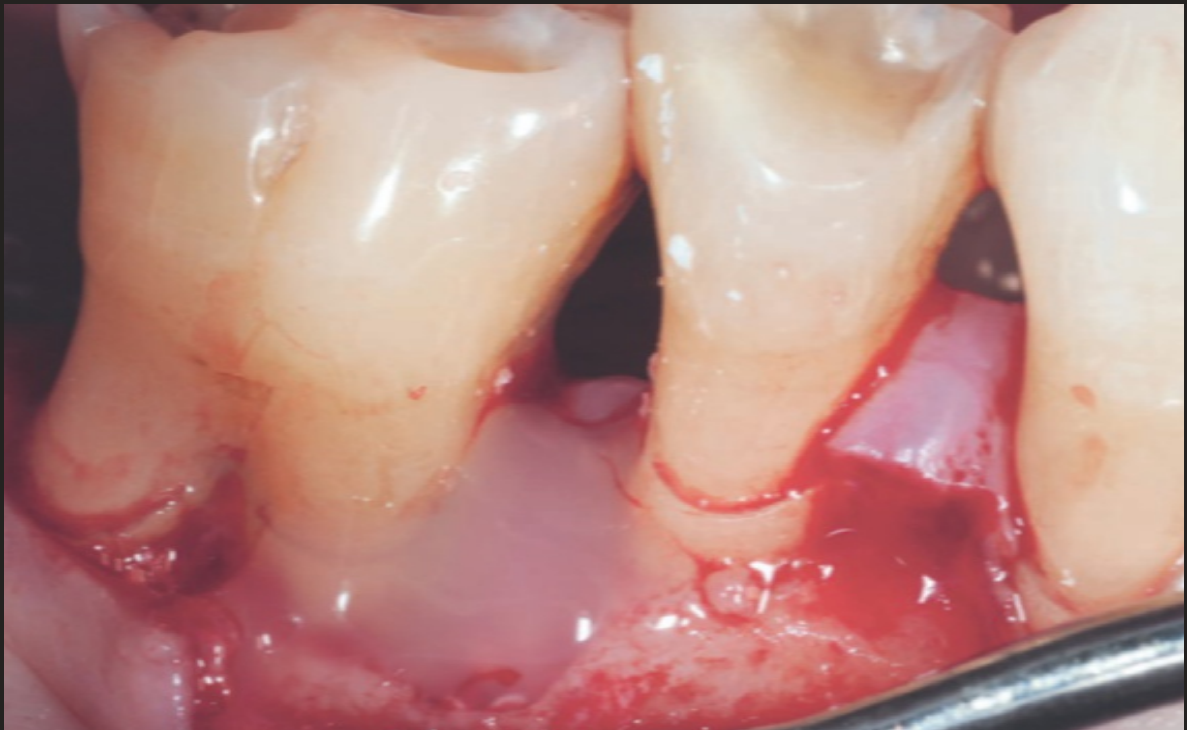


Fig 59 Application of amelogenins.

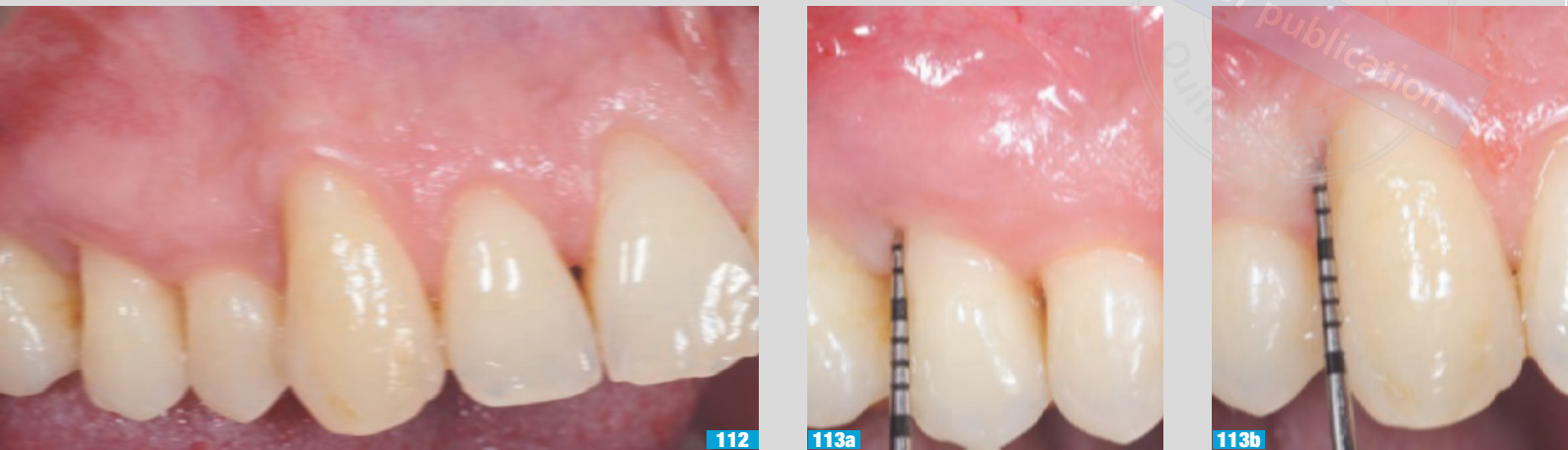

Fig 112 Multiple recession defects (RT 2 on 11 and 13) in the 11–16 sextant with interdental pockets and distal infrabony defects at 15 and 13. **Fig 113** Initial pockets at 15 and 13.

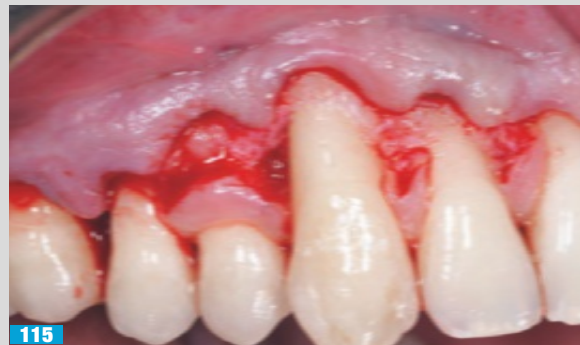
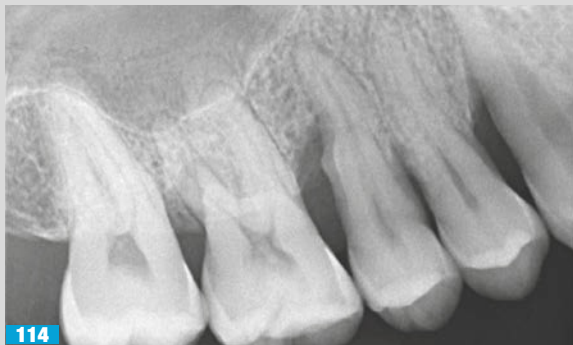
Fig 114 Initial radiograph of defects in figure 113. **Fig 115** Design of a multiple coronally advanced flap with 13 as rotation center, submarginal incision for false recession at 14, simplified mesial papilla preservation at 16, and complete distal preservation at 13.

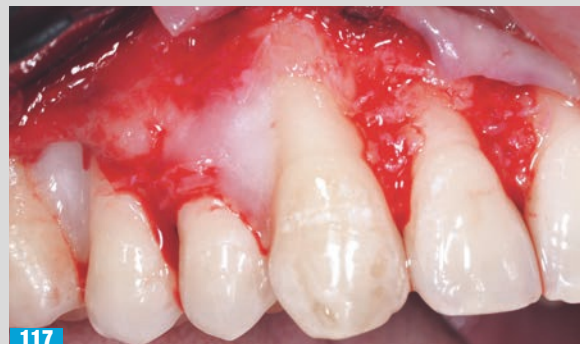
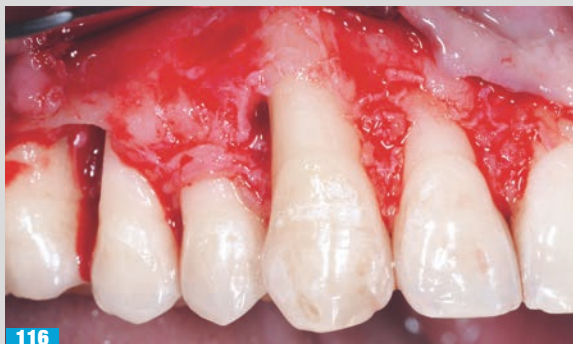
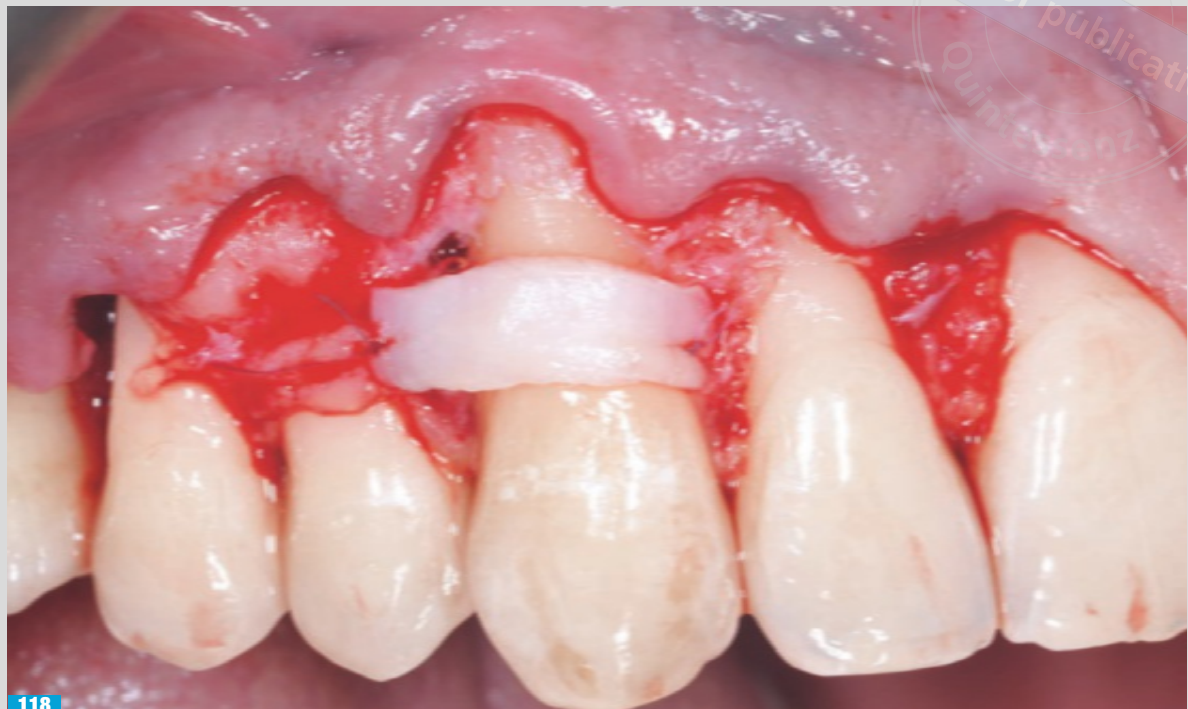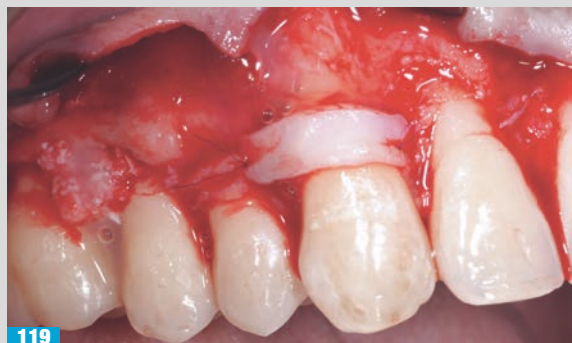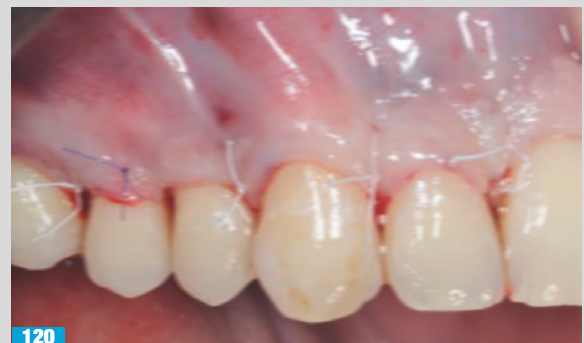Fig 116 De-epithelialization of papillae and false recession area. **Fig 117** EDTA application before application of enamel matrix derivative.



118

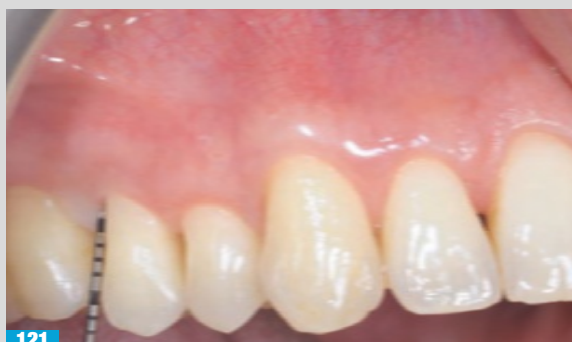

119

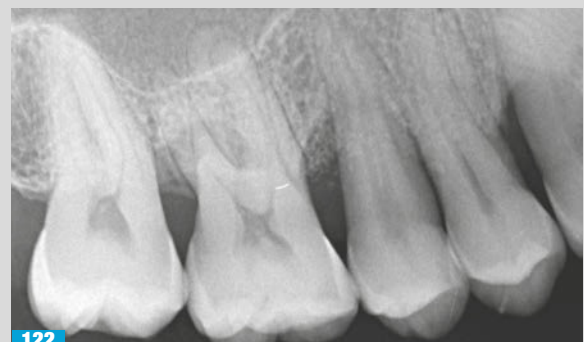

120

Fig 118 Stabilization of buccal connective tissue graft at 13 anchored to de-epithelialized papillae with simple sutures. **Fig 119** Application of amelogens and deproteinized bovine bone in defect distal to 15. **Fig 120** Coronally advanced flap suture.

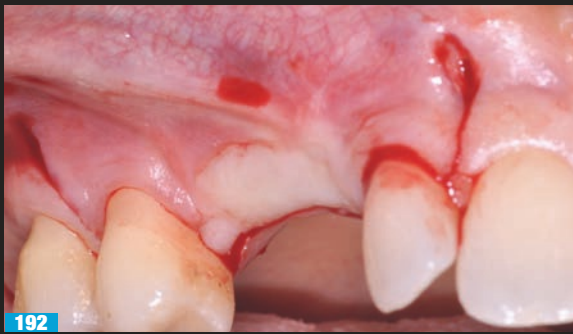


121

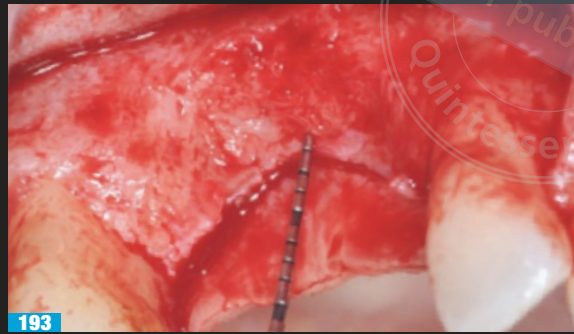


122

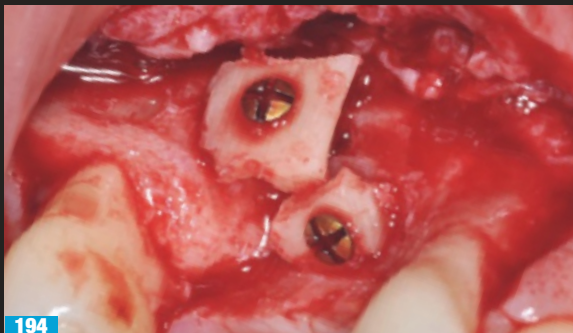
Fig 121 Healing with esthetic improvement and recession reduction at 13 and 11. **Fig 122** Final radiographs.



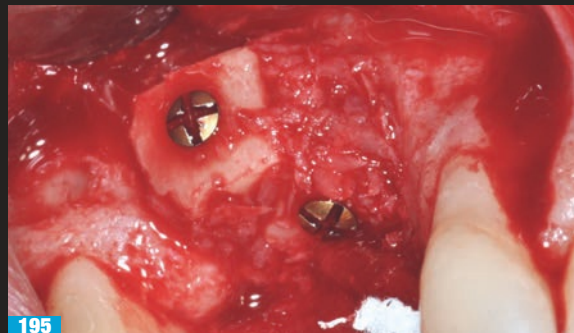192



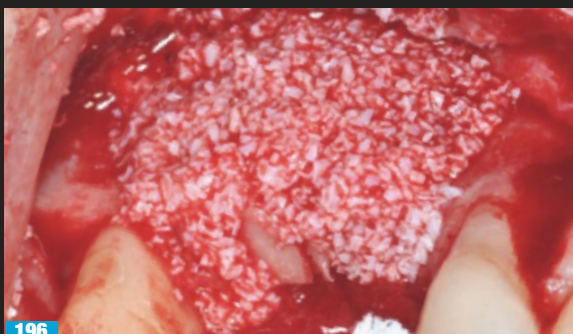193



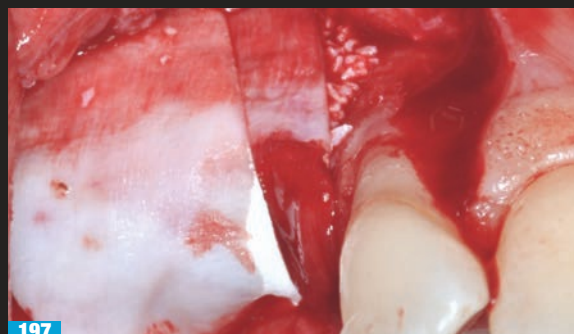
194



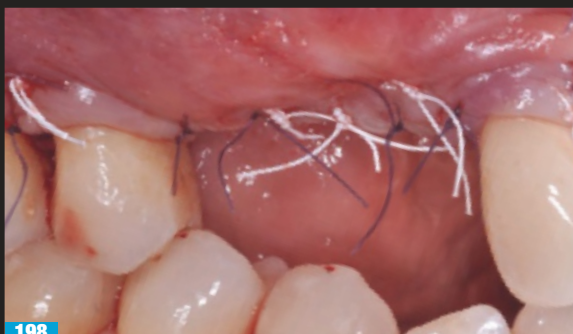195



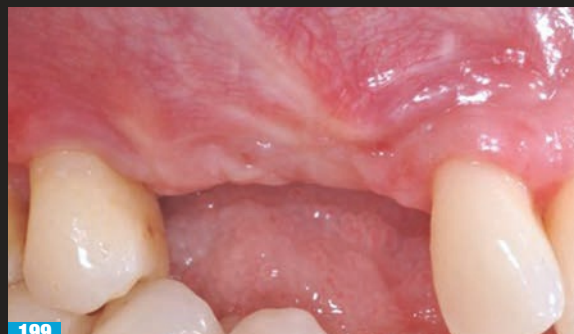196



197

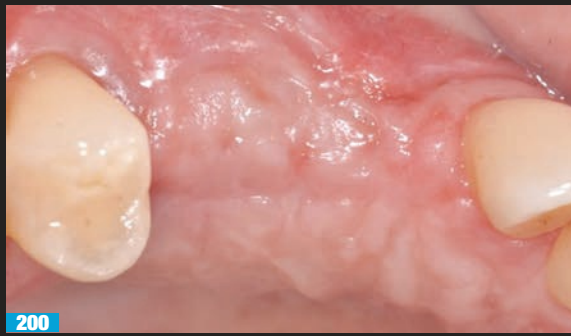

198

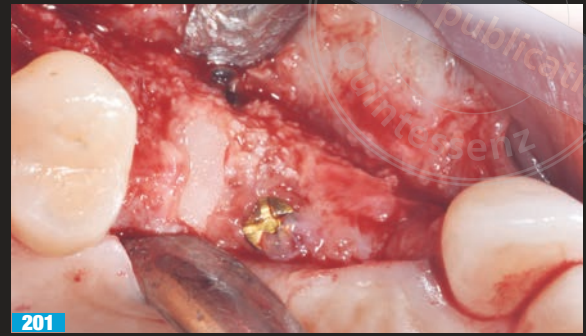

199

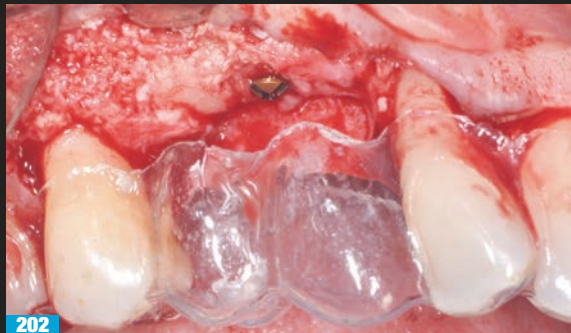Fig 192 Flap design with two vertical releasing incisions. **Fig 193** Elevation of a full-thickness flap. **Fig 194** Placement of two autogenous block grafts, one horizontal and one vertical. **Fig 195** Application of particulate autogenous bone. **Fig 196** External application of deproteinized bovine bone. **Fig 197** Stabilization of resorbable membranes. **Fig 198** Primary intention closure after flap passivation. **Fig 199** After 5 months, view of the site from the buccal aspect.



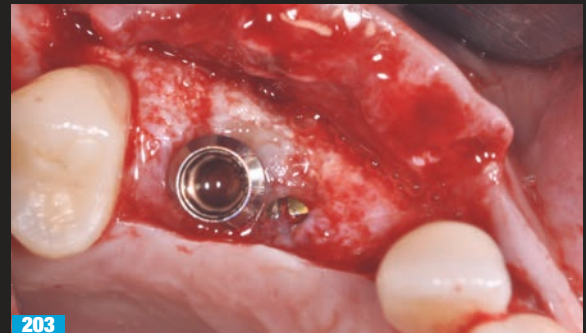
200



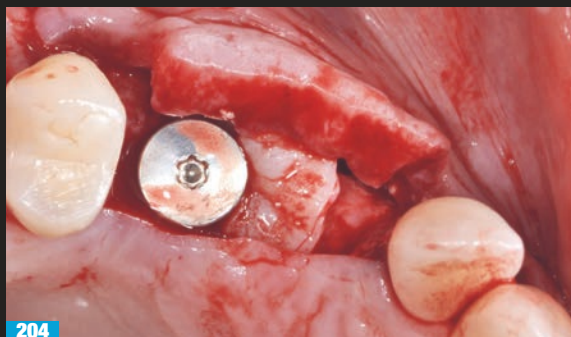
201



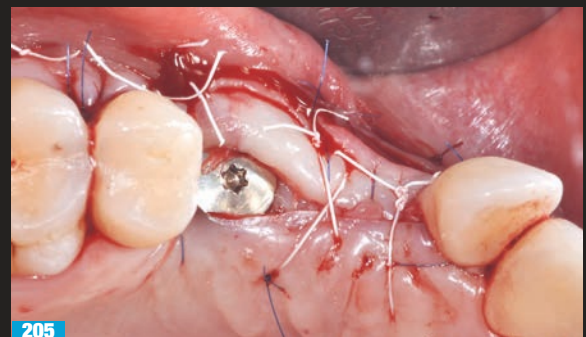
202



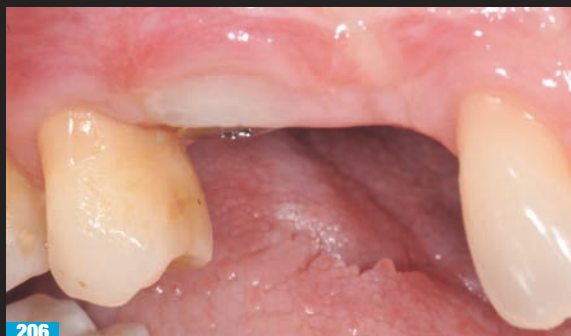203



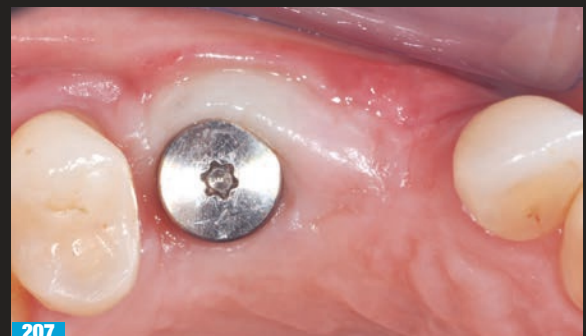204



205



206



207

Fig 200 After 5 months, occlusal view of the site. **Fig 201** Re-entry. **Fig 202** Placement of a single implant at site 24. **Fig 203** Placement of a single implant at site 24, occlusal view. **Fig 204** Use of a connective tissue graft in the area of tooth 23. **Fig 205** Wound suture with a healing abutment in place. **Fig 206** Buccal view of soft-tissue healing. **Fig 207** Occlusal view of soft-tissue healing.