

SEBASTIAN COTOFANA

THE ANATOMY
OF BEAUTY

PREFACE

Welcome to a new kind of anatomy experience.

This book is unlike traditional facial anatomy texts. It presents the human face through a fresh lens — revealing the intricacies of tissue structure and function using meticulous, innovative dissection techniques. The better the dissection, the deeper the understanding we can gain. One of my mentors, Prof Dr Bernhard N. Tillmann, often reminded us: “The donor is always right.” I have carried that wisdom with me throughout my career.

My passion for anatomical dissection began during my medical studies at Ludwig-Maximilians-University in Munich, Germany. Each donor entrusted me with a task: identify, reveal, and honor a specific anatomical structure. That responsibility inspired me to be precise, thoughtful, and persistent.

As my career progressed — from senior postdoctoral work to trauma surgery — I learned that knowing anatomy is one challenge, but teaching it is another entirely. Effective teaching requires breaking complex information into meaningful, digestible parts, transforming a seemingly overwhelming subject into one that informs and empowers.

With that goal in mind, I began developing new approaches to dissection and new ways of visualizing anatomical relationships. I was fortunate to be supported and inspired by mentors and friends — Prof Dr Bernhard N. Tillmann, Prof Dr Michael Pretterklieber, Prof Dr Gottfried Bogusch, Prof Dr Andreas Winkelmann, Prof Dr Eveline Baumgart-Vogt, and PD Dr Sabine Löffler — all esteemed members of The Anatomische Gesellschaft.

When I moved to the United States and joined Albany Medical College as an associate professor of anatomy, I found myself again humbled. Teaching anatomy to medical students is meaningful — but equipping surgeons, dermatologists, and aesthetic practitioners with knowledge that directly informs patient care takes anatomical interpretation to an entirely new level.

It was during this time that I met Dr Marcelo Charles Pereira, an exceptional ENT specialist and friend from Curitiba, Brazil. Together, we spent countless evenings and weekends in the laboratory — including a memorable dissection on the Fourth of July. His expertise and enthusiasm sparked a shift in how I viewed and documented anatomy. Through specialized photography and video capture, the relationship between structure and clinical practice became clearer, more accessible, and more profound. The techniques that evolved during this special collaboration forms the foundation of what you will see throughout this book.

As you explore these pages, I hope you discover not only knowledge, but beauty — the elegance of facial anatomy expressed through artfully executed dissection. The imagery is designed to draw your eye to essential structures while preserving the dignity and individuality of the donors who made this work possible.

Thank you for choosing to join me on this journey — and for honoring the generosity of those who gave the ultimate gift so that we may learn.

— *Sebastian Cotofana*

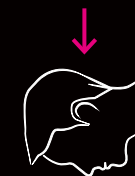
CONTENTS

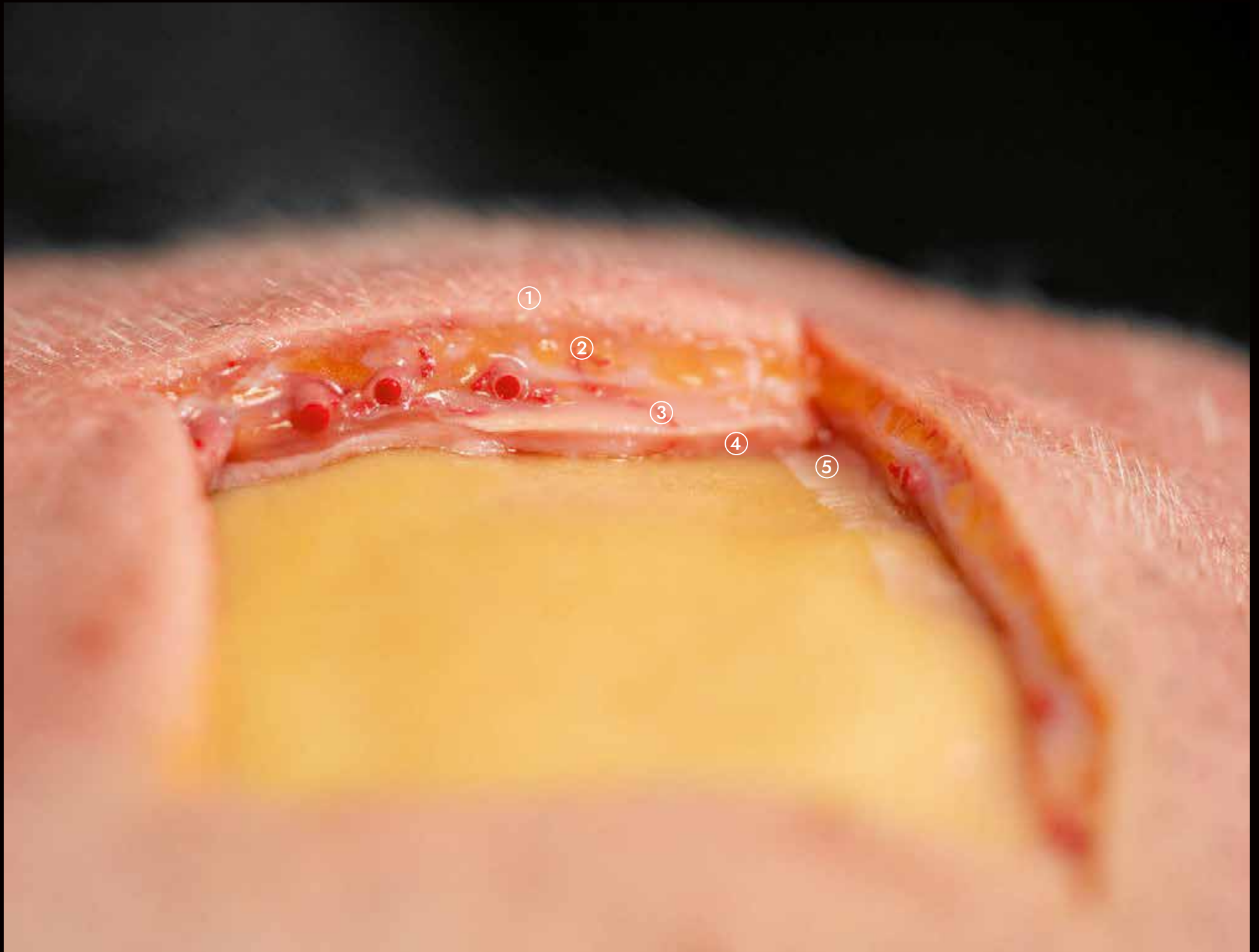
Chapter 1	Facial Layers	1
Chapter 2	Injection Biomechanics	21
Chapter 3	Temples	41
Chapter 4	Forehead	85
Chapter 5	Glabella	109
Chapter 6	Periorbital	131
Chapter 7	Nose	163
Chapter 8	Medial Midface	187
Chapter 9	Lateral Midface & Line of Ligaments	231
Chapter 10	Lips & Perioral	257
Chapter 11	Chin	301
Chapter 12	Jawline & Mandibular Angle	333
Chapter 13	Neck	359
Chapter 14	Body	377

Each fascial plane contains specific structures like nerves or vessels and thereby provides guidance and protection along their pathway. In the scalp, the superficial fatty layer (Layer 2) contains the majority of the arterial and venous vasculature. The loose connective tissue (Layer 4), in contrast, is predominantly free (but not 100% devoid) of neurovascular structures, as this plane supports the majority of the soft tissue movements of the scalp. The periosteum, however, contains a substantial number of sensory nerves alongside small arteries and veins, as their function is to provide arterial and venous blood supply to the underlying bone.

Fig. 1.4 Full-thickness resection of all fascial layers of the scalp, allowing for a cross-sectional view. Several subdermal arteries have been exposed and transected, demonstrating their subdermal location. Note: the arteries are filled with red latex to allow for better visualization.

- 1 Skin
- 2 Superficial fatty layer
- 3 Galea aponeurotica
- 4 Loose connective tissue
(here thickened)
- 5 Periosteum





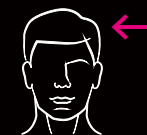
The field of injection biomechanics was recently introduced into the scientific literature, which describes factors that influence injection-related product distribution:

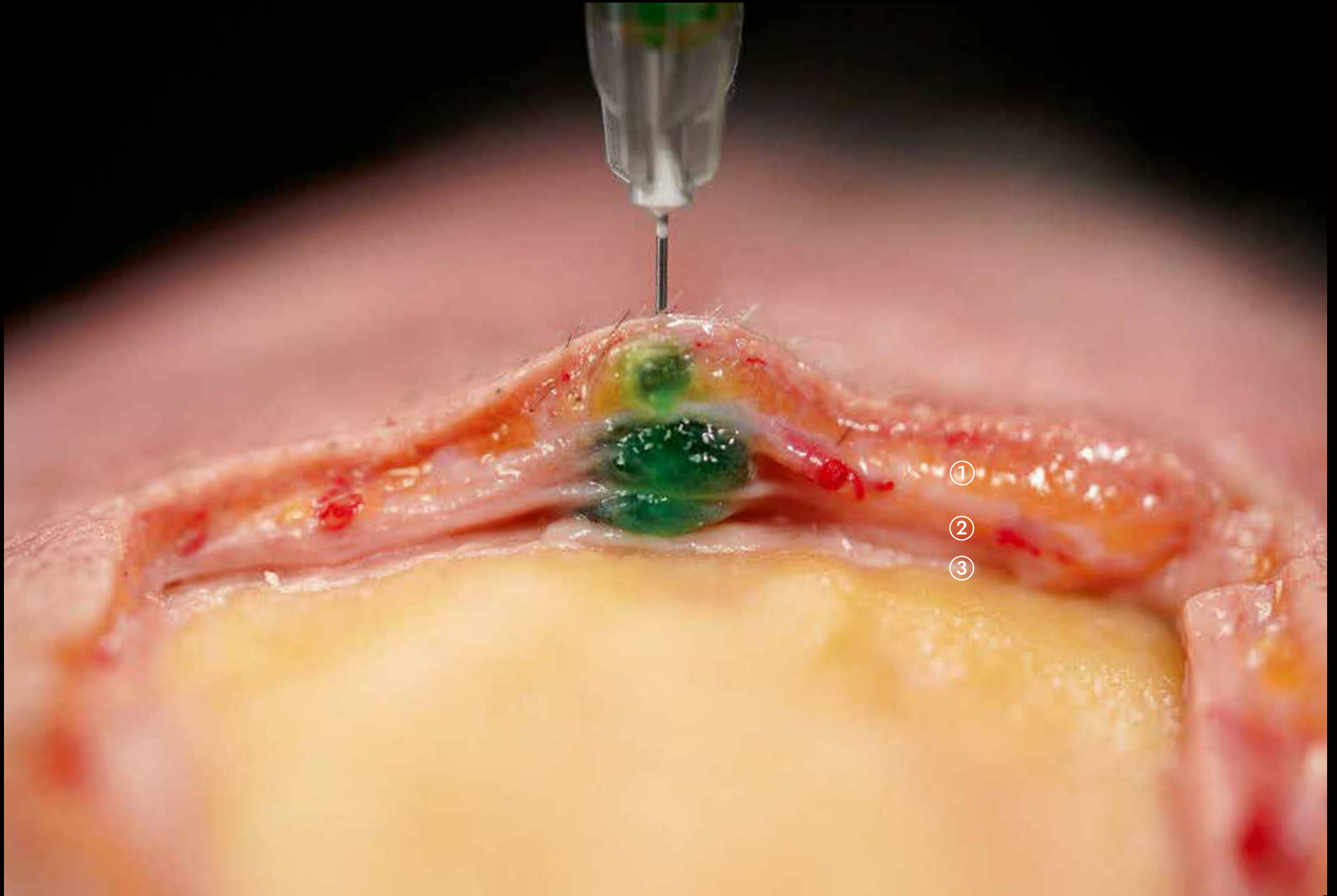
1. Rheology of the product (softer = the more product distribution)
2. Needle/cannula external diameter (larger = the more product distribution)
3. Injection angle (steeper = the more product distribution)
4. Injection speed (faster = the more product distribution)

All of the above factors (1–4) influence the distribution of the product, which always follows the pathway of least resistance. This pathway is created by the introduced needle/cannula, which is why the first line of product distribution is along the created injection canal.

Fig. 2.2 Retrograde product distribution following a 90-degree (to the bone surface) injection using a 27 G, ½ inch/13 mm needle. Despite being in constant bone contact during the injection process, the product flowed backward along the vertically oriented injection canal into more superficial layers, reaching the subdermal plane where arterial vessels are located.

- 1 Subdermal plane
- 2 Intrafascial plane
- 3 Supraperiosteal plane



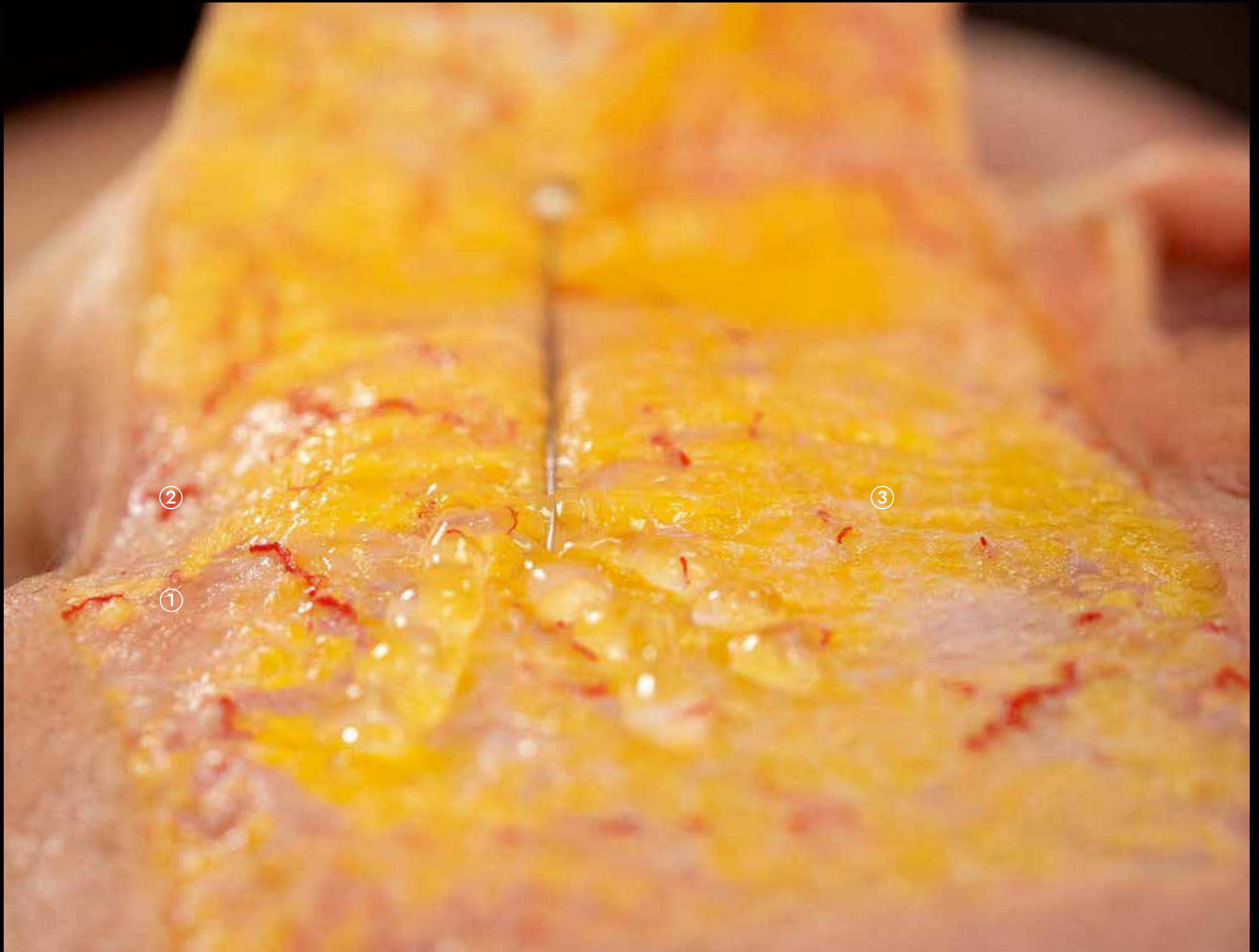

Within the subdermal fatty layer, no major neurovascular structures can be identified; however, this does not mean that this fascial plane is avascular. Especially in the periorbital region, small arteries can be identified that are frequently accompanied by the periorbital subdermal venous plexus; the latter can show signs of engorgement after the subdermal fanning technique, but this will resolve without clinical intervention within the following days after the treatment. If the cannula is advanced to reach the lateral canthal region, a concomitant treatment of lateral canthal lines can be performed to address deep smile lines (also referred to as "Crow's feet").

Fig. 3.6 The subdermal product deposition places the material superficial to the orbicularis oculi muscle, which is a potent orbital sphincter and eyebrow depressor muscle.

- 1 Orbicularis oculi muscle
- 2 Periorbital arterial vascular network
- 3 Superficial fatty layer

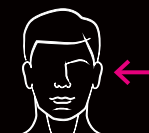


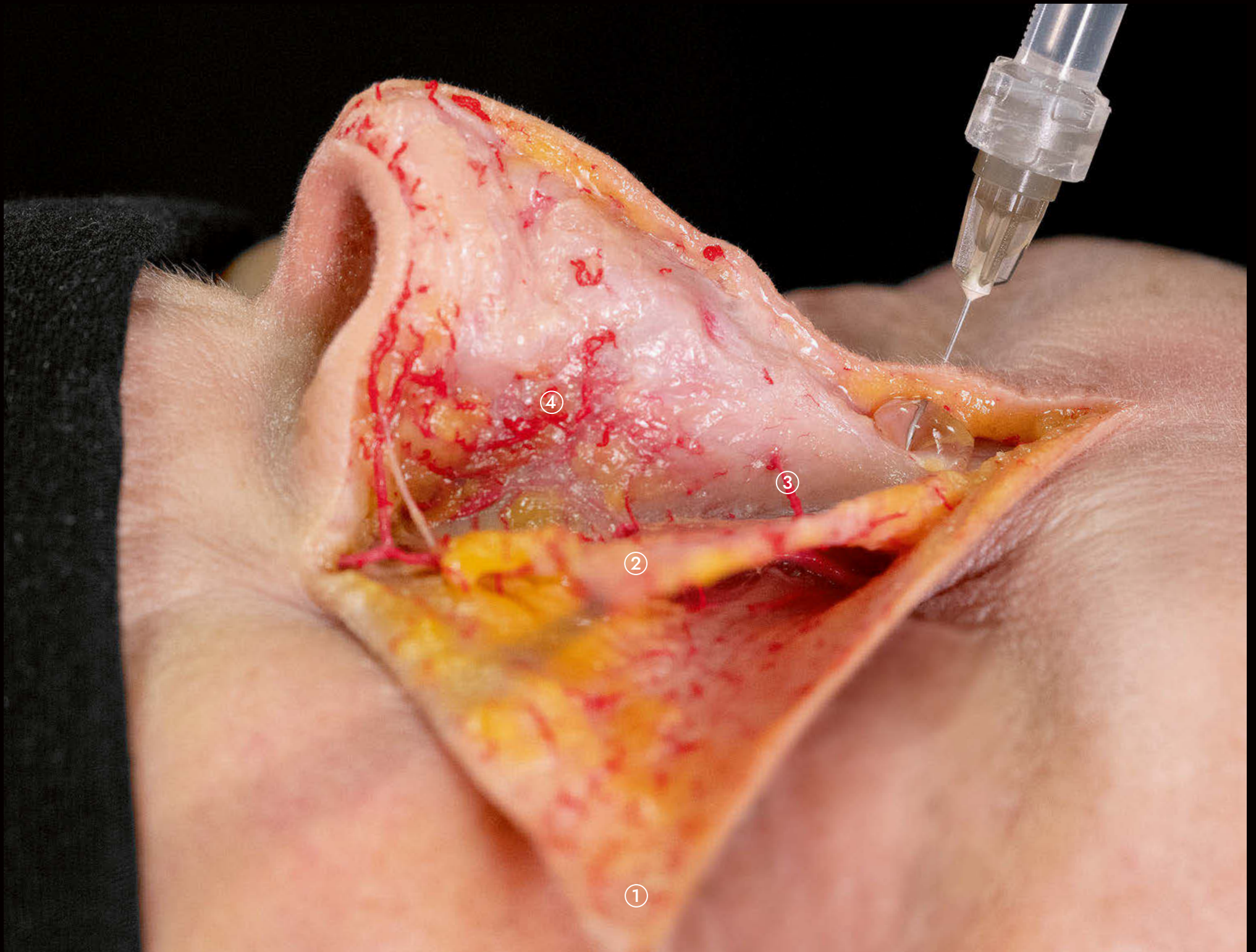
To address a prominent nasal hump, most often caused by the position of the nasal bone, the soft tissue filler product is injected at the root of the nose in deep contact with the bone. This elevates the soft tissues cranial to the dorsal nasal hump and decreases the volume difference between the glabellar prominence and the nasal line. Too much product deposition should be avoided so as not to create a continuous line between the nasal tip and forehead; this is considered aesthetically displeasing. Pre-injection aspiration should be conducted, because in this location the transverse branch of the dorsal nasal artery connects to the contralateral facial side and is located in the deep plane in 50% of cases.

Fig. 7.9 The treatment of a prominent dorsal nasal hump with nonsurgical soft tissue filler injections using a 27 G, ½ inch/13 mm needle. Note that it is paramount to maintain constant bone contact in the nasal midline during product deposition.

- 1 Skin
- 2 Nasalis muscle
- 3 Septal branch of the anterior ethmoidal artery
- 4 Scroll area



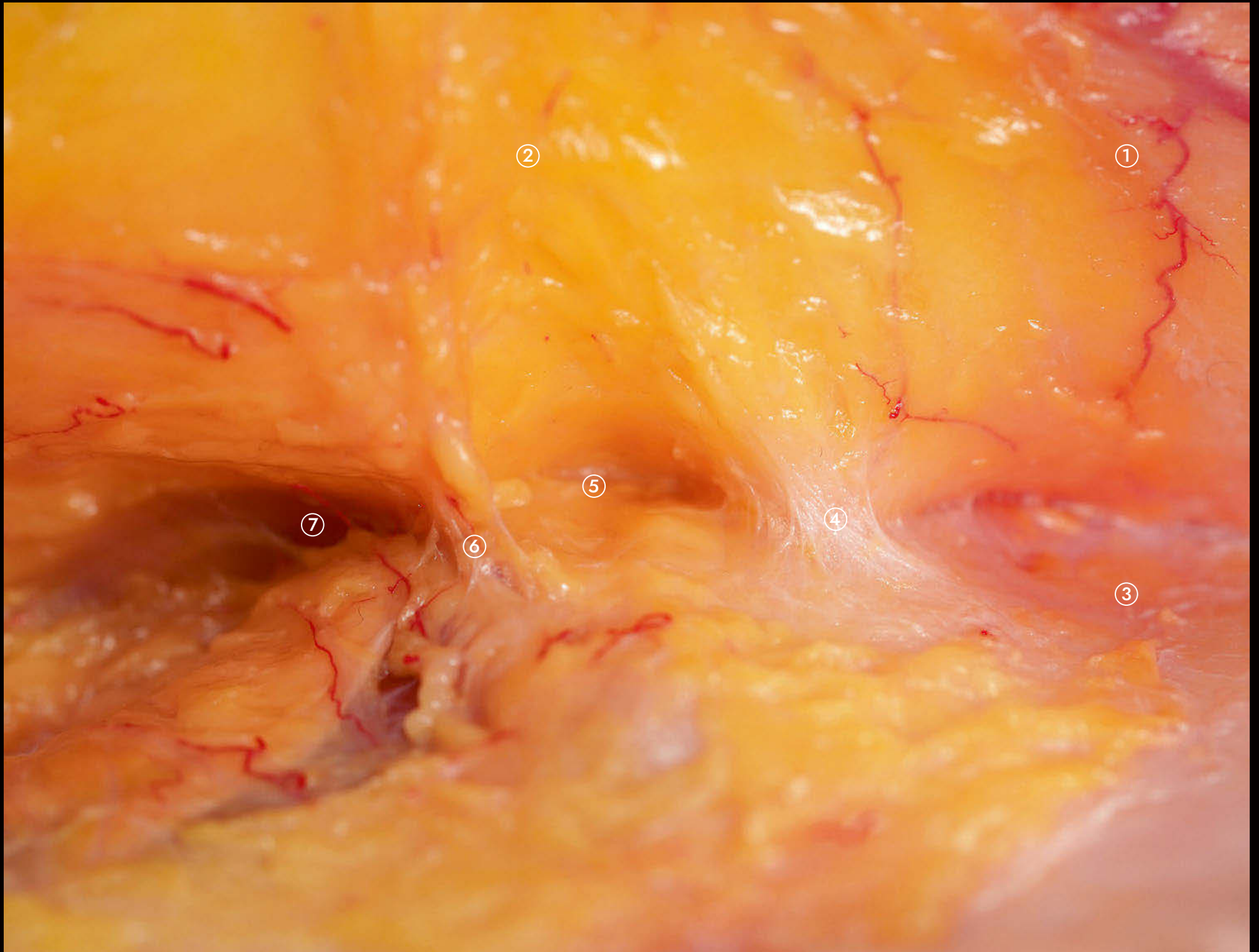


The strongest facial ligament is considered to be located at the zygomatic arch in close proximity to the bony origin of the zygomaticus major muscle and is termed the *zygomatic ligament*. Another term for this ligament is *McGregor's patch*, and it has been shown to be of crucial relevance for surgical face lifting procedures. The release of this ligament allows for good medial midfacial repositioning, a soft tissue mobilization step that is most relevant for improving the central facial oval. Care must be taken to respect the intraligamentous perforator branch of the transverse facial artery, which is consistently found to travel within this ligament.

Fig. 9.5 Close-up view of the left zygomatic region in view from posterior (see Fig. 9.4). The lateral orbital thickening, temporal tunnel, zygomatic ligament, and bony origin of the zygomaticus major muscle are visible.

- 1 Superficial temporal fascia
- 2 Superficial musculoaponeurotic system
- 3 Deep temporal fascia
- 4 Lateral orbital thickening
- 5 Suborbicularis oculi fat
- 6 Zygomatic ligament
- 7 Zygomaticus major muscle





Treatment of the jawline can target the posterior and anterior jawline including the chin with one single dermal access point. This point is located at the mid-distance between the mandibular symphysis and mandibular angle. Following dermal puncture, the cannula is inserted into the subdermal plane and first advanced posteriorly to increase the posterior jawline contour and increase the lateral projection of the mandibular angle. The cannula is then withdrawn and, right before exiting the skin, turned 180 degrees and advanced anteriorly within the superficial fatty layer. This allows for targeting of the Marionette line, the prejowl sulcus, and the chin zone.

Fig. 12.8 Nonsurgical treatment of the anterior jawline using a 22 G, 2 inch/50 mm blunt-tip cannula in a horizontal approach. The cannula is located within the superficial fatty layer to avoid any crucial neurovascular structures found in deeper planes.

- 1 Superficial medial cheek fat compartment (malar fat pad)
- 2 Superficial middle cheek fat compartment
- 3 Superficial lateral cheek fat compartment
- 4 Jowls fat compartment
- 5 Perioral fibrofatty tissue layer





Directly below the mandible at the mandibular crossing of the facial artery and vein, the submandibular gland is located. Together with the parotid gland, these two glands are considered salivary organs, and it has been shown that both increase in volume during the process of facial aging. This increase in glandular volume can reduce the aesthetic appeal of the jawline and/or mandibular angle, which can be addressed either surgically or nonsurgically. The latter relies on the intraglandular injection of neuromodulator product, which reduces the size of the glands and restores the contour of the jawline and mandibular angle and ramus.

Fig. 13.7 Detailed dissection of the platysma muscle in view from anterior. The skin and the superficial fatty layer are reflected cranially, whereas the platysma muscle is elevated laterally by the surgical instruments. The submandibular gland and the most inferior aspect of the parotid gland are exposed.

- 1 Skin & superficial fatty layer
- 2 Platysma muscle
- 3 Submandibular gland
- 4 Facial artery
- 5 Facial vein
- 6 Parotid gland



